

Matrix miniplate versus locking miniplate in the management of displaced mandibular angle fractures

R. K. Singh, Sharad Chand¹, U. S. Pal, Sanjib K. Das, V. P. Sinha²

Departments of Oral and Maxillofacial Surgery, King George's Medical University, Lucknow, ²Professor Oral and Maxillofacial Surgery, UP Dental College, Lucknow, ³Department of Dentistry, Government Medical College, Kannauj, Uttar Pradesh, India

ABSTRACT

Aim: The purpose of this study was to determine and compare various postoperative parameters like ease of operability, plate adaptability, stability etc., associated with use of matrix miniplate versus locking miniplate in the treatment of displaced mandibular angle fractures. **Materials and Methods:** The study was carried out in the Department of Oral and Maxillofacial surgery, King George's Medical College, GM and Associated Hospital, Lucknow. Total 50 patients were treated and included in the study. These were divided into two groups of 25 each and were treated with two of the standard techniques, i.e., one is matrix miniplate osteosynthesis and other is locking miniplate osteosynthesis. These patients were evaluated for postoperative complications and the differences between the two Groups were assessed. **Results:** Patients treated by matrix miniplate showed better recovery phase postoperatively as compared to locking miniplate group. **Conclusion:** Based on this study matrix mini plate osteosynthesis may be considered as the better alternative method available for the treatment of displaced mandibular angle fractures.

Key words: Locking miniplate, mandibular fracture, matrix miniplate, post-operative complications

Address for correspondence:
Dr. R. K. Singh,
Professor Oral and Maxillofacial
Surgery, KG Medical
University, Lucknow - 226003
E-mail: rksingh@kgmcindia.edu

INTRODUCTION

Mandible is a very prominent and vulnerable bone on the face^[1] since the projected chin is a favored target of adversaries. Lower jaw plays a major role in the mastication, speech and deglutition. Its fracture result in severe loss of function and disfigurement.^[2]

The management of mandibular fractures varies in various maxillofacial units depending on the presentation, surgical expertise and the facilities available.

The general principles of treatment for mandibular fractures do not differ from the treatment of fractures

elsewhere in the body. The fragments are reduced into a proper position and then immobilized until such time as bony union occurs^[3] i.e., reduction and fixation. Monocortical miniplates at superior border osteosynthesis of mandibular angle fracture is a world-wide technique^[4] but lower border flaring and rotation of lower border of proximal fragment linguallly due to pterygomasseteric sling results into loss of stability of fixation in three dimensional (3D) plane and to overcome this some sort of stabilization either a second miniplate^[5] or a 3D plate (matrix miniplate) is required to control this rotation in the coronal plane in displaced angle fracture.

MATERIALS AND METHODS

This study included 50 patients of mandibular angle fractures, who were treated at the Department of Oral and Maxillofacial Surgery, King George's Medical University, GM and Associated Hospital, Lucknow. Informed consent was obtained. A standard history and examination chart was completed for each patient. Data concerning the patients' fracture etiology and pattern of fracture were

Access this article online	
Quick Response Code: 	Website: www.njms.in
	DOI: 10.4103/0975-5950.127656

also obtained and analyzed Orthopantomogram (OPG) and posterior-anterior view of mandible were the standard radiographs. The radiological findings were recorded as fracture site, presence of additional mandibular fracture and degree of fracture dislocation.

Patients were distributed into two groups and were treated with two of the standard techniques i.e., one is matrix miniplate osteosynthesis and other is locking miniplate osteosynthesis. 25 patients were included in each group.

Group A: Matrix miniplate osteosynthesis.
Group B: Locking miniplate osteosynthesis.

The operation was performed under general anesthesia with nasotracheal intubation. Pre-operatively arch bar were placed for intra-operative Maxillomandibular fixation. All the plates were placed near tension trajectories using an intra-oral approach. Concomitant fractures were treated with miniplate fixation. Concurrent condylar fractures were treated by intermaxillary fixation for 21 days.

Amoxicillin plus clavulanic acid 1.2 g was administered 3 times a day for 5 days. 0.1% chlorhexidine mouthwash was advised to maintain oral hygiene. Non-chewing liquid diet was advised for 6 weeks. Each patient was followed-up for 3-months' time. Post-operative OPG and posterior-anterior view was taken in follow-up for each patient, whenever required. During the follow-up period any complication found was recorded on the proforma.

RESULTS

In our study, the mandibular fractures were most commonly seen in body/parasymphysis region (64%) followed by their association with contralateral condylar fractures 24% and isolated angle fractures 12% of the total. The details are given in Table 1 and Figure 1.

Both Groups A and B have 80-84% cases associated with high mobility of fracture fragments, and impairment in mouth opening was also predominantly high and equals 80% in both groups [Table 2].

25 patients were treated with matrix miniplate [Figure 2] and 25 were treated with straight locking miniplate [Figure 3]. Details about post-operative complications related to the above two treatment modalities are given in Table 3.

DISCUSSION

In this study, we have observed the fracture stability achieved by two different plates i.e., matrix miniplate and locking miniplate. We have found that matrix miniplate

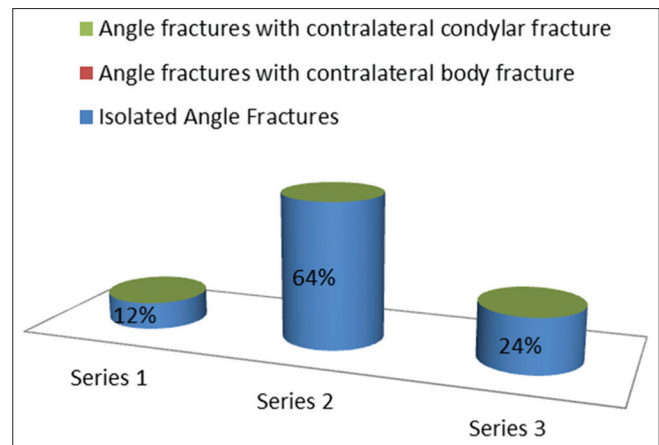


Figure 1: Anatomical location of fractures

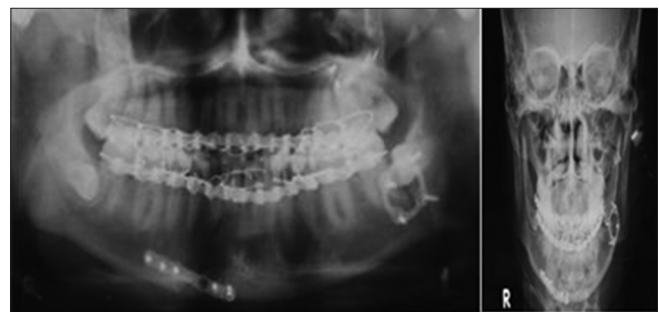

Figure 2: Post operative check X-rays

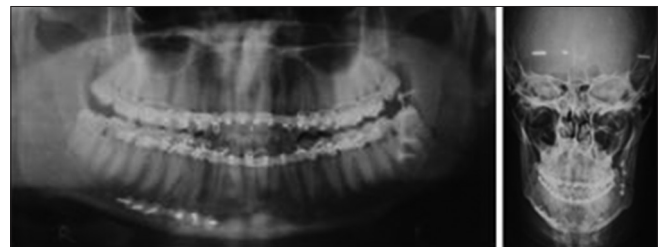


Figure 3: Postoperative OPG X-ray

Table 1: Location of fracture

Anatomical location of fracture	Number	Percentage
Isolated angle fractures	6	12
Angle fractures with contralateral body fracture	32	64
Angle fractures with contralateral condylar fracture	12	24

Table 2: Displacement and mouth opening in different groups patients

Parameter	No. (%) (N= 25)	
	Group A	Group B
Dislocation of fragments		
Yes	25 (100)	25 (100)
No	0	0
Mobility of fragments		
High	20 (80)	21 (84)
Slight	5 (20)	4 (16)
None	0	0
Pre-operative mouth opening		
Impaired	20 (80)	20 (80)
Non-impaired	5 (20)	5 (20)

Table 3: Post-operative complications

Complications	1 st week		2 nd week		4 th week		12 th week	
	Group A	Group B	Group A	Group B	Group A	Group B	Group A	Group B
	No. (%)	No. (%)	No. (%)	No. (%)	No. (%)	No. (%)	No. (%)	No. (%)
Infection	2 (8)	3 (12)	0	1 (4)	0	0	0	0
Wound dehiscence	3 (12)	2 (8)	0	0	0	0	0	0
Paresthesia	3 (12)	3 (12)	2 (8)	3 (12)	0	1 (4)	0	0
Malocclusion	2 (8)	1 (4)	0	0	0	0	0	0

provided better stability in fixation over locking plate 3D in displaced angle fracture.

About 80-84% patients of both Groups A and B reported with high mobility of fracture fragments attributable to the anatomy of the region involved i.e. opposing action of the pterygomasseteric sling and supra-hyoid muscles and delay in reporting of the cases.

80% of cases of each Groups A and B had impaired mouth opening and this is again attributable to regional anatomy, unstable nature of fracture and muscle guarding due to pain and swelling.

Nearly 12% (3) patients of Group B reported infection when compared with 8% (2) patients of Group A during first follow-up depicted by persistent swelling and pain. Patients having infection were treated with antibiotics for 7 days and no surgical intervention or plate removal was required, probable reason for this may be improper oral hygiene measures adopted by the patients. Similar results were obtained by Ellis and Graham (2002)^[7] who treated 28 patients out of 58 having mandibular angle fractures using locking miniplate and only 2 cases reported infection and no re-osteosynthesis was required Guimond *et al.*^[8] in his retrospective evaluation of 37 patients having mandibular angle fractures fixed with curved angle strut plate reported an infection rate of 5.4% which compares favorably with reconstruction plate fixation.

12% cases of Group A when compared with 8% of Group B, reported wound dehiscence after a weeks' time which may be due to wide exposure of surgical site to accommodate large size plate and excessive retraction during screw placement. Jain *et al.*^[9] in their study on 20 patients reported Champy's miniplate system as better and easier method than 3D miniplate system however he asserted that vertical bars incorporated in 3D plates provide good stability by countering the torque forces and due to simultaneous stabilization of both superior and inferior border operating time was less.^[10,13]

12% patients (3) of both groups reported paresthesia in first follow-up probably due to manipulation of fracture fragments for obtaining reduction., During second follow-up, 1 (4%) patient of Group A recovered from paresthesia while no improvement in paresthesia was found in patients of Group B. In third follow-up no patient

of Group A reported paresthesia while 1 (4%) of Group B reported paresthesia. In final follow-up none of the patients of either groups reported paresthesia, above findings can be explained on the basis of stability of fixation" of the system utilized. Early resolution of paresthesia was found in patients of Group A as compared to Group B, this may be attributable to better stability of fixation with matrix miniplate. Guimond *et al.*^[8] in their retrospective evaluation of 37 patients having mandibular angle fractures fixed with curved angle strut plate reported similar observation

Post-operative malocclusion was noted in 02 (8%) cases of Group A as compared to 01 (4%) case Group B, this finding though adverse was probably due to improved stability of fixation in case of matrix miniplate than locking miniplate.^[11,12] Patients of both the groups which reported post-operative malocclusion were relieved by selective grinding and enameloplasty of the dentition. Jules *et al.*^[13] also reported similar findings of better intrinsic stability, more resistance to fracture fragment mobility in a series of 22 patients of mandibular angle fracture treated with 2.0 mm matrix miniplate. Similar results were reported by Ellis and Graham^[7] and Gutwald *et al.*^[14] using mini-locking plate. The former reported no impairment in occlusion in treating 58 patients with mandibular fractures and later asserted that a rigid frame was constructed in all three planes with the use of locking miniplate and the bone was loaded more evenly in contrast to conventional fixation techniques.

CONCLUSION

Our study indicates that matrix miniplate increases stability in fixation in displaced angle fractures than locking miniplate. There must be at least two mechanisms that must be considered when developing new strategies to reduce the incidence of complications and increase the 3D stability of fixation in displaced angle fracture. Matrix miniplate offers better alternative in managing displaced mandibular angle fractures.

REFERENCES

1. Stanley RB. Pathogenesis and evaluation of mandibular fracture. In: Methog RH, editor. Maxillofacial Trauma. Baltimore: William and Wilkins; 1985. p. 136-47.

2. Tanaka N, Tomitsuka K, Shionoya K, Andou H, Kimijima Y, Tashiro T, *et al.* Aetiology of maxillofacial fracture. *Br J Oral Maxillofac Surg* 1994;32:19-23.
3. Banks P. Killeys' Fracture of the Mandible. 4th ed. London: Wright; 1991. p. 1-133.
4. Gear AJ, Apasova E, Schmitz JP, Schubert W. Treatment modalities for mandibular angle fractures. *J Oral Maxillofac Surg* 2005;63:655-63.
5. Ellis E 3rd. Treatment methods for fractures of the mandibular angle. *Int J Oral Maxillofac Surg* 1999;28:243-52.
6. Hochuli-Vieira E, Ha TK, Pereira-Filho VA, Landes CA. Use of rectangular grid miniplate for fracture fixation at the mandibular angle. *J Oral Maxillofac Surg* 2011;69:1436-41.
7. Ellis E 3rd, Graham J. Use of a 2.0-mm locking plate/screw system for mandibular fracture surgery. *J Oral Maxillofac Surg* 2002;60:642-5.
8. Guimond C, Johnson JV, Marchena JM. Fixation of mandibular angle fractures with a 2.0-mm 3-dimensional curved angle strut plate. *J Oral Maxillofac Surg* 2005; 63:209-14.
9. Jain MK, Manjunath KS, Bhagwan BK, Shah DK. Comparison of 3-dimensional and standard miniplate fixation in the management of mandibular fractures. *J Oral Maxillofac Surg* 2010;68:1568-72.
10. Zix J, Lieger O, Iizuka T. Use of straight and curved 3-dimensional titanium miniplate for fracture fixation at the mandibular angle. *J Oral Maxillofac Surg* 2007;65:1758-63.
11. Höfer SH, Ha L, Ballon A, Sader R, Landes C. Treatment of mandibular angle fractures-linea obliqua plate versus grid plate. *J Craniomaxillofac Surg* 2012;40:807-11.
12. Vineeth K, Lalitha RM, Prasad K, Ranganath K, Shwetha V, Singh J. A comparative evaluation between single non compression titanium miniplate and three dimensional titanium miniplate in treatment of mandibular angle fracture: A randomized prospective study. *J Craniomaxillofac Surg* 2013;41:103-9.
13. Feledy J, Caterson EJ, Steger S, Stal S, Hollier L. Treatment of mandibular angle fractures with a matrix miniplate: A preliminary report. *Plast Reconstr Surg* 2004;114:1711-6.
14. Gutwald R, Alpert B, Schmelzeisen R. Principle and stability of locking plates. *Keio J Med* 2003;52:21-4.

How to cite this article: Singh RK, Chand S, Pal US, Das SK, Sinha VP. Matrix miniplate versus locking miniplate in the management of displaced mandibular angle fractures. *Natl J Maxillofac Surg* 2013;4:225-8.

Source of Support: Nil. **Conflict of Interest:** None declared.