

## Full recovery of a stage IV cancer patient facing COVID-19 pandemic

Anuraj Parmanande<sup>a#</sup> , Diana Simão<sup>a#</sup> , Mariana Sardinha<sup>a#</sup> ,  
Ana Filipa Palma dos Reis<sup>a</sup> , Ana Sofia Spencer<sup>a</sup> , João Vasco Barreira<sup>a</sup> ,  
Ricardo da Luz<sup>a</sup> 

**How to cite:** Parmanande A, Simão D, Sardinha M, et al. Full recovery of a stage IV cancer patient facing covid-19 pandemic. *Autops Case Rep* [Internet].2020;10(3):e2020179. <https://doi.org/10.4322/acr.2020.179>

### ABSTRACT

Coronavirus disease 2019 (COVID-19), first recognized in Wuhan, China, was recently declared a global pandemic by the World Health Organization (WHO). Advanced age and comorbid disease, well-known characteristics in the solid tumor population, have been reported as risk factors for severe disease and death. Cancer-related immunosuppression and its treatments also seem to play an active role in the prognosis, response, and clinical outcomes of these patients. The most effective combination therapy for COVID-19 is still under investigation, and the use of corticosteroids is controversial. Although, as a group, metastatic cancer patients are often considered not to be good candidates for ICU treatment, the individual prognosis should always come into consideration, even in a context of high pressure on medical facilities. We report the case of a stage IV prostate cancer patient infected with SARS-CoV-2 who required ICU admission and recovered from COVID-19 infection. Further studies are needed in order to identify accurate clinical prognostic criteria and provide the best treatment for these challenging patients.

### Keywords

COVID-19; SARS-CoV-2; Cancer; Critical care; Treatment Outcome.

### INTRODUCTION

Coronavirus disease 2019 (COVID-19), first recognized in Wuhan, China, in December 2019, was recently determined by the World Health Organization (WHO)<sup>1</sup> as a global pandemic. The rapid spread throughout Western Nations has been creating great instability among patients with chronic medical conditions, particularly those with cancer.

Advanced age and comorbid disease, well-known characteristics in the solid tumor population, have been reported as risk factors for severe disease and death.<sup>1,2</sup>

Data suggest that cancer or treatment-related immunosuppression seem to increase the risk of

COVID-19 infection and is also associated with poor prognosis and negative clinical outcome.<sup>2-4</sup>

Severe acute respiratory syndrome Coronavirus 2 (SARS-CoV-2) infection presents with a rapidly progressive course of fever, cough, and dyspnea in the majority of cases. Important distinguishing factors are lymphopenia and the rapid progression to *acute respiratory distress syndrome* (ARDS), therefore leading to the need for intensive care.<sup>5</sup> In these patients, a high index of suspicion is mandatory in order to ensure adequate clinical monitorization and institution of supportive and contention measures.

<sup>a</sup> Centro Hospitalar Universitário Lisboa Central, Medical Oncology Department. Lisboa, Portugal.

# joint first authors



We report a successful case of a 77-year-old man with stage IV active metastatic prostate cancer and bone metastasis, admitted to an intensive care unit for COVID-19 infection, complicated with moderate ARDS.

## CASE REPORT

A 77-year-old male patient from Lisbon, with no epidemiologic contacts or recent travels, developed new-onset fever 38.9°C, asthenia, odynophagia, and dry cough over the last 5 days. After 3 days of persistent symptoms, he scheduled an urgent medical appointment. Chest radiography (Figure 1A) showed bilateral nonspecific poorly defined opacities, and blood tests revealed mild lymphopenia ( $0.89 \times 10^9 /L$ ) and an C-reactive protein (CRP) of 97.9 mg/L (reference range, [ $<0.5$  mg/L]). An upper respiratory tract infection was assumed, and since the patient was hemodynamically stable, the housing conditions were very good and there was no epidemiological data of suspicion for the newly presented COVID-19 disease, he was discharged home with azithromycin for three days and paracetamol.

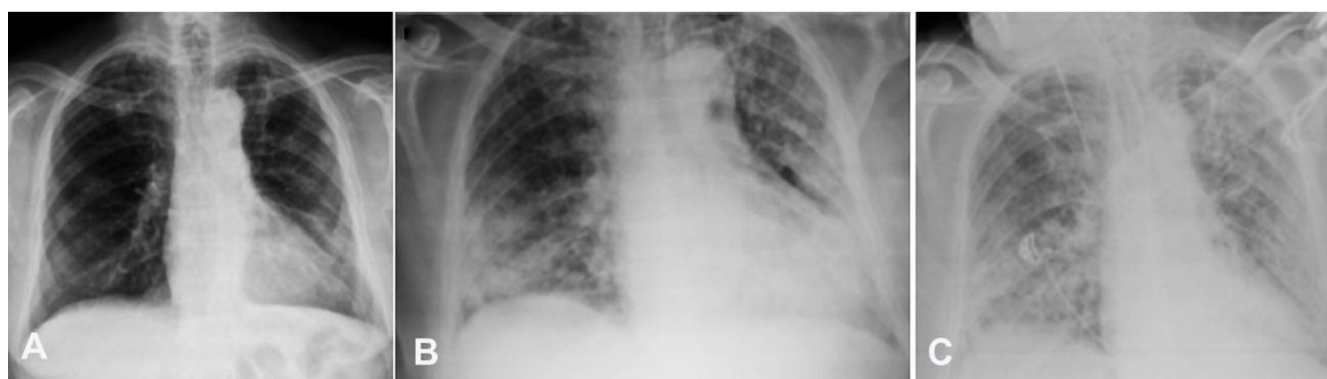Concerning this patient's medical background, he had Gleason 8 prostate cancer diagnosed in 2001 and initially treated with androgen blockade. In 2012, he developed castration resistance with bone metastasis being started on abiraterone plus 10mg prednisolone in February 2015, after progressing on docetaxel. PSA levels remained undetectable since then. He additionally had a history of stage I large cell

neuroendocrine lung carcinoma submitted to inferior left lobe segmentectomy in March 2014, on follow-up; Chronic obstructive pulmonary disease (COPD), GOLD A, with no recent exacerbations; former smoker (60 pack-years) and a history of pulmonary tuberculosis during childhood.

On the 14<sup>th</sup> of March, the patient returned to the hospital with worsening symptoms, having developed dyspnea (23 cycles per minute) and hypoxemia, with a partial pressure of oxygen of 56 mmHg on a 15 liter per minute oxygen mask, yet being hemodynamically stable and afebrile. Chest radiography showed multiple peripheral nodular infiltrate and lower right condensation (Figure 1B). Blood tests detected leukocytosis, neutrophilia, and CRP levels with rising kinetics (Figure 2). A nasopharyngeal swab was collected, which was positive for SARS-CoV-2.

COVID-19 associated acute respiratory distress syndrome (PaO<sub>2</sub>/FiO<sub>2</sub> of 160 mmHg), with probable bacterial superinfection, was assumed. The patient was, therefore, intubated and transferred to the Intensive care unit (ICU) (Figure 1C), being started on empirical piperacillin/tazobactam, hydroxychloroquine, and lopinavir/ritonavir (Figure 2).

Aminergic support was required for the first 4 days, during which he kept fever, sustained elevation of leukocytes count, CRP, and procalcitonin levels. Azithromycin was then administered along with the supra cited therapy. Blood cultures and secretions were sterile since admission. Due to the maintenance of low PaO<sub>2</sub>/FiO<sub>2</sub>, 40mg of IV methylprednisolone were



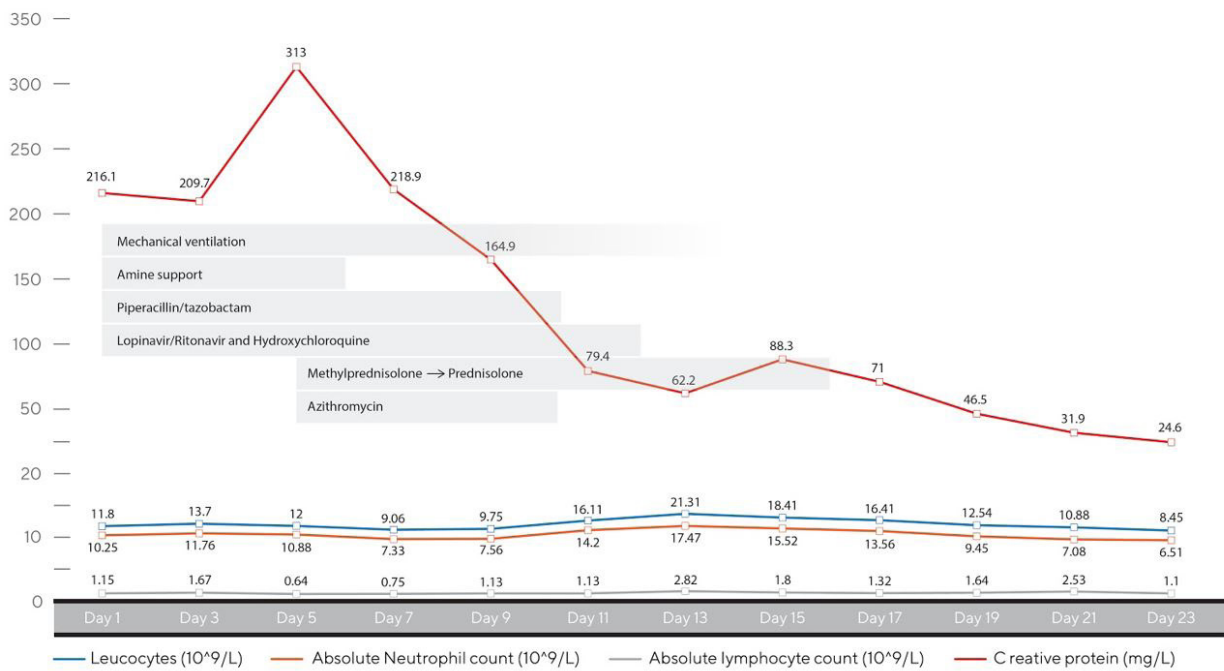
**Figure 1.** Postero-Anterior Chest X-ray depicting – **A** – bilateral poorly defined airspace opacities, with peripheral and lower zone predominance. Additional findings: Scarring at the lung apices, with volume loss and fibrosis due to previous tuberculosis; **B** – 4 days later. Radiological worsening, with a greater extension of the ground glass opacities and presence of peripheral consolidations, commonly reported imaging features of COVID-19 pneumonia; **C** – 6 days later, extensive coalescent opacities, with bilateral consolidation and panlobar involvement, typical radiological findings of ARDS.

administered daily from days 7 to 12 and then tapered to 10mg prednisolone from day 17. Prone positioning periods were adopted for a total of two days.

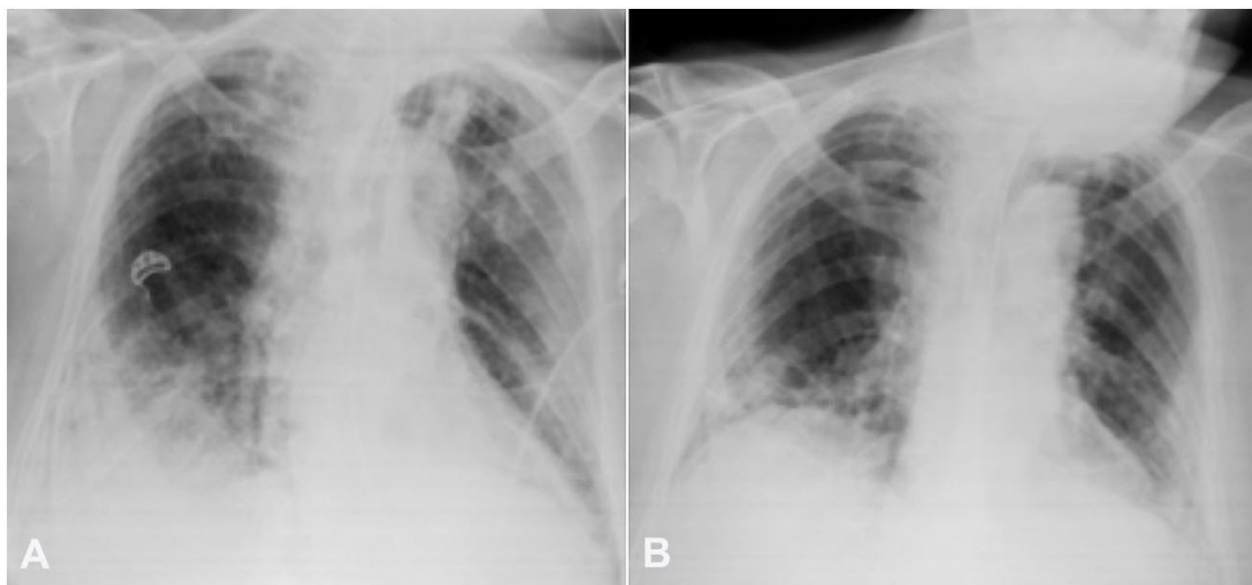
Hereafter, from the 10<sup>th</sup> day, there was a progressive improvement of the respiratory and hemodynamic function, which permitted patient extubation, with a PaO<sub>2</sub> of 80 mmHg with 4L/min supplemental oxygen administered by nasal cannula (Figures 2, 3A).

The patient was discharged from the ICU 14 days after admission to the infectious diseases ward. Chest radiography evolution showed a reduction in lung infiltrates (Figure 3B). The SARS-CoV-2 nasopharyngeal swab was the first negative on the 19th day of admission.

The patient was considered to be cured on the 24th day after admission, being able to resume his previous oncological treatment with abiraterone and



**Figure 2.** Clinical and laboratory evolution during hospitalization.



**Figure 3.** Postero-Anterior Chest X-ray depicting: **A** – (2 days after figure 1C) Bilateral peripheral airspace opacities and consolidations, less extensive than the previous x-rays; **B** – (12 days after figure 3A) Peripheral lower lobe predominant ill space opacities after clinical ARDS recovery due to COVID-19 infection.

prednisolone. He was discharged to a rehabilitation unit to recover from intensive care related myopathy, and his respiratory condition is improving since then, with no further need for supplementary oxygen therapy.

## DISCUSSION

To our knowledge, this is the first case report in Europe of a COVID-19 infected cancer patient who was admitted to the ICU and had a successful recovery.

At that time, according to Portuguese health authorities orientations and COVID-19 case definition, a case would be considered suspicious whenever one of the following conditions were met: respiratory tract infection symptoms (onset of fever with cough) and travel history to areas with active community transmission; respiratory tract infection symptoms and contact with a confirmed case in the previous 14 days before the beginning of symptoms; or severe respiratory tract infection requiring immediate hospitalization.<sup>6</sup> None of these conditions applied to this case, which explains why a SARS-CoV-2 swab was not performed, in the first place.

Active cancer has been reported to be a risk factor for complications related to COVID-19 infection.<sup>2</sup> In this context, understanding the factors that influence oncological patients' outcomes is relevant.

Concerning clinical presentation of COVID-19 infected patients, a recent retrospective study of 28 cancer patients with COVID-19 from three hospitals in Wuhan, China, showed that clinical signs and symptoms in this subgroup are usually similar to those of the general population. Typical symptoms included fever, dry cough, and dyspnea.<sup>7</sup> The clinical presentation of COVID-19 infection in our case report is, therefore, consistent with previous literature.

There is insufficient data regarding the clinical course of COVID-19 in cancer patients. Although in Europe, data are minimal, in a report from Italy, 20 percent of deaths from COVID-19 in the entire country occurred in patients with active cancer. However, in this report, patient demographics and clinical characteristics concerning the type of cancer and treatment background were not revealed. Also, severe complications and mortality from COVID-19 infection may be higher in some European countries compared

to China, for reasons that remain unclear. It is discussed if an older population in Italy might partly explain the differences in cases and case-fatality rates among countries.<sup>8</sup>

Despite the small sample size, retrospective, nonrandomized, and heterogeneous nature of the previously mentioned series from Wuhan, China, this is currently the most robust evidence of the COVID-19 infection course in cancer patients. In this series, more than 50% of cancer patients had severe disease, and 21% required admission to the ICU. Although the univariable analyses showed no statistically significant association, 70% of stage IV patients developed severe events. The finding of patchy consolidation on admission computed tomography was associated with a greater risk of severe disease.<sup>7</sup>

Although this case report refers to a stage IV cancer patient, ICU admission for mechanical ventilation due to hypoxemic respiratory failure occurred. This decision required a multidisciplinary discussion that took into account the fact that this was a potentially reversible complication, in a patient with previously good performance status and a predicted lifespan of more than a year. According to both the European Society of Medical Oncology (ESMO) and the Portuguese Society of Medical Oncology (SPO) guidelines, this situation would be suitable for an ICU full code management.<sup>9,10</sup>

Taking into account the higher rate of severe events reported in COVID-19 stage IV cancer patients and the presence of potential predictors for clinical deterioration such as lymphopenia, elevated CRP, and multiple nodular infiltrates, this would be a probable clinical course.

Immunosuppression in cancer seems to play an active role in the response and clinical outcomes of COVID-19 infection, although its prognostic value is still unclear. In this case report, there was a state of prolonged immunosuppression, both cancer-related and treatment-induced. Immunosuppression could be a risk factor for a poor prognosis allowing higher viral loads and an increased risk of secondary infection.<sup>11</sup> On the other hand, the rationale for corticosteroids use is to decrease the host inflammatory response in the lungs, which may lead to an acute lung injury and acute respiratory distress syndrome (ARDS). A recent observational retrospective study

of 201 patients with COVID-19 in China demonstrated that treatment with methylprednisolone was associated with a decreased risk of death for patients developing ARDS (23/50 [46%] with steroids vs 21/34 [62%] without; HR, 0.38 [95% CI, 0.20-0.72]), although inherent bias and residual confounding factors may have influenced these results.<sup>12</sup>

In this case report, systemic glucocorticoid therapy was administered during the ICU stay, being rapidly tapered to 10mg prednisolone. Despite the presence of multiple factors potentially contributing to a worse prognosis of COVID-19 infection, there was a full recovery after ICU admission in this case. The use of hydroxychloroquine, lopinavir/ritonavir, and azithromycin might have been effective, although there is no robust evidence supporting the use of this combination.

Chloroquine and hydroxychloroquine have first been reported to be efficient in Chinese patients with SARS-CoV-2, and hydroxychloroquine was found to have greater activity with a safer dose-dependent toxicity profile. A small French trial soon after confirmed the effectiveness of hydroxychloroquine use in COVID-19 patients by demonstrating a significant viral load reduction, with a synergistic effect led by the addition of azithromycin.<sup>13</sup>

The oral combination of Lopinavir/ritonavir, used in HIV treatment, has also demonstrated in vitro activity against other novel coronaviruses via inhibition of 3-chymotrypsin-like protease. The ideal timing of administration seems to be during the early peak viral replication phase (initial 7-10 days), since a delayed therapy initiation revealed no effect on clinical outcomes. Although additional randomized controlled trials (RCTs) of lopinavir/ritonavir are ongoing, we recognize that no published SARS-CoV-2 in vitro data exist on this combination, yet.<sup>12</sup> Other antivirals, such as Remdesivir, have recently revealed more promising efficacy results.<sup>12,14</sup>

Despite the uncertainties, the most recent recommendations of the Portuguese Society of Intensive Care for COVID-19 treatment are in line with this therapeutic choice.<sup>15</sup>

This case underlines the importance of case series and clinical trials to achieve a better understanding of SARS-CoV-2 infection in cancer patients.

## CONCLUSION

Despite limited data that suggest that COVID-19 is typically more severe and lethal among people with underlying medical conditions such as active cancer, the global risk may be influenced by the type of cancer, disease control, treatment background and time since the last treatment, patient's age and comorbid medical conditions. Treatment decisions among cancer patients can be challenging, and our case report highlights how ICU admission needs to be made on a case-to-case basis. Further studies are needed to identify accurate clinical prognostic criteria in order to provide the most effective treatment.

## REFERENCES

1. World Health Organization (WHO). Clinical management of severe acute respiratory infection (SARI) when COVID-19 disease is suspected: interim guidance. Vol.1-2. Geneva: WHO; 2020. p. 1-21.
2. Liang W, Guan W, Chen R, et al. Cancer patients in SARS-CoV-2 infection: a nationwide analysis in China. *Lancet Oncol.* 2020;21(3):335-7. [http://dx.doi.org/10.1016/S1470-2045\(20\)30096-6](http://dx.doi.org/10.1016/S1470-2045(20)30096-6). PMID:32066541.
3. Kamboj M, Sepkowitz KA. Nosocomial infections in patients with cancer. *Lancet Oncol.* 2009;10(6):589-97. [http://dx.doi.org/10.1016/S1470-2045\(09\)70069-5](http://dx.doi.org/10.1016/S1470-2045(09)70069-5). PMID:19482247.
4. Li JY, Duan XF, Wang LP, et al. Selective depletion of regulatory t cell subsets by docetaxel treatment in patients with nonsmall cell lung cancer. *J Immunol Res.* 2014;2014:286170. <http://dx.doi.org/10.1155/2014/286170>. PMID:24868562.
5. Rodriguez-Morales A, Cardona-Ospina J, Gutiérrez-Ocampo E, et al. Clinical, laboratory and imaging features of COVID-19: a systematic review and meta-analysis. *Travel Med Infect Dis.* 2020;34:101623. <http://dx.doi.org/10.1016/j.tmaid.2020.101623>. PMID:32179124.
6. Direção-Geral da Saúde (DGS). Doença pelo novo Coronavírus (COVID-19) – Nova definição de caso. Lisboa: DGS; 2020. Orientação 02/2020 atualizada em 09/03/2020.
7. Zhang L, Zhu F, Xie L, et al. Clinical characteristics of COVID-19-infected cancer patients: a retrospective case study in three hospitals within Wuhan, China. *Ann Oncol.* 2020; pii: S0923-7534(20):36383-3. [Epub ahead of print]. <http://dx.doi.org/10.1016/j.annonc.2020.03.296>.
8. Onder G, Rezza G, Brusaferro S. Case-fatality rate and characteristics of patients dying in relation to COVID-

- 19 in Italy. *JAMA*. 2020. <http://dx.doi.org/10.1001/jama.2020.4683>. PMID:32203977.
9. Schellongowski P, Sperr WR, Wohlfarth P, et al. Critically ill patients with cancer: chances and limitations of intensive care medicine — a narrative review. *ESMO Open*. 2016;1(1):1-6. <http://dx.doi.org/10.1136/esmoopen-2015-000018>. PMID:27843637.
10. Martins RM, Teixeira G, Cortesão E, et al. Recomendações para tratamento médico intensivo em doentes oncológicos. Lisboa: Sociedade Portuguesa de Oncologia; 2020.
11. Sanders JM, Monogue ML, Jodlowski TZ, Cutrell JB. Pharmacologic treatments for coronavirus disease 2019 (COVID-19): a review. *JAMA*. 2020. [Epub ahead of print]. <http://dx.doi.org/10.1001/jama.2020.6019>. PMID:32282022.
12. Wu C, Chen X, Cai Y, et al. Risk factors associated with acute respiratory distress syndrome and death in patients with coronavirus disease 2019 pneumonia in Wuhan, China. *JAMA Intern Med*. 2020. [Epub ahead of print]. <http://dx.doi.org/10.1001/jamainternmed.2020.0994>. PMID:32167524.
13. Gautret P, Lagier J-C, Parola P, et al. Hydroxychloroquine and azithromycin as a treatment of COVID-19: results of an open-label non-randomized clinical trial. *Inten J Antimicrob Agents*. 2020. [Epub ahead of print]. <https://doi.org/10.1016/j.ijantimicag.2020.105949>.
14. Sheahan TP, Sims AC, Leist SR, et al. Comparative therapeutic efficacy of remdesivir and combination lopinavir, ritonavir, and interferon beta against MERS-CoV. *Nat Commun*, 11:222. <https://doi.org/10.1038/s41467-019-13940-6>.
15. Mendes JJ, Mergulhão P, Froes F, Paiva JA, Gouveia J. Recommendations from the Sociedade Portuguesa de Cuidados Intensivos and Infection & Sepsis Group for intensive care approach to COVID-19. *Rev Bras Ter Intensiva*. 2020;32(1):2-10. PMID:32401989.

**Authors' contributions:** Parmanande A, Simão D and Sardinha M developed and took the lead in writing the manuscript. Palma dos Reis AF, Spencer AS and Barreira JV provided critical feedback and helped shape the manuscript. Barreira JV and Da Luz R. supervised the work. All the authors discussed the results and contributed to the final manuscript.

The authors retain informed consent and permission signed by the patient authorizing the data for publication.

**Conflict of interest:** None

**Financial support:** None

**Submission on:** April 12<sup>th</sup>, 2020

**Accepted on:** May 8<sup>th</sup>, 2020

### Correspondence

João Vasco Barreira

Medical Oncology Department - Centro Hospitalar Universitário Lisboa Central

Alameda Santo António dos Capuchos, – Lisboa – Portugal

1169-050

Phone: +351 213 136 300

joavascobarreira@gmail.com