

# General hyperpigmentation induced by Grave's disease

## A case report

Xiaoxiao Song, MD, PhD<sup>a</sup>, Yimin Shen, MBBS<sup>a,b</sup>, Ying Zhou, MS<sup>c</sup>, Qinhu Lou, MBBS<sup>b</sup>, Li Han, MBBS<sup>b</sup>, Jon Kee Ho, MS<sup>b</sup>, Yuezhong Ren, MD<sup>a,\*</sup>

### Abstract

**Rationale:** Hyperpigmentation is a common skin disease. However, there are few reported cases of Grave's disease with diffuse hyperpigmentation. We hereby described a rare case with diffuse hyperpigmentation induced by Grave's disease.

**Patient concerns:** A 42-year-old Chinese woman with accumulated general pigmentation of skin was admitted to our hospital in October 2017. On examination, hyperpigmentation was observed throughout the whole body, especially on the extremities and the face.

**Diagnoses:** The patient has elevated levels of serum free thyroxine (FT<sub>4</sub>), free triiodothyronine (FT<sub>3</sub>), reduced levels of thyroid-stimulating hormone (TSH) and positive anti-TSH receptor antibody (TRAb). She presented with grade I goiter and a diffusely increased thyroid uptake to 18.5% in thyroid scan. Histopathological examination demonstrated melanin pigmentation in the pigmented skin area. The patient was diagnosed with hyperpigmentation induced by Grave's disease.

**Interventions:** The patient was treated with oral methimazole (15 mg/day) for thyroid dysfunction and beta blocker for symptom control.

**Outcomes:** After a period of treatment with methimazole and beta blocker, symptoms of hyperthyroidism ameliorated and hyperpigmentation abated.

**Lessons:** Our studies proposed that in this case the diffuse hyperpigmentation in Grave's disease was caused by elevated adrenocorticotrophic hormone (ACTH) as well as anti-TSH receptor stimulating antibody instead of enhanced capillary fragility. Other potential mechanisms for skin pigmentation in hyperthyroidism still need further exploration.

**Abbreviations:** ACTH = adrenocorticotrophic hormone, FT<sub>3</sub> = free triiodothyronine, FT<sub>4</sub> = free thyroxine, HH = hereditary hemochromatosis, TRAb = anti-TSH receptor antibody.

**Keywords:** adrenocorticotrophic hormone, Grave's disease, hemosiderin deposition, hyperpigmentation, thyroid-stimulating hormone

## 1. Introduction

Hyperpigmentation is always accompanied by a number of endocrine diseases, such as Addison's disease and hemochromatosis.

Editor: N/A.

This work was supported by grant from Zhejiang Provincial Medical and Health Technology Project (project number 2013KYA089), and grant from National Natural Science Foundation of China for Young Scholars (grant number 81300083). The funders had no role in study design, data collection and analysis, decision to publish, or preparation of the manuscript.

The authors have no conflicts of interest to disclose.

<sup>a</sup> Department of Endocrinology, The Second Affiliated Hospital of Zhejiang University School of Medicine, <sup>b</sup> Zhejiang University School of Medicine,

<sup>c</sup> Department of Dermatology, The Second Affiliated Hospital of Zhejiang University School of Medicine, Hangzhou, Zhejiang, China.

\* Correspondence: Yuezhong Ren, Department of Endocrinology, The Second Affiliated Hospital of Zhejiang University School of Medicine, 88 Jiefang Road, Hangzhou, Zhejiang, 310009, China (e-mail: renyuezhong@zju.edu.cn).

Copyright © 2018 the Author(s). Published by Wolters Kluwer Health, Inc. This is an open access article distributed under the terms of the Creative Commons Attribution-Non Commercial-No Derivatives License 4.0 (CCBY-NC-ND), where it is permissible to download and share the work provided it is properly cited. The work cannot be changed in any way or used commercially without permission from the journal.

Medicine (2018) 97:49(e13279)

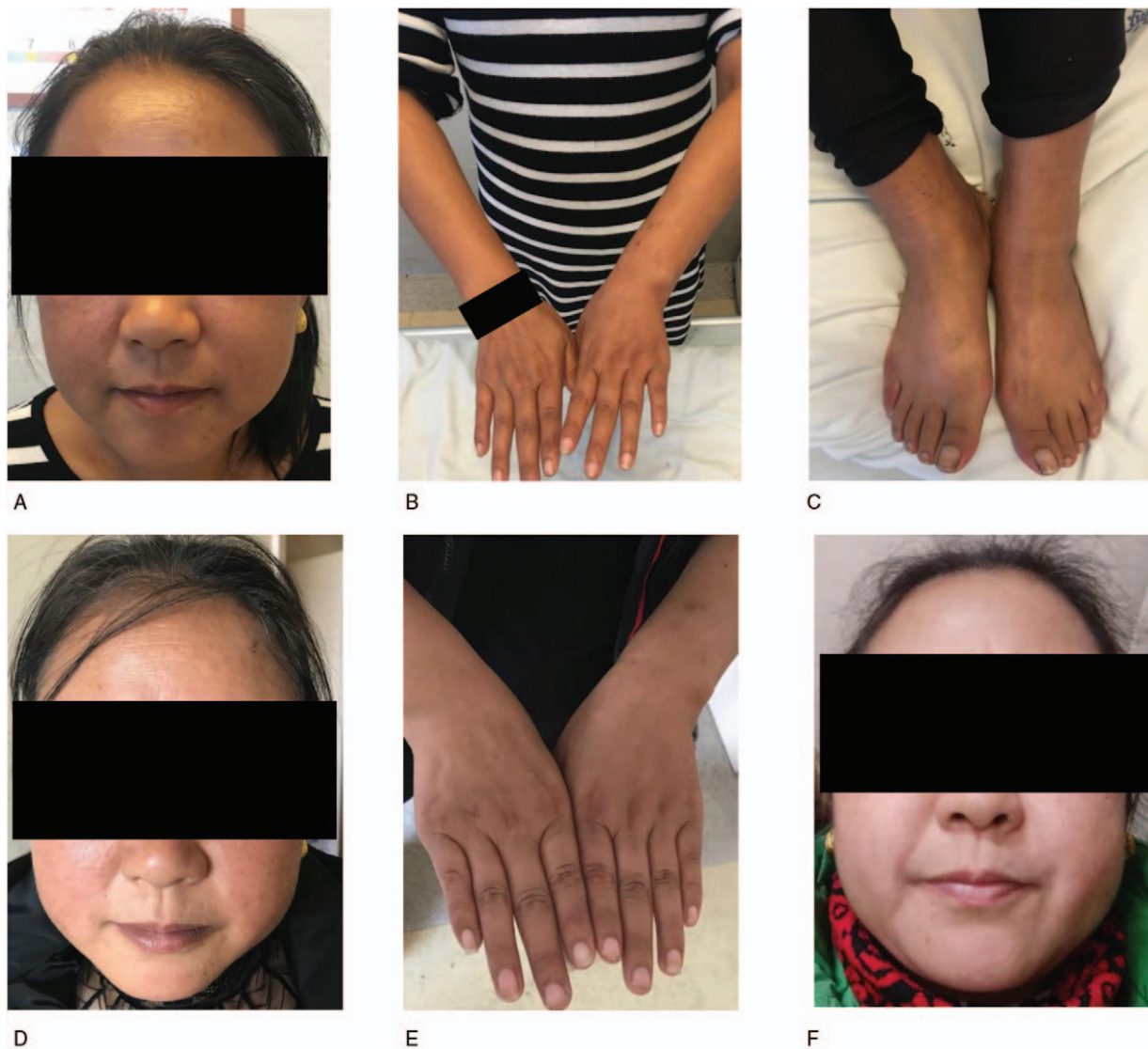Received: 2 July 2018 / Accepted: 23 October 2018

<http://dx.doi.org/10.1097/MD.00000000000013279>

However, the occurrence of hyperpigmentation in thyroid dysfunctions is rarely reported in the literature. Hyperthyroidism mainly leads to dermal symptoms like localized myxoedema, eczematous dermatitis, alopecia, and telangiectasis.<sup>[1–3]</sup> There had been a hypothesis that thyrotoxicosis could also lead to hyperpigmentation through an increased capillary fragility, contributing to hemosiderin deposition and basal melanosis.<sup>[4]</sup> In this case report, we attempt to elucidate the possible mechanism for hyperpigmentation in Grave's disease. Informed consent was obtained in writing from the patient with use of photographs and publication of this case.

## 2. Case report

In October 2017, a 42-year-old Chinese woman came with the complaint of pigmentation and weight loss for 3 months. She had diffused hyperpigmentation observed on the whole body including non-sun-exposed skin, especially on her lower and upper extremities, as well as her face (Fig. 1). There was no obvious hyperpigmentation in the oral cavity, nipples and genital. Over the past 3 months, despite an increase in appetite, she had weight loss for 15 kg. She gave a recent history of menstrual irregularities, heat intolerance, fine tremor, palpitations, and anhelation after regular exercise at times. She has no sign of exophthalmos, conjunctival edema, and myxoedema. Her thyroid gland was diffusely enlarged (WHO goiter grading I) with elastic hardness.

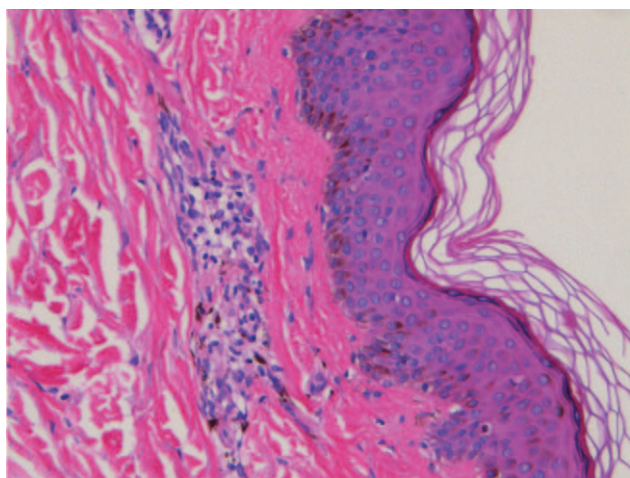


**Figure 1.** (A), (B), (C) Hyperpigmentation especially on the face, upper limbs as well as lower extremities; (D), (E) 1 month after the therapy; (F) 3 months after therapy.

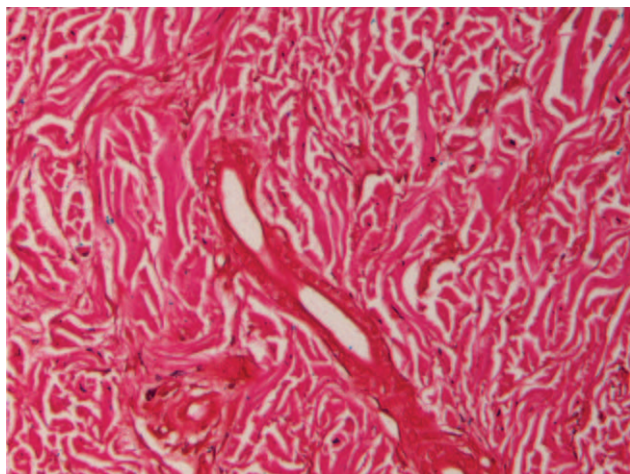
Her laboratory data revealed overt hyperthyroidism: total thyroxine ( $TT_4$ )=284.28nmol/L (reference range, 58.1–140.6nmol/L), total triiodothyronine ( $TT_3$ )=12.26nmol/L (reference range, 0.89–2.44nmol/L), free thyroxine ( $FT_4$ )=58.11pmol/L (reference range, 9.01–19.05pmol/L), free triiodothyronine ( $FT_3$ )>46.08pmol/L (reference range, 2.63–5.70pmol/L), TSH <0.01mIU/mL (reference range, 0.35–4.94mIU/mL), anti-thyroglobulin antibody (TGAb)=10.82IU/mL (reference range, <4.11IU/mL), anti-TSH receptor antibody (TRAb)>40IU/L (reference range, <1.75IU/L), and anti-thyroid peroxidase antibody (TPOAb)=10.54IU/mL (reference range, <5.61IU/mL). The levels of cortisol (8AM-4PM-0AM) were 325.98nmol/L-150.83nmol/L-20.47nmol/L (reference range for 8AM is 185–624nmol/L), while adrenocorticotrophic hormone (ACTH) (8AM-4PM-0AM) were 69pg/mL-43pg/mL-9.8pg/mL (reference range for 8AM is 7.2–63.3pg/mL) and serum ferritin was 45.10 $\mu$ g/L (reference range, 11.1 $\mu$ g/L–306.8 $\mu$ g/L). And the result of 1mg overnight dexamethasone screening test was negative (cortisol at 8AM the next morning was 11.71nmol/L).

On examination, the electrocardiogram revealed a heart rate with 95beats/min at rest. Technetium-99 m-methoxyisobutylisonitrile (MIBI) scintigraphy demonstrated a diffusely increased uptake rate to 18.5% (positive >2.5%) in the thyroid gland, a pattern consistent with Grave's disease. Thyroid ultrasonography scans showed mild goiter and Color flow Doppler imaging demonstrated high blood flow, while adrenal ultrasonography was normal. The histopathological examination from pigmented skin revealed hyperpigmented basal cells in the epidermis as well as lots of melanophages in the superficial dermis. Iron staining to identify the presence of hemosiderin deposition showed negative results (Figs. 2 and 3).

Taken together, the patient was diagnosed as thyrotoxicosis and hyperpigmentation induced by Grave's disease, thus was treated with oral methimazole (15mg/day) and beta blocker for thyroid dysfunction. A month later, the hyperpigmentation abated and the thyroid function improved ( $FT_4$ : 23.75pmol/L and  $FT_3$ : 11.10pmol/L). Moreover, the adrenocortical functions returned to normal levels (ACTH (8AM-4PM): 50.5pg/mL-25.4pg/mL, cortisol (8AM-4PM): 382.29nmol/L-169.22nmol/L). Three



**Figure 2.** Pigmented basal cells in the epidermis and melanophages in the superficial dermis (Hematoxylin-eosin stain; 200 $\times$ ).



**Figure 3.** Negative iron stain of pigmented areas (200 $\times$ ).

months later, the thyroid function came to normal and skin pigmentation further subsided (Fig. 1).

### 3. Discussion

The mentioned case presented with particularly unique extensive skin pigmentation which may be attributed to Grave's disease. Although a few cases of pigmentation with hyperthyroid have been reported, definite causal relationship remains incompletely understood. K. Banba et al hypothesized that evident pigmentation may be related to hemosiderin deposition caused by increased capillary fragility in hyperthyroid patients which could be verified by the iron staining in pigmented area.<sup>[4]</sup> On the other hand, some researchers proposed that increased release of pituitary ACTH compensating for accelerated cortisol degeneration was responsible for the hyperpigmentation through increasing melanotropic activity.<sup>[5-8]</sup> Moreover, other study speculated the expression of TSH-receptor on epidermal melanocytes may be related to the skin pigmentation in Graves' hyperthyroidism patients.<sup>[9]</sup> To further explore the mechanism

on this subject, we examined the histopathological staining which revealed melanosis in the epidermis and aggregation of brown-colored granules in macrophages located in the superficial dermis, nevertheless few hemosiderin depositions around capillaries. Meanwhile, the ACTH was slightly increased but the low-dose dexamethasone overnight suppression test showed negative result in this patient. Thus, we speculated that increased release of ACTH rather than enhanced capillary fragility contributed to hyperpigmentation in our case.

As we all know, many endocrine diseases, especially Addison's disease and hemochromatosis, are referring to induce skin pigmentation. Therefore, we reviewed the pigmentation-related disease and discussed their distinct features compared with our case to further dissect the possible mechanism for hyperpigmentation accompanied by hyperthyroidism. The distribution of the pigmentation in our case is a bit different from that in Addison's disease which presents a diffuse pigmentation with a preferential occurrence on the mucous membranes and over pressure points, such as oral cavity, conjunctiva, and genitalia. As for Addison's disease, it gets overt high secretion of ACTH due to the deficient of adrenal cortex hormones.<sup>[10,11]</sup> The histopathological examination of Addison's disease-related pigmentation always presents with heavy deposition of melanin in the basal as well as subepithelial layers.<sup>[12]</sup> And hereditary hemochromatosis (HH) is an autosomal recessive disorder characterized by enhanced intestinal absorption of dietary iron. The overloaded iron always leads to the skin pigmentation.<sup>[13,14]</sup> Hemochromatosis related pigmentation is more likely to happen in sun-exposed skin and scar areas. According to the laboratory examination, the diagnosis of HH can be made once the ferritin level is elevated. Furthermore, increased level of alanine aminotransferase (ALT) and aspartate aminotransferase (AST) will also be meaningful.<sup>[15]</sup> In the skin biopsy of HH, the deposits of hemosiderin granules and melanin could be observed to indicate the overloaded of iron. Moreover, there have been several cases regarding drug-induced diffuse hyperpigmentation. Amiodarone is often used to treat both ventricular and atrial arrhythmias. With the use of amiodarone, slate-grey pigmentation could be observed in the sun-exposed skin due to accumulation of drug and its metabolites in the skin.<sup>[16,17]</sup> Yellow-brown pigment granules located in macrophages and fibroblasts can be observed for its histopathology.<sup>[18]</sup> Patient using Amiodarone may suffer from potential adverse effects like alterations of thyroid physiology, resulting in hypothyroidism and thyrotoxicosis.<sup>[19,20]</sup> All in all, the distributions of skin pigmentation, histopathological results as well as the related mechanisms are varied among these different endocrine disorders induced skin-pigmentation.

In our case, we hypothesized that hyperpigmentation in skin may be correlated with the following explanations. First, increased release of pituitary ACTH in the thyrotoxicosis patients could compensate for accelerated cortisol degradation.<sup>[6]</sup> Pituitary ACTH, in common with some MSH peptides in the amino acid sequences, is critical agonist for melanotropic activity.<sup>[5]</sup> Elevated ACTH could interact with the type 1 melanocortin receptor (MC-1R) in melanocytes through the adenylyl cyclase/cAMP second messenger system, contributing to overproduction of melanin.<sup>[7,21-24]</sup> Second, it has been testified that the functional TSH receptor expressed in epidermal melanocytes and melanoma cells. Therefore, previous research speculated that in autoimmune conditions, stimulating antibodies such as TRAb interacting with TSH-R could stimulate cAMP production, which promotes melanocytes proliferation

and differentiation, resulting in the skin pigmentation of Graves' hyperthyroidism patients.<sup>[9]</sup>

In the case we present here, the pigmentation displayed good response to methimazole and beta blocker treatment. As the euthyroidism was arrived, and ACTH levels came to normal, the hyperpigmentation significantly diminished. This could be well explained by the mechanisms we mentioned above and is also consistent with Addisonian type pigmentation in which cortisone replacement therapy would decrease the ACTH level and significantly mitigate intensity of hyperpigmentation. On the other hand, we have already known that Addison's disease results in a significant higher level of ACTH compared with those of Grave's disease. Therefore, it is reasonable the occurrence of hyperpigmentation in Addison's disease is much higher than that in Grave's disease. The low morbidity of hyperpigmentation in hyperthyroidism may be due to multifactorial reasons and involves a complex genetic background. Different phenotypes of ACTH or their different affinity with MC-1R among individuals ultimately contribute to a variable sensibility to the effect of elevated ACTH in thyrotoxicosis condition. Although the increased ACTH can well explain the hyperthyroidism induced skin pigmentation, the differences of pigmentation distributions between hyperthyroidism and Addison's disease still needs further exploration. The simulating effect of anti-TSH receptor antibodies on epidermal melanocytes may partly take responsible for this difference, but we still cannot rule out other potential mechanisms for skin pigmentation in hyperthyroidism.

### Author contributions

**Conceptualization:** Xiaoxiao Song, Yuezhong Ren.

**Funding acquisition:** Xiaoxiao Song.

**Resources:** Ying Zhou, Qinhua Lou.

**Supervision:** Yuezhong Ren.

**Writing - original draft:** Xiaoxiao Song, Yimin Shen.

**Writing - review & editing:** Xiaoxiao Song, Ying Zhou, Qinhua Lou, Li Han, Jon Kee Ho, Yuezhong Ren.

### References

- [1] Taketomo Y, Noso S, Babaya N, et al. Common phenotype and different non-HLA genes in Graves' disease and alopecia areata. *Hum Immunol* 2017;78:185–9.
- [2] Shih SR, Lin MS, Li HY, et al. Observing pretibial myxedema in patients with Graves' disease using digital infrared thermal imaging and high-resolution ultrasonography: for better records, early detection, and further investigation. *Eur J Endocrinol* 2011;164:605–11.
- [3] Lause M, Kamboj A, Fernandez Faith E. Dermatologic manifestations of endocrine disorders. *Transl Pediatr* 2017;6:300–12.
- [4] Banba K, Tanaka N, Fujioka A, et al. Hyperpigmentation caused by hyperthyroidism: differences from the pigmentation of Addison's disease. *Clin Exp Dermatol* 1999;24:196–8.
- [5] Slominski A, Tobin DJ, Shibahara S, et al. Melanin pigmentation in mammalian skin and its hormonal regulation. *Physiol Rev* 2004;84:1155–228.
- [6] Leonhardt JM, Heymann WR. Thyroid disease and the skin. *Dermatol Clin* 2002;20:473–81.
- [7] Yamamoto H, Yamane T, Iguchi K, et al. Melanin production through novel processing of proopiomelanocortin in the extracellular compartment of the auricular skin of C57BL/6 mice after UV-irradiation. *Sci Rep* 2015;5:14579.
- [8] Diven DG, Gwinup G, Newton RC. The thyroid. *Dermatol Clin* 1989;7:547–58.
- [9] Slominski A, Wortsman J, Kohn L, et al. Expression of hypothalamic-pituitary-thyroid axis related genes in the human skin. *J Invest Dermatol* 2002;119:1449–55.
- [10] Meleti M, Vescovi P, Mooi WJ, et al. Pigmented lesions of the oral mucosa and perioral tissues: a flow-chart for the diagnosis and some recommendations for the management. *Oral Surg Oral Med Oral Pathol Oral Radiol Endod* 2008;105:606–16.
- [11] Sarkar SB, Sarkar S, Ghosh S, et al. Addison's disease. *Contemp Clin Dent* 2012;3:484–6.
- [12] Fernandez-Flores A, Cassarino DS. Histopathologic findings of cutaneous hyperpigmentation in addison disease and immunostain of the melanocytic population. *Am J Dermatopathol* 2017;39:924–7.
- [13] Santos PC, Krieger JE, Pereira AC. Molecular diagnostic and pathogenesis of hereditary hemochromatosis. *Int J Mol Sci* 2012;13:1497–511.
- [14] Sanchez-Pablo MA, Gonzalez-Garcia V, del Castillo-Rueda A. Study of total stimulated saliva flow and hyperpigmentation in the oral mucosa of patients diagnosed with hereditary hemochromatosis. Series of 25 cases. *Med Oral Patol Oral Cir Bucal* 2012;17:e45–9.
- [15] Borgaonkar MR. Hemochromatosis. More common than you think. *Can Fam Physician* 2003;36–43.
- [16] Bernstein EF. Q-switched laser treatment of amiodarone pigmentation. *J Drugs Dermatol* 2011;10:1316–9.
- [17] Wiper A, Roberts DH, Schmitt M. Amiodarone-induced skin pigmentation: Q-switched laser therapy, an effective treatment option. *Heart* 2007;93:15.
- [18] Jaworski K, Walecka I, Rudnicka L, et al. Cutaneous adverse reactions of amiodarone. *Med Sci Monit Int Med J Experiment Clin Res* 2014;20:2369–72.
- [19] Cohen-Lehman J, Dahl P, Danzi S, et al. Effects of amiodarone therapy on thyroid function. *Nat Rev Endocrinol* 2010;6:34–41.
- [20] Jabrocka-Hybel A, Bednarczuk T, Bartalena L, et al. Amiodarone and the thyroid. *Endokrynol Polska* 2015;66:176–86.
- [21] Rousseau K, Kauser S, Pritchard LE, et al. Proopiomelanocortin (POMC), the ACTH/melanocortin precursor, is secreted by human epidermal keratinocytes and melanocytes and stimulates melanogenesis. *FASEB J Off Publ Federation Am Soc Exp Biol* 2007;21:1844–56.
- [22] Zmijewski MA, Slominski AT. Neuroendocrinology of the skin: an overview and selective analysis. *Dermatoendocrinology* 2011;3:3–10.
- [23] Busca R, Ballotti R. Cyclic AMP a key messenger in the regulation of skin pigmentation. *Pigment Cell Res* 2000;13:60–9.
- [24] Robbins LS, Nadeau JH, Johnson KR, et al. Pigmentation phenotypes of variant extension locus alleles result from point mutations that alter MSH receptor function. *Cell* 1993;72:827–34.