

Case Report

The rendezvous technique for the treatment of ipsilateral femoral neck and shaft fractures: A case series

Seun Harewood^a, Marlon M. Mencia^{b,*}, Patrick Harnarayan^b

^a Department of Surgery, Scarborough General Hospital, Tobago, Trinidad and Tobago

^b Department of Clinical Surgical Sciences, University of the West Indies, Trinidad and Tobago

ARTICLE INFO

Keywords:
Rendezvous
Ipsilateral
Hip
Femoral
Fracture

ABSTRACT

Concomitant ipsilateral femoral neck and shaft fractures are uncommon high-energy injuries characteristically occurring in young adults. Between 75 and 100% of these injuries occur in association with polytrauma to other organ systems. Associated femoral neck fractures are typically undisplaced, occurring in 2–9% of all femoral shaft fractures. These injuries present both technical and infrastructural challenges particularly in a low resource environment. Several methods of treatment have been used to successfully treat these fractures but there exists no consensus about the optimal management strategy. The “rendezvous” technique using dual implants in an overlapping fashion has been proposed as one method to treat these fractures. We present three cases of ipsilateral hip and femoral shaft fractures which were satisfactorily treated using this technique. The “rendezvous” technique is a simple method, with a good clinical outcome and a low complication rate that can be used to treat ipsilateral femoral neck and shaft fractures.

Case 1

A 36-year-old male chef sustained injuries when a heavy metal garage gate fell onto his right thigh. At presentation, he was hemodynamically stable and radiographs confirmed a minimally displaced petrochanteric fracture of the right hip with an ipsilateral middle to distal 1/3 femoral fracture. The unavailability of operating time required that his fractures be stabilized with temporary skeletal traction through the proximal tibia, before definitive treatment 72 h later. At surgery, the fractures were stabilized using the rendezvous technique as described below (Fig. 1) The patient had an uneventful peri-operative period and was allowed partial weight bearing. At his six week outpatients' clinic appointment, radiographs showed callus at the femoral fracture, and he was therefore permitted full weight bearing. One year after surgery, he has returned to full-time work and is able to participate in low impact recreational sporting activity (Fig. 2).

Case 2

A 34 year old male driver was involved in a high-speed motor vehicle accident in which he sustained a comminuted fracture at the junction of the proximal and middle 1/3 of his right femur in association with an ipsilateral undisplaced petrochanteric hip fracture. His condition was stable on admission and 24 h later he was taken to the operating theatre for definitive stabilization of his fractures. In theatre, with the aid of the C-arm, the femoral fracture was noted to extend well into the subtrochanteric region; therefore to

* Corresponding author at: Bungalow 5, Department of Clinical Surgical Sciences, Port of Spain General Hospital, Trinidad and Tobago.
E-mail address: mmmencia@me.com (M.M. Mencia).

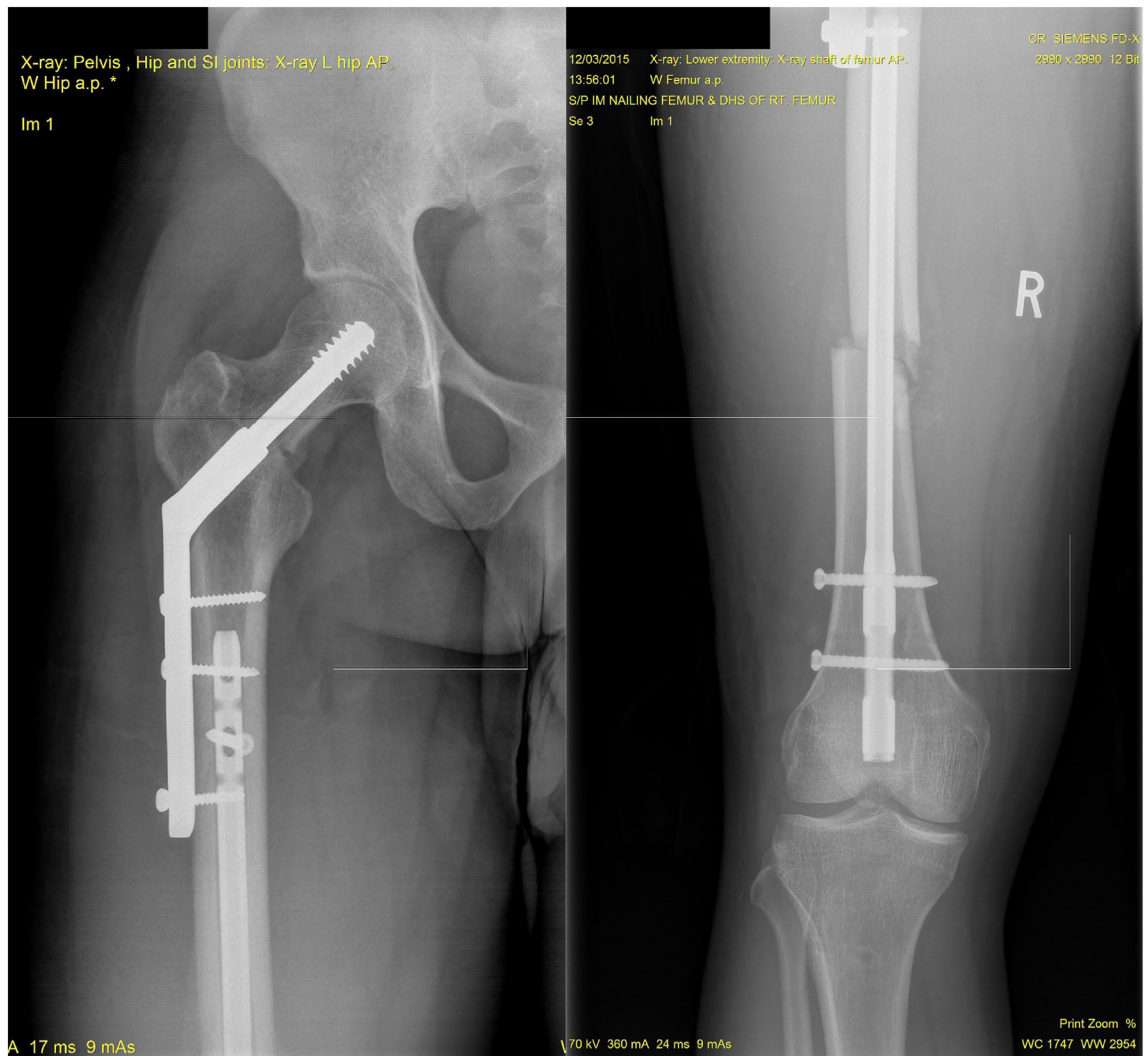


Fig. 1. A 36-year old male.

A: Anteroposterior radiograph of the hip with DHS and proximal extent of the RFN overlapped as per the “rendezvous” technique. Note that the 3rd screw hole in the side plate could not be used.

B: Anteroposterior radiograph of the femur with RFN stabilizing the femoral shaft fracture.

maximize stability, we used two locking bolts proximally within the retrograde femoral nail, followed by standard dynamic hip screw (DHS) fixation (Fig. 3).

Following 10 weeks of partial weightbearing, radiographs revealed sufficient callus at the proximal femur and he was then permitted unrestricted weight bearing. Eighteen months after surgery his fractures have healed satisfactorily and he has returned to full-time work (Fig. 4).

Case 3

A 34-year-old male front seat passenger was involved in a motor vehicle accident in which he sustained multiple injuries, including a liver laceration and a displaced intertrochanteric fracture in association with an ipsilateral midshaft fracture of his right femur. On admission he was noted to be in hypovolemic shock and required resuscitation. Due to the intra-abdominal injury, he was kept under the care of general surgery for observation, while his fractures were temporarily stabilized with skeletal traction. Four days later, his condition improved and he was cleared to undergo definitive stabilization of his fractures (Fig. 5). The patient made an uneventful post-operative recovery and was discharged three days after surgery but did not attend his outpatient clinic appointment. When contacted by telephone he indicated that for reasons of convenience he would have his follow up care within the private sector.

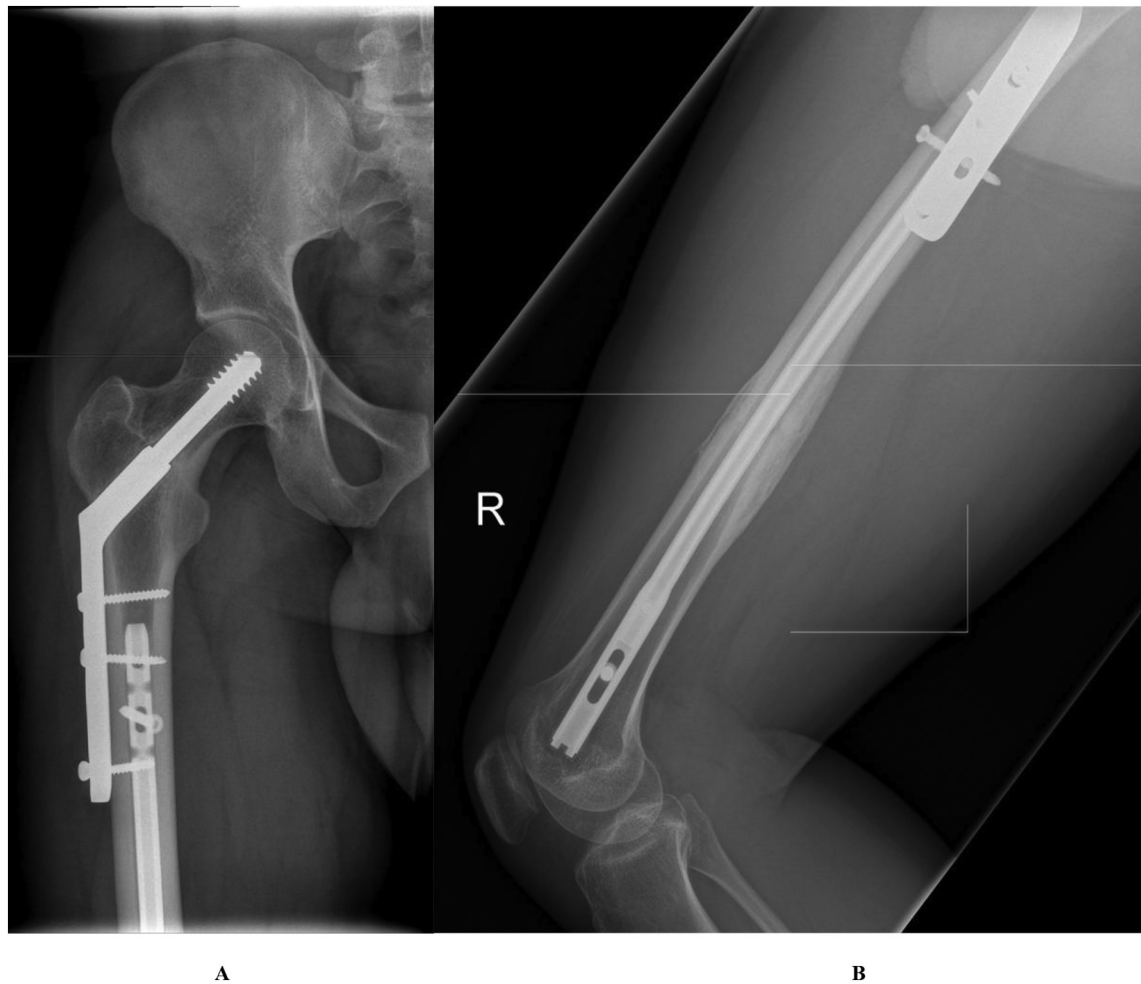

Fig. 2. A: Anteroposterior radiograph showing complete healing of the femoral neck fracture.
 B: Lateral radiograph showing consolidation of the femoral shaft fracture with no failure of implants.

Surgical technique

All patients were positioned supine on a radiolucent operating table and the knee was flexed to approximately 30°. Using a mid-patella approach, we created an entry point in the distal femur and passed the guide wire across the reduced fracture using C-arm fluoroscopy. Sequential reaming was performed until we heard cortical chatter. The appropriately sized retrograde femoral nail was inserted to the level of the lesser trochanter, and then statically locked. All incisions were closed, the foot of the table was removed and replaced with a standard traction end, and the patient repositioned in a routine fashion to allow for DHS fixation. The femoral neck fracture was reduced using inline traction through the lower limb, then, via a direct lateral approach a 4-hole 135° DHS was inserted. Despite the overlap between the proximal aspect of the nail and the side plate, we made every attempt to achieve bicortical fixation of all 4 screws, if this was not possible the screw hole was left unfilled or a unicortical screw used.

Discussion

Ipsilateral femoral neck and shaft fractures are uncommon, high energy injuries occurring in young adults and have an estimated incidence between 2 and 9% of all femoral fractures [1]. Seventy-five percent of the patients are male with a mean age of 35 years [1]. The femoral shaft fracture is characteristically comminuted and displaced representing a high energy injury, while the femoral neck fracture is usually basi-cervical, and minimally displaced in 60% of the cases, indicating that most of the energy has been imparted to the femoral shaft [2–4]. Femoral neck fractures in this scenario are easily missed preoperatively and recent studies report a misdiagnosis rate of 6–22% [4]. These injuries raise several controversial points including, which injury should be stabilized first and the optimal implant choice for treatment [1,5]. Typically, the surgeon has to choose between a single construct, such as a cephalomedullary nail (CMN), and a dual construct like a retrograde femoral nail (RFN) and a dynamic hip screw (DHS)/cannulated hip screws.

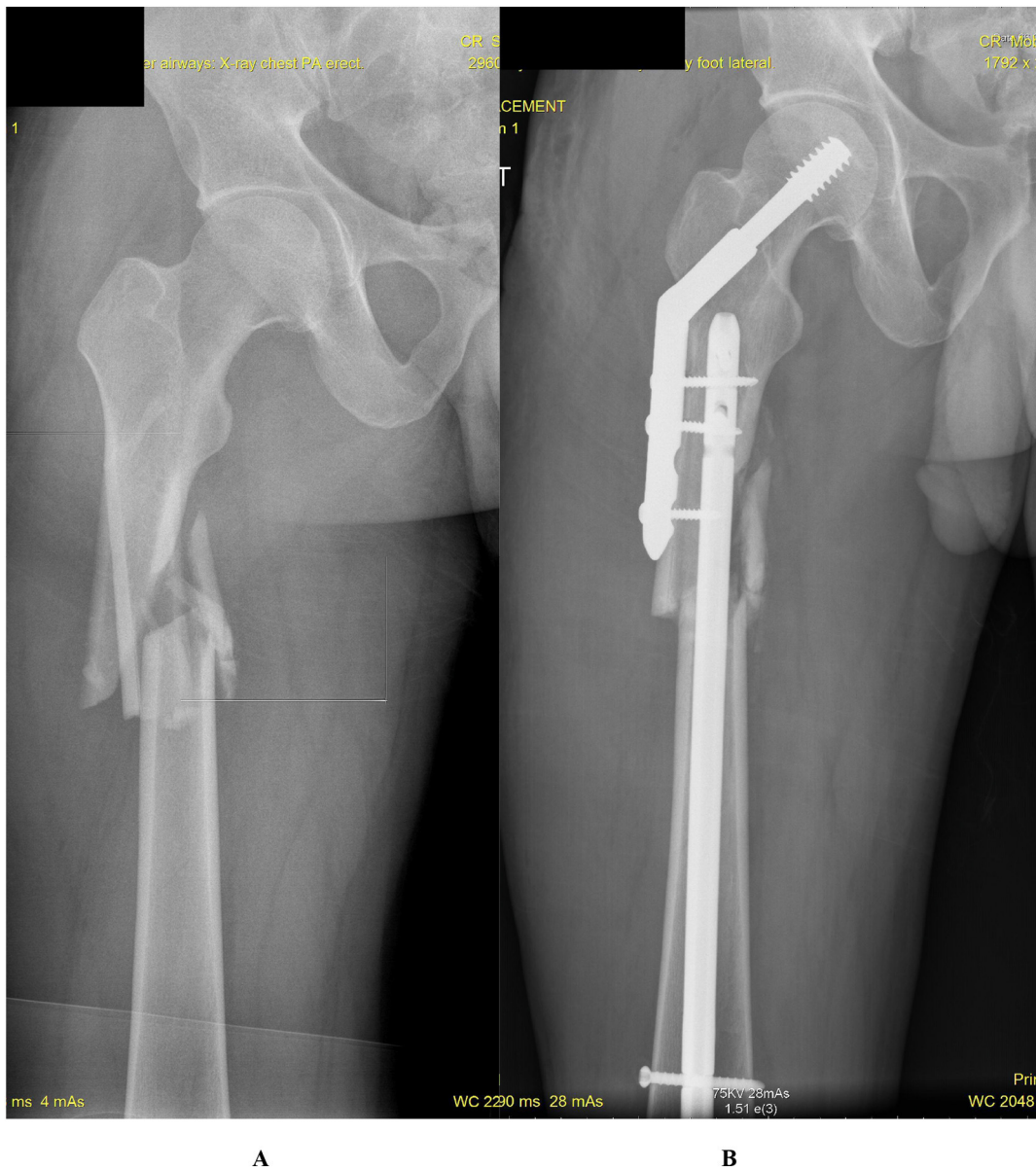


Fig. 3. A 34-year old male following a motor vehicle accident.

A: Anteroposterior radiograph of the femur showing comminuted fracture of the proximal femur with extension into the pertrochanteric region.
 B: Anteroposterior radiograph of the hip with dual implants. Note that the degree of comminution did not allow use of the 3rd screw hole in the side plate and only permitted a unicortical 4th screw. The RFN is inserted high into the femur and both anteroposterior proximal locking holes are used to increase stability.

Ostrum et al. compared dual construct retrograde femoral nailing and either cannulated screws or a dynamic hip screw in 95 patients. The authors reported no difference in union rates of the femoral neck or shaft between the groups [2]. Singh et al. compared several dual construct combinations of cannulated screws and compression plates with a reconstruction nail, reporting no difference in functional outcome. The small number of patients in the dual construct group did not permit statistical subgroup analysis [6].

In a large meta-analysis of 659 cases, no significant difference in outcome was found when a single construct was compared with a dual construct [7]. Boulton et al. in a 2014 systematic review, indicated their preference for a dual implant, femoral neck fracture first approach [5]. A more recent systematic review, found favorable outcomes in both treatment groups, and called for prospective, randomized trials to definitively guide treatment strategy [8].

We chose a dual construct, stabilizing the femoral shaft fracture first with a RFN and then using a DHS in an overlapping configuration, to treat the femoral neck fracture, the so-called “rendevous” technique [8].

There are several benefits of the “rendevous” technique, particularly in a low resource setting, such as the institution in which

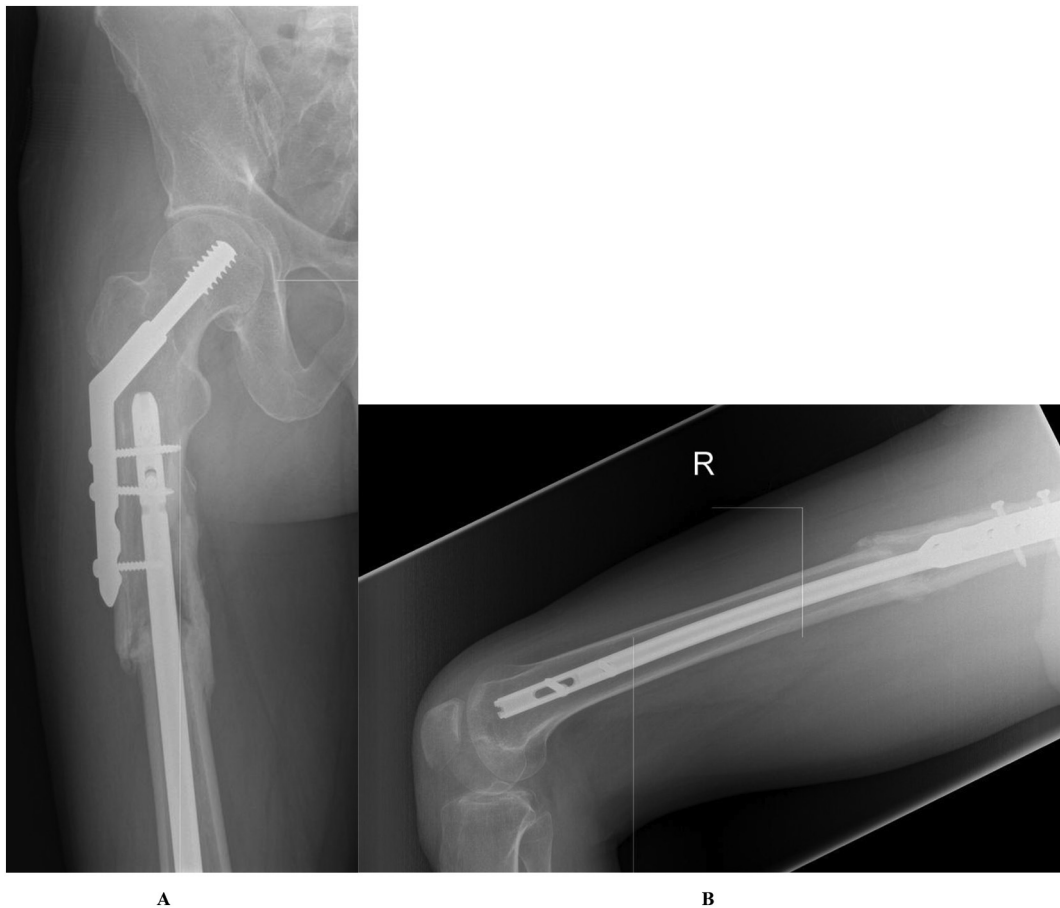

Fig. 4. A and B: Anteroposterior (A) and lateral radiographs (B) showing complete healing of the fractures without failure of implants.

the surgeries were performed by one of the authors (SH).

First, complex fracture patterns can be satisfactorily treated without the need for additional equipment. There is no immediate access to CMNs so we have modified the femoral nailing set to allow for a standard antegrade femoral nail to be placed in a reverse direction via the knee joint (in effect, functioning as a RFN). The stabilized femur allows effective traction through the limb to facilitate reduction of the femoral neck fracture which is then treated with a DHS, allowing overlap of the two implants, eliminating the risk of an inter-implant fracture. The surgical technique is simple, economical and familiar to most orthopedic surgeons. von Ruden et al. found no difference in outcome, comparing three techniques of fixation in a prospective cohort study of 65 patients, (mean follow up 2 years), but stated their preference for the rendezvous technique, other studies have shown similar successful outcomes supporting a dual implant approach [9–12].

Second, it is not uncommon for patients with this injury combination to have life threatening injuries which may take priority in treatment. In these instances the use of damage control orthopedics (DCO) is recommended. In those cases the femoral shaft can be promptly stabilized with an un-reamed RFN, this will reduce pain, blood loss and allow for easier nursing care, allowing time for the patient's general condition to improve, at which time the femoral neck fracture can be treated with a DHS [8]. The use of a single CMN in these circumstances is likely to result in longer operating times and increased blood loss, as well as compromised reduction at one or both fracture sites [11,13].

Third, the femoral shaft fracture has been shown to have lower healing rates (78.1% vs 90.6%, $p = 0.11$) and prolonged healing times (35 weeks vs 16 weeks, $p < 0.001$) versus the femoral neck fracture which directly correlate with patient satisfaction [14]. Delayed union or nonunion may necessitate additional surgical measures including plate stabilization and bone grafting or complex revision surgery in the case of a CMN. In the case of dual implants, the RFN can be simply dynamized by removing the distal locking bolts to allow compression at the shaft fracture site, without compromising the stability of the femoral neck fracture, which would not be possible with a CMN. If not successful then healing may be further encouraged with the use of closed exchange nailing without violation of the soft tissue envelope.

At all times, the surgical decision making process takes into consideration several factors namely, but not limited to, surgical skill, patient factors and infrastructural resources [15]. Arguably, decision making is made more difficult in a low resource setting where an error of judgment may result in significant complications which may be difficult to remedy at the local facility. Given the

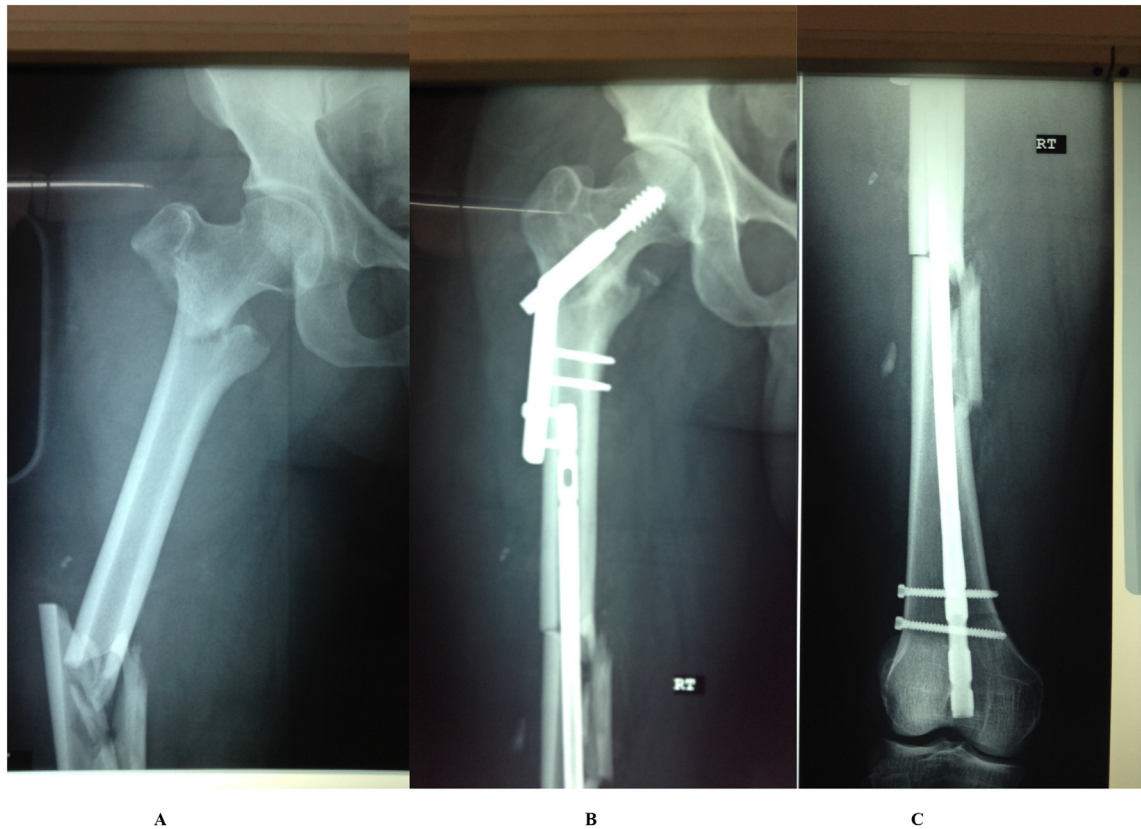


Fig. 5. A 36-year old male with a liver laceration.

A: Anteroposterior radiograph of the femur showing a displaced intertrochanteric fracture and a comminuted midshaft femoral fracture.

B: Anteroposterior radiograph of the hip showing good reduction of both fractures. Note that both the 3rd and 4th screws in the side plate are uncortical.

C: Anteroposterior radiograph of the femoral shaft with RFN in situ.

economies of scale it is not cost-effective to have a dedicated CMN system available locally in Tobago to treat these uncommon fracture combinations. We have found that the dual implant “rendezvous” technique for treating these injuries to be a simple and economically feasible option, which provides a good clinical outcome in a low-resource environment without easy access to tertiary level care.

Author contributions

Seun Harewood: Conceptualization, Data curation, Writing-original draft
 Marlon M. Mencia: Conceptualization, Writing-review & editing
 Patrick Harnarayan: Writing-review & editing.

Source of funding

None.

Previous presentations

This manuscript was presented as a podium presentation at the annual Caribbean Association of Orthopedic Surgeons Meeting at the Hyatt Hotel, Oct 4–6th 2018 in Trinidad.

Declaration of competing interest

None.

References

- [1] C.B. Jones, J.B. Walker, Diagnosis and management of ipsilateral femoral neck and shaft fractures, *The Journal of the American Academy of Orthopaedic Surgeons* 26 (2018) e448–e454.
- [2] R.F. Ostrum, P. Tornetta 3rd, J.T. Watson, et al., Ipsilateral proximal femur and shaft fractures treated with hip screws and a reamed retrograde intramedullary nail, *Clin. Orthop. Relat. Res.* 472 (2014) 2751–2758.
- [3] A.E. Peljovich, B.M. Patterson, Ipsilateral femoral neck and shaft fractures, *The Journal of the American Academy of Orthopaedic Surgeons* 6 (1998) 106–113.
- [4] L.K. Cannada, T. Viehe, C.A. Cates, et al., A retrospective review of high-energy femoral neck-shaft fractures, *J. Orthop. Trauma* 23 (2009) 254–260.
- [5] C.L. Boulton, A.N. Pollak, Special topic: ipsilateral femoral neck and shaft fractures—does evidence give us the answer? *Injury* 46 (3) (2015) 478–483.
- [6] R. Singh, R. Rohilla, N.K. Magu, et al., Ipsilateral femoral neck and shaft fractures: a retrospective analysis of two treatment methods, *J. Orthop. Traumatol.* 9 (2008) 141–147.
- [7] A. Alho, Concurrent ipsilateral fractures of the hip and femoral shaft: a meta-analysis of 659 cases, *Acta Orthop. Scand.* 67 (1996) 19–28.
- [8] K. Mohan, P. Ellanti, H. French, et al., Single versus separate implant fixation for concomitant ipsilateral femoral neck and shaft fractures: a systematic review, *Orthop Rev (Pavia)* 11 (2019) 7963.
- [9] C. von Ruden, M. Tauber, A. Woltmann, et al., Surgical treatment of ipsilateral multi-level femoral fractures, *J. Orthop. Surg. Res.* 10 (2015) 7.
- [10] A. Bedi, M.A. Karunakar, T. Caron, et al., Accuracy of reduction of ipsilateral femoral neck and shaft fractures—an analysis of various internal fixation strategies, *J. Orthop. Trauma* 23 (2009) 249–253.
- [11] S. Kang, M.P. McAndrew, K.D. Johnson, The reconstruction locked nail for complex fractures of the proximal femur, *J. Orthop. Trauma* 9 (1995) 453–463.
- [12] J.T. Watson, B.R. Moed, Ipsilateral femoral neck and shaft fractures: complications and their treatment, *Clin. Orthop. Relat. Res.* (2002) 78–86.
- [13] P.R. Wolinsky, K.D. Johnson, Ipsilateral femoral neck and shaft fractures, *Clin. Orthop. Relat. Res.* (1995) 81–90.
- [14] M.C. Tsai, C.C. Wu, C.W. Hsiao, et al., Reconstruction intramedullary nailing for ipsilateral femoral neck and shaft fractures: main factors determining prognosis, *Chang Gung Med. J.* 32 (2009) 563–573.
- [15] C. Gunaratnam, M. Bernstein, Factors affecting surgical decision-making—a qualitative study, *Rambam Maimonides Med J* 9 (2018).