

Contents lists available at [ScienceDirect](#)

## International Journal of Surgery Case Reports

journal homepage: [www.casereports.com](http://www.casereports.com)

# Invasive lobular carcinoma of the breast with extracellular mucin: A case report



G.S. Gómez Macías<sup>a,\*</sup>, J.E. Pérez Saucedo<sup>a</sup>, S. Cardona Huerta<sup>b</sup>, M. Garza Montemayor<sup>c</sup>, C. Villarreal Garza<sup>d</sup>, I. García Hernández<sup>a</sup>

<sup>a</sup> Department of Pathology, Hospital San José of Tecnológico de Monterrey, Mexico

<sup>b</sup> Center for Treatment and Diagnosis of breast, Hospital San José, Tecnológico de Monterrey, Mexico

<sup>c</sup> Imaging Center Diagnostic of Breast, Hospital San José of ITESM, Mexico

<sup>d</sup> Center of Breast Cancer, Hospital San José of ITESM, Mexico

## ARTICLE INFO

### Article history:

Received 4 March 2016

Received in revised form 29 May 2016

Accepted 30 May 2016

Available online 3 June 2016

### Keywords:

Lobular breast carcinoma

Mucin secretion

Breast

Case report

## ABSTRACT

**BACKGROUND:** Invasive lobular carcinoma is the second most common histological type of breast carcinoma, accounting for approximately 5%–15% of all invasive breast cancers. The extracellular mucin secretion is by default a feature of ductal carcinoma. Only four cases of infiltrative lobular carcinoma with extracellular mucin have been reported.

**CASE SUMMARY:** A 60 year old female asymptomatic patient with palpable breast mass and architectural distortion by mammography on external upper quadrant of the right breast was diagnosed as invasive lobular carcinoma with extracellular mucin in the resection, confirmed with immunohistochemistry markers.

**DISCUSSION:** Previous report in the literature of four cases of Invasive lobular carcinoma of breast with extracellular mucin, all of them sharing the same histologic features: the presence of extracellular and intracellular mucin with appearance of infiltrates lobular carcinoma with signet ring cells and “Indian files”.

**CONCLUSION:** It is important to know that extracellular mucin production is not exclusive of ductal lesions and keep in mind the lobular carcinomas with extracellular mucin as a differential diagnosis.

© 2016 The Authors. Published by Elsevier Ltd on behalf of IJS Publishing Group Ltd. This is an open access article under the CC BY-NC-ND license (<http://creativecommons.org/licenses/by-nc-nd/4.0/>).

## 1. Background

The classic lobular carcinoma is characterized by discohesive cells with small nuclei, linear arrangements of cells infiltrating the stroma between collagen fascicles forming so-called ‘Indian files’ and low mitotic activity [1]. Lobular neoplasia and infiltrative lobular carcinoma may produce intracellular mucin, when the secretion is prominent; the cells have a signet ring configuration. Extracellular mucin secretion is a feature of ductal carcinoma; however cases have been reported some cases of lobular carcinoma with extracellular mucin [2]. Although generally accepted histological criteria serve to distinguish lobular from ductal carcinoma of the breast, this differential diagnosis may present a challenge in some variants of the tumors showing equivocal histological features, the e-cadherin immunostaining is very helpful in these cases [3]. It is important for pathologists to recognize the new entity of invasive lobular carcinoma with extracellular mucin because of the differential diagnosis is with the mucinous ductal carcinoma.

noma with extracellular mucin because of the differential diagnosis is with the mucinous ductal carcinoma.

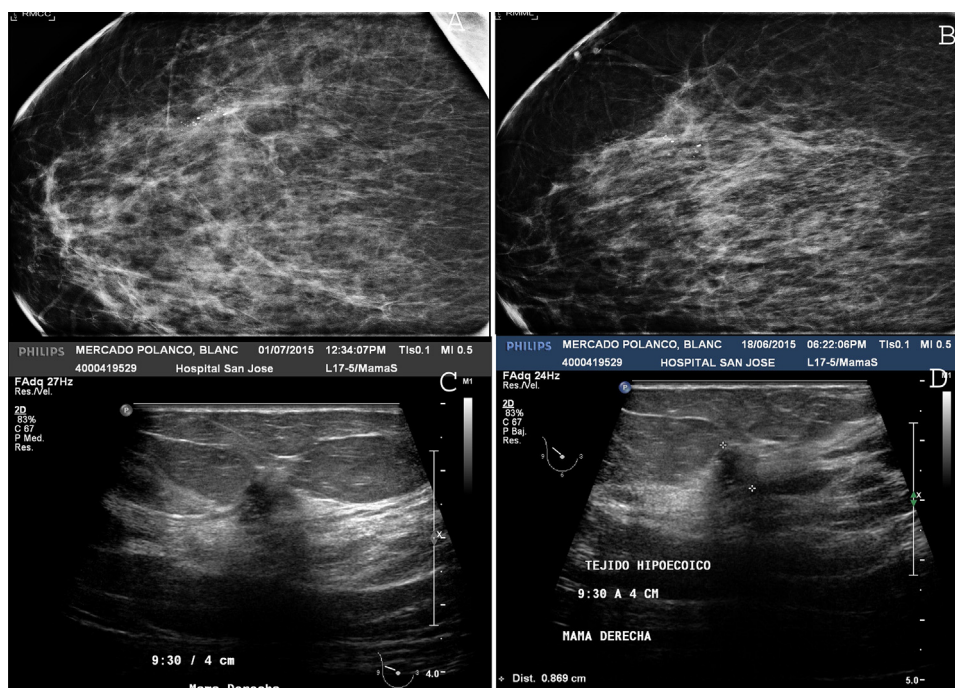
## 2. Case report

A 60-year-old Mexican woman asymptomatic patient without family history of cancer, with palpable breast mass on external upper quadrant of the right breast was presented to our clinic with diagnosis of breast cancer after a core biopsy performed. Previous mammograms report a group of microcalcifications and the external histopathologic report was an infiltrating ductal carcinoma. Paraffin block and slides review showed an infiltrating carcinoma with secretory characteristics associated to ductal carcinoma in situ of intermediate grade. PAS and alcian blue histochemistry highlighted the secretory component of this carcinoma.

Radiological imaging with tomosynthesis, digital mammography and ultrasound were performed. Digital mammography showed on external upper quadrant of the right breast architectural distortion associated with a group of fine pleomorphic microcalcifications of 17 mm in largest diameter. On the left breast several groups of amorphous low dense microcalcifications were observed. Directed ultrasound on right breast showed a hypoechoic area on

\* Corresponding author at: Department of pathology, Hospital San José of Institute Technology of Superior Studies of Monterrey, Av. Morones Prieto #3000 Pte, Col. Los Doctores, CP 64710 Monterrey, Nuevo León, México.

E-mail address: [bpositivo66@hotmail.com](mailto:bpositivo66@hotmail.com) (G.S. Gómez Macías).



**Fig. 1.** (A) Magnification views in the CC. (B) Lateral projections of the right breast (upper outer quadrant) demonstrate a focal asymmetric density with architectural distortion associated to round and amorphous calcifications. (C, D) Sonographic image of the right breast demonstrates 8.6 mm mixed echogenicity irregular mass at the 9:30 position, approximately 4 cm from the nipple.

the external upper quadrant corresponding to the architectural distortion on mammography. Right axillary ultrasound showed multiple hypoechoic lymph nodes with focal cortex enlargement (Fig. 1).

The patient's case was presented and reviewed by the multidisciplinary Tumor Board in the Breast Unit at "Hospital San Jose at Tecnológico de Monterrey" and in the presence of a clinical resectable disease categorized as T1N0M0 was scheduled for surgery. A lumpectomy and sentinel lymph node biopsy was performed, with no complications. A total of 4 sentinel lymph nodes were resected.

On gross examination the lumpectomy specimen had an irregular fibrotic area measuring  $2.0 \times 1.5$  cm that was located away from the margins grossly. The microscope exam of this area showed a dense fibrotic stroma with multiple extracellular mucin lakes of small diameter (Fig. 2A, B). Inside these lakes were floating numerous tumor cells of small to medium size, with scant to moderate amount of eosinophilic cytoplasm. Some of these cells exhibit intracellular mucin also, giving the appearance of signet ring cell component. At last, other areas of the tumor consisted of classic lobular invasive carcinoma, with single cell infiltration (Fig. 2C, D). Final tumor size was of 9 mm. In situ carcinoma was also observed.

On immunohistochemistry examination, the tumor was positive for estrogen receptors with a combined score of Allred of 7 (proportion 5, intensity 2), progesterone receptors was positive in the 90% of the cells and Her2-neu and e-cadherin were negatives (Fig. 3). All margins were negative for in situ or invasive carcinoma. The tumor was graded with a modified Scarff Bloom Richardson score of 5 and the four lymph node were reported negative for metastases. With this information the tumor was assigned with a pathologic T1b, N0, MX. We discussed the possibility of chemotherapy due to immunohistochemically report (ER+, PR+), however, the benefit of chemotherapy is unknown and taking into account tumor size and histological grade, we decided adjuvant treatment with tamoxifen 20 mg orally daily for 5 years and radiation therapy to

the breast. Currently the patient is under treatment with tamoxifen, asymptomatic and free of disease.

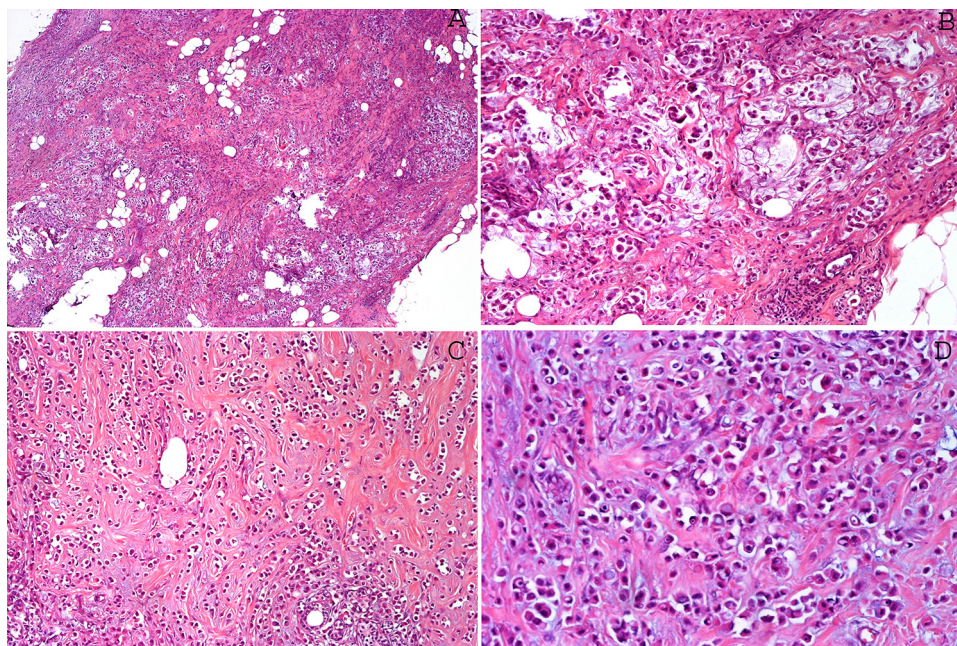
### 3. Discussion

Lobular carcinoma represents the second most common type of invasive carcinoma with 5–15% of all invasive carcinomas. Histologically is composed by non-cohesive cells distributed in a single cell pattern that immerse on fibrotic stroma and possess a low mitotic index. Another characteristics of the cells is that they have cytoplasmic mucin, and when it is prominent gives the appearance of a signet ring cell. Histologic patterns of lobular carcinoma are classic, solid, alveolar, pleomorphic, tubulolobular, signet ring cell and mixed types [4,5]. We present a case with classic lobular carcinoma features but with the rare characteristic of extracellular mucin lakes. This feature is rare but has been documented previously on the literature [2,6,7].

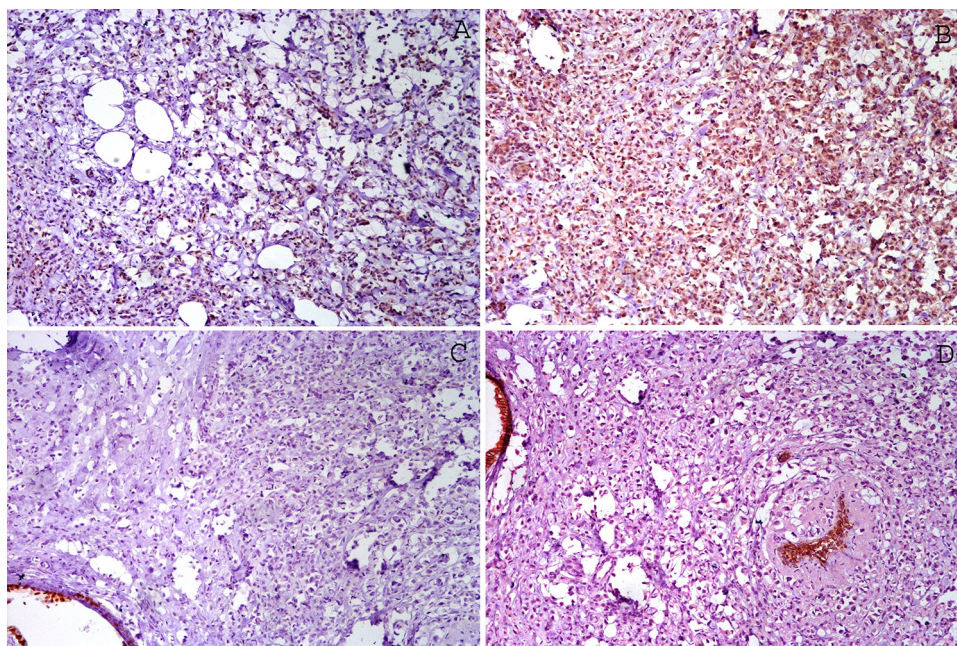
Invasive lobular carcinoma shows the characteristic loss of expression of e-cadherin, which is a helpful immunohistochemistry tool to differentiate lobular from ductal carcinomas. In our case the e-cadherin expression is complete absent, so the lobular nature of the neoplasm is confirmed. On receptor expression, until 95% of the lobular carcinomas are estrogen or progesterone receptor positive, and typically do not express Her2 [8,9]. On the previous reported cases of lobular carcinoma with extracellular mucin production, only the one described by Yu et al. had expression of Her2 [10].

The differential diagnosis of this case includes mucinous carcinoma, mixed ductal and mucinous carcinoma, papillary mucinous neoplasm and mucocele lesions, but all the above are ductal related and express e-cadherin [11].

In conclusion we report a rare histologic variant of lobular carcinoma. To our knowledge there has been only four previous cases reported, therefore, at this point, it is important to recall that extracellular mucin production is not exclusive of ductal lesions. The



**Fig. 2.** (A) On panoramic view the tumor is composed of multiple groups of neoplastic cells immerse on extracellular mucin within a fibrotic stroma (hematoxylin-eosin, original magnification  $\times 25$ ). (B) Extracellular mucin lakes with are the prominent characteristic of the tumor. (C, D) Other areas of the tumor show the classic pattern of lobular carcinoma with single cell infiltration.



**Fig. 3.** (A) ER was positive with a combined score of Allred of 7 (proportion 5, intensity 2) (B) PR was positive in the 90% of the cells. (C) Her2-neu negative. (D) E-cadherin negative, with internal control positive.

distinction needs to be made in order to give the patient the correct treatment.

**Competing interests**

None.

**Funding**

None.

**Ethical approval**

This article does not involve patients.

**Consent**

This study does not use patients or volunteers.

**Author contribution**

All author contributed equally in the conception and design, acquisition of data, analysis and interpretation of data, drafting the article and revising it critically for important intellectual content.

**Guarantor**

There is no Guarantor.

**References**

- [1] J. Rosai, Breast, in: J. Rosai (Ed.), Rosai and Ackermans Surgical Pathology, 10th ed., Mosby, An Imprint of Elsevier, 2011, pp. 1659–1770.
- [2] M. Rosa, A. Mohammadi, S. Masood, Lobular carcinoma of the breast with extracellular mucin: new variant of mucin producing carcinomas? *Pathol. Int.* 59 (2009) 405–409.
- [3] D.J. Dabbs, S.J. Schnitt, F.C. Geyer, B. Weigelt, et al., Lobular neoplasia of the breast revisited with emphasis on the role of E-cadherin immunohistochemistry, *Am. J. Surg. Pathol.* 37 (July (7)) (2013) e1–11.
- [4] X. Sastre-Garau, M. Jouve, B. Asselain, et al., Infiltrating lobular carcinoma of the breast. Clinicopathologic analysis of 975 cases with reference to data on conservative therapy and metastatic patterns, *Cancer* 77 (1996) 113–120.
- [5] M.J. Borst, J.A. Ingold, Metastatic patterns of invasive lobular versus invasive ductal carcinoma of the breast, *Surgery* 14 (1993) 637–641.
- [6] V.B. Bari, S.U. Bholay, K.C. Sane, Invasive lobular carcinoma of the breast with extracellular mucin—a new rare variant, *J. Clin. Diagn. Res.* 9 (April (4)) (2015).
- [7] H. Haltas, R. Bayrak, S. Yenidunya, et al., Invasive lobular carcinoma with extracellular mucin as a distinct variant of lobular carcinoma: a case report, *Diagn. Pathol.* 6 (August (7)) (2012) 91.
- [8] B. Zafrani, et al., High sensitivity and specificity of immunohistochemistry for detection of hormone receptors in breast carcinoma: comparison with biochemical determination in a prospective study of 793 cases, *Histopathology* 37 (2000) 536–545.
- [9] P. Lal, L.K. Tan, B. Chen, Correlation of HER-2 status with estrogen and progesterone receptors and histologic features in 3,655 invasive breast carcinomas, *Am. J. Clin. Pathol.* 123 (2005) 541–546.
- [10] J. Yu, R. Bhargava, D.J. Dabbs, Invasive lobular carcinoma with extracellular mucin production and HER-2 overexpression: a case report and further case studies, *Diagn. Pathol.* 15 (June (15)) (2010) 36.
- [11] W.T. Yang, D.L. Li, Mucoceles and mucocele-like lesions of breast, *Zhonghua Bing Li Xue Za Zhi* 38 (September (9)) (2009) 633–636.

**Open Access**

This article is published Open Access at [sciedirect.com](http://sciedirect.com). It is distributed under the [IJSCR Supplemental terms and conditions](#), which permits unrestricted non commercial use, distribution, and reproduction in any medium, provided the original authors and source are credited.