

A Cryptogenic Case of Fulminant Fibrosing Organizing Pneumonia

Takehiko Kobayashi¹, Masanori Kitaichi^{2,4}, Kazunobu Tachibana^{1,2}, Yutaro Kishimoto^{1,5}, Yasushi Inoue¹, Tomoko Kagawa^{1,2}, Toshiya Maekura¹, Chikatoshi Sugimoto², Toru Arai², Masanori Akira^{2,6} and Yoshikazu Inoue²

Abstract

Cryptogenic organizing pneumonia (COP) generally responds well to corticosteroids with a favorable outcome. Rare cases of organizing pneumonia are rapidly progressive. Yousem et al. studied pathologic predictors of idiopathic bronchiolitis obliterans organizing pneumonia/COP with an unfavorable prognosis. Beardsley and Rassl proposed the name fibrosing organizing pneumonia (FOP). A 74-year-old female non-smoker presented with a 2-week history of dry cough followed by dyspnea and a fever. The clinical course was fulminant, but we successfully performed bronchoscopy. After the diagnosis of FOP, we treated the patient with mechanical ventilation and high-doses of steroids/immunosuppressants, which improved the disease.

Key words: cryptogenic organizing pneumonia (COP), fibrosing organizing pneumonia (FOP), rapidly progressive bronchiolitis obliterans organizing pneumonia, bronchoscopy

(Intern Med 56: 1185-1191, 2017)

(DOI: 10.2169/internalmedicine.56.7371)

Introduction

Cryptogenic organizing pneumonia (COP) is synonymous with idiopathic bronchiolitis obliterans organizing pneumonia (idiopathic BOOP), although COP is the preferred term. COP is a characteristic clinicopathologic disease condition that generally responds to steroids with a good outcome (1-3). Histopathologically, COP is defined by the filling of distal airways, alveolar ducts, and adjacent alveoli with fibromyxoid plugs of granulation tissue without findings characteristic of other diseases, such as hyaline membranes or abundant fibrin (3). It has been documented that COP usually responds to corticosteroid therapy with favourable outcomes (2-4). However, some patients exhibit a rapidly progressing disease that is often refractory to steroids and associated with poor outcomes (5-8). About 10% to

15% of idiopathic BOOP/COP patients are steroid-resistant and progressive (9, 10).

Rare cases previously classified as idiopathic BOOP/COP can progress to respiratory failure and death (3). Some of these cases present additional features of diffuse interstitial fibrosis, suggesting an alternative diagnosis, including organizing pneumonia superimposed on an unusual interstitial pneumonia lesion (3). The 2013 statement of the international multidisciplinary classification of the idiopathic interstitial pneumonias mentioned “a fibrosing variant of OP” in the section of COP and pointed out that some patients with this pattern of mixed fibrosis and organizing pneumonia have underlying polymyositis or antisynthetase syndrome (11). In 2013, Beardsley and Rassl used the term fibrosing organizing pneumonia (FOP) alluding to the histologic features of steroid-resistant idiopathic BOOP/COP (9, 11, 12). Some articles reported cases of COP with

¹Department of Internal Medicine, National Hospital Organization Kinki-Chuo Chest Medical Center, Japan, ²Clinical Research Center, National Hospital Organization Kinki-Chuo Chest Medical Center, Japan, ³Department of Pathology, National Hospital Organization Kinki-Chuo Chest Medical Center, Japan, ⁴Department of Pathology, National Hospital Organization Minami Wakayama Medical Center, Japan, ⁵Department of Respiratory Medicine, Iwata City Hospital, Japan and ⁶Department of Radiology, National Hospital Organization Kinki-Chuo Chest Medical Center, Japan

Received for publication March 4, 2016; Accepted for publication August 15, 2016

Correspondence to Dr. Yoshikazu Inoue, giichi@kch.hosp.go.jp

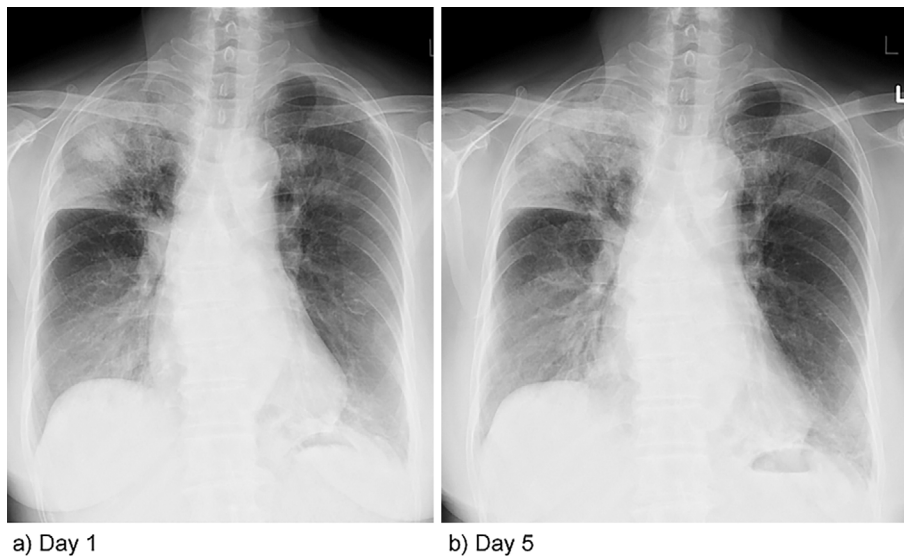


Figure 1. (a) Chest X-ray taken on Day 1 showing bilateral pulmonary infiltrates, especially in the right upper and right lower lung fields. (b) Chest X-ray taken on Day 5 showing progressive worsening of the pulmonary infiltrates, especially in the right upper and lower and left lower lung fields.

severe prognoses (5, 9, 10). Therefore, it is essential and important to establish a rapid histologic diagnosis. The clinical course of rapidly progressive idiopathic BOOP/COP is fulminant, and we have not been able to evaluate the lung disease by surgical lung biopsies. Bronchoscopy is a less invasive procedure tool than a biopsy and may prove useful in such cases (13).

We herein report a case of rapidly progressive idiopathic BOOP/COP histologically diagnosed as FOP by transbronchial lung biopsy (TBLB) specimens with a favourable outcome by prompt drug therapies.

Case Report

A 74-year-old woman presented in September 2014 with a 2-week history of dry cough followed by progressive dyspnea and a fever. She was diagnosed with bacterial pneumonia 10 days later, for which she had received treatment with levofloxacin (500 mg/day orally) for 2 weeks, and was referred to our hospital with complaints of worsened dyspnea. She was a never-smoker and had not been exposed to known toxins. On an examination, she was alert and did not seem to be overtly sick. Her body temperature was 38.2°C. Pulse oximetry showed an oxygen saturation of 94% on ambient air. Fine crackles were heard in the bilateral lung fields without wheezing. Physical examination findings were negative for signs of connective tissue disease such as heliotrope rash or Gottron's sign.

Chest X-ray films showed right-sided predominant bilateral progressive pulmonary infiltrates (Fig. 1). High-resolution computed tomography (HRCT) of the chest revealed bilateral and progressive multiple areas of subpleural and peribronchial patchy consolidation with ground glass

opacities (Fig. 2).

An arterial blood gas analysis on room air revealed marked hypoxemia [partial pressure of oxygen (PaO₂) 56.8 mmHg]. Blood and serologic examinations revealed leukocytosis (15.1×10⁴ cells/μL) and mild eosinophilia (510 eosinophils/μL); markedly increased values of C-reactive protein (CRP) (23.34 mg/dL), erythrocyte sedimentation rate (ESR; 115 mm/60 minutes), and ferritin (1,725 ng/mL; normal female range: 3.6-11.4); and mildly-to-moderately increased values of surfactant protein-D (SP-D) (141.9 ng/mL; normal <110) and surfactant protein-A (SP-A) (92.3 ng/mL; normal <43.8). There was no notable increase in the value of Krebs von den Lungen-6 (KL-6) (Table and Fig. 3).

On the fourth hospital day when the patient was transferred to the respiratory care unit, we managed to perform bronchoscopy under a clinical suspicion of organizing pneumonia. Bronchoalveolar lavage fluid (BALF) from the right B₅^a showed a cell count of 1.14×10⁵ cells/mL, and a cellular analysis of the BALF revealed increased neutrophils (23.8%) and lymphocytes (5.2%), with a CD4⁺/CD8⁺ ratio of 3.2. No pathogens were cultured. A TBLB obtained two samples from the right upper lobe (rtB₆^b) and right lower lobe (rtB₈^b and rtB₉^b), and the TBLB specimens revealed histologic features of FOP (Fig. 4). One specimen from the right upper lobe showed hyalinisation and fibrosis of the central core of the Masson body, and another sample also from the right upper lobe showed granulation tissues in many terminal air spaces, mainly of the alveolar ducts, with adhesion of the alveolar duct walls due to intervening granulation tissues (obliterative alveolar duct fibrosis) and foamy cells in the alveolar spaces (12) (Fig. 4e-h). The sample from the right lower lobe showed granulation tissues mainly in the alveolar ducts without adhesions of the alveolar duct walls. Another

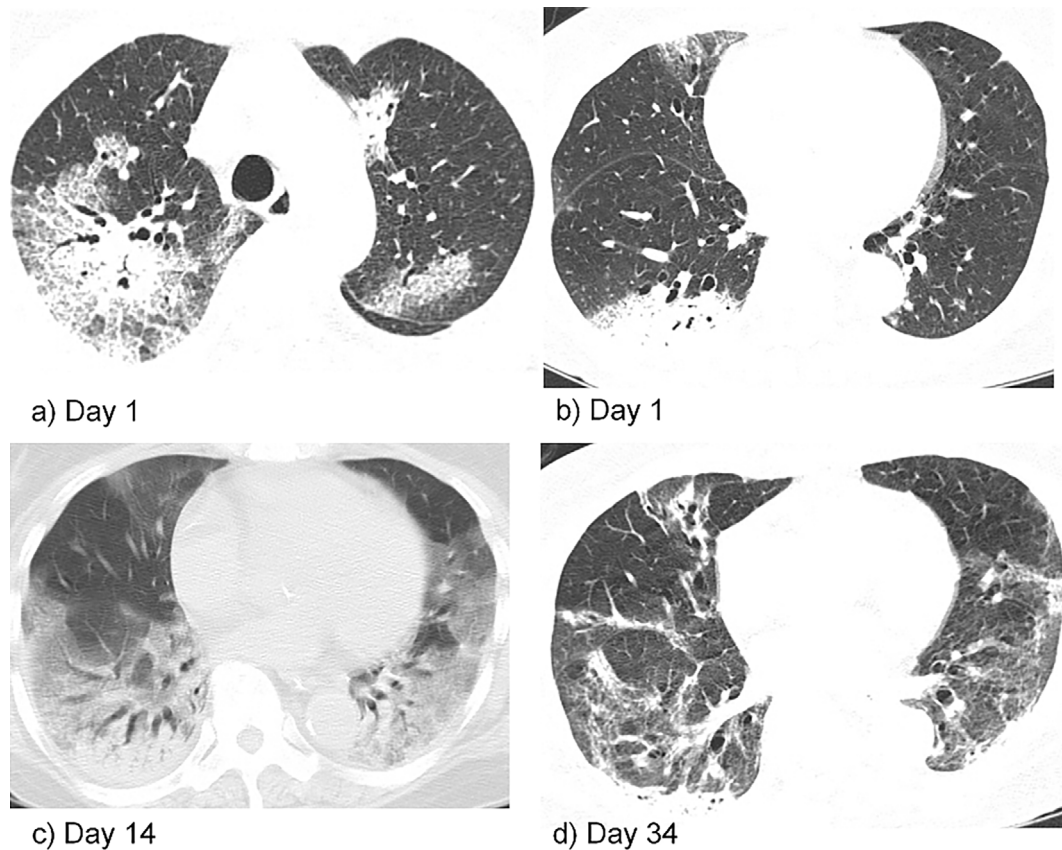


Figure 2. High-resolution computed tomography (HRCT) of the chest: (a, b) HRCT of the upper and lower lung fields on Day 1 showing bilateral multiple patchy alveolar opacities with a peripheral predominance. (c) HRCT on Day 14 showing bilateral worsening of alveolar opacities with air bronchograms in the lower lung fields. (d) HRCT of the lower lung fields on Day 34 showed gradual disappearance of the bilateral alveolar opacities with some residual abnormal lung shadows and tortuosity of bronchovascular shadows in the lower lung fields

Table. Results of a Blood Examination at Admission.

WBC	15.1×10 ⁹ /L	KL-6	290 U/mL
Lymphocytes	81.9 %	SP-D	141.9 ng/mL
Neutrophils	9.4 %	SP-A	92.3 ng/mL
Monocytes	5.1 %	Ferritin	1,725 ng/mL
Eosinophils	3.4 %	CRP	24.34 mg/dL
Hb	8.8 g/dL	ESR	115 mm/h
Ht	31.9 %	ANA antibody	negative
Plt	5,280×10 ⁹ /L	ss-A antibody	negative
TP	6.9 g/dL	ss-B antibody	negative
Alb	2.1 g/dL	anti-Jo 1 antibody	negative
BUN	12.9 mg/dL	anti-synthetase antibody	negative
Crea	0.62 mg/dL	anti-neutrophil cytoplasmic antibody	negative
LDH	241 U/L	anti-cyclic citrullinated peptide antibody	negative

Ht: hematocrit, Plt: platelet, TP: total protein, Alb: albumin, BUN: blood urea nitrogen, KL-6: Krebs von Lungen-6, SP-D: surfactant protein-D, SP-A: surfactant protein-A, CRP: C-reactive protein, ESR: erythrocyte sedimentation rate, ANA: anti-nuclear antibody

sample from the right lower lobe showed fibrination in the alveolar ducts and infiltration of a few neutrophils in the fibrin. The fibrination did not show organisation. We considered the possibility of an artificial effect from the transbronchial biopsy (not shown). None of the four lung specimens

showed any malignant cells, granulomas, or significant infiltration of eosinophils or neutrophils (Fig. 4).

Empirical broad-spectrum antibiotics were initially administered. However, during the subsequent four days, the patient's condition continued to deteriorate, with worsening of

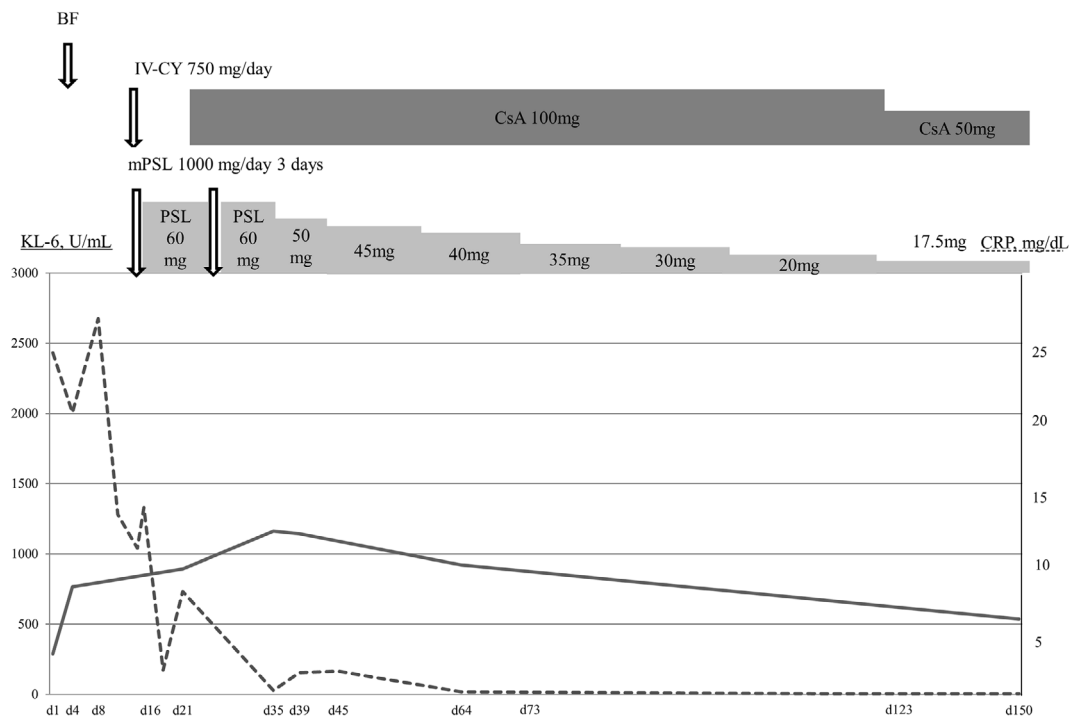


Figure 3. The clinical course of the present case between Days 1 and 150. A bronchoscopic examination with a TBLB and BAL was performed on Day 4, and drug therapy of methylprednisolone pulse therapy and intravenous cyclophosphamide was started on Day 8 (dotted line: CRP, solid line: KL-6). KL-6: Krebs von den Lungen-6, IV-CY: intravenous cyclophosphamide, CsA: cyclosporine, PSL: prednisolone, BF: bronchoscopy

chest radiograph findings (Fig. 1, 2) and hypoxemia. She developed dyspnea on the seventh hospital day. On the eighth hospital day, mechanical ventilation and intravenous methylprednisolone treatment (1,000 mg per day for three consecutive days) was started (Fig. 3). On the seventh hospital day, a histopathologic diagnosis of FOP was rendered by the lung pathologist of this article (Fig. 4). The patient received 750 mg/day cyclophosphamide (CY) intravenously in addition to corticosteroid therapy. Initially, despite these regimens, her chest radiograph findings and hypoxemia did not stop deteriorating. Therefore, 100 mg (2.0 mg/kg) cyclosporin A (CsA) was added. The chest radiograph findings and hypoxemia gradually improved, and she was successfully extubated on hospital day 22. The peribronchovascular consolidation revealed by chest radiography resolved steadily. She was discharged on hospital day 73 when prednisolone was tapered to 20 mg/day (Fig. 3). Her symptoms and the HRCT findings of the lungs improved during the follow-up 150 days later. She was fine 500 days later and did not develop any symptoms or signs of connective tissue disease (Fig. 3).

Discussion

To our knowledge, there have been no previous reports of idiopathic rapidly progressive idiopathic BOOP/COP confirming the histopathologic features of FOP by TBLB specimens in the English literature. The prompt histopathologic

diagnosis of FOP by TBLB enabled us to make a treatment decision on the eighth hospital day (Fig. 3)

Colby listed four findings as the major histologic features of BOOP in 1992: 1) patchy bronchiolitis obliterans with organizing pneumonia, 2) interstitial mononuclear cell infiltrates, variable in density, 3) alveolar space foam cells, and 4) absence of honeycombing or extensive interstitial fibrosis (14). Yousem et al. compared 10 cases of steroid-responsive idiopathic BOOP/COP (Group I) and 9 cases of steroid-resistant idiopathic BOOP/COP (Group II) to determine the histopathologic predictors (18 open lung biopsies and 1 lobectomy cases) (9). They pointed out the poor prognostic findings and listed the findings of the presence of background remodelling of the pulmonary parenchyma (scarring/interstitial fibrosis) and dense eosinophilic hyalinization of the fibromyxid plugs of air space collagen (9).

The 2002 American Thoracic Society/European Respiratory Society (ATS/ERS) classification of idiopathic interstitial pneumonias described the histologic features of organizing pneumonia as follows: 1) intraluminal organizing fibrosis in distal airspaces (bronchioles, alveolar ducts, and alveoli); 2) patchy distribution; 3) preservation of lung architecture; 4) uniform temporal appearance; and 5) mild interstitial chronic inflammation. Among the seven pertinent negative findings for organizing pneumonia, the characteristic of “lack of interstitial fibrosis (except for incidental scars or apical fibrosis)” was noted (3).

Beardsley and Rassel proposed FOP to include the his-

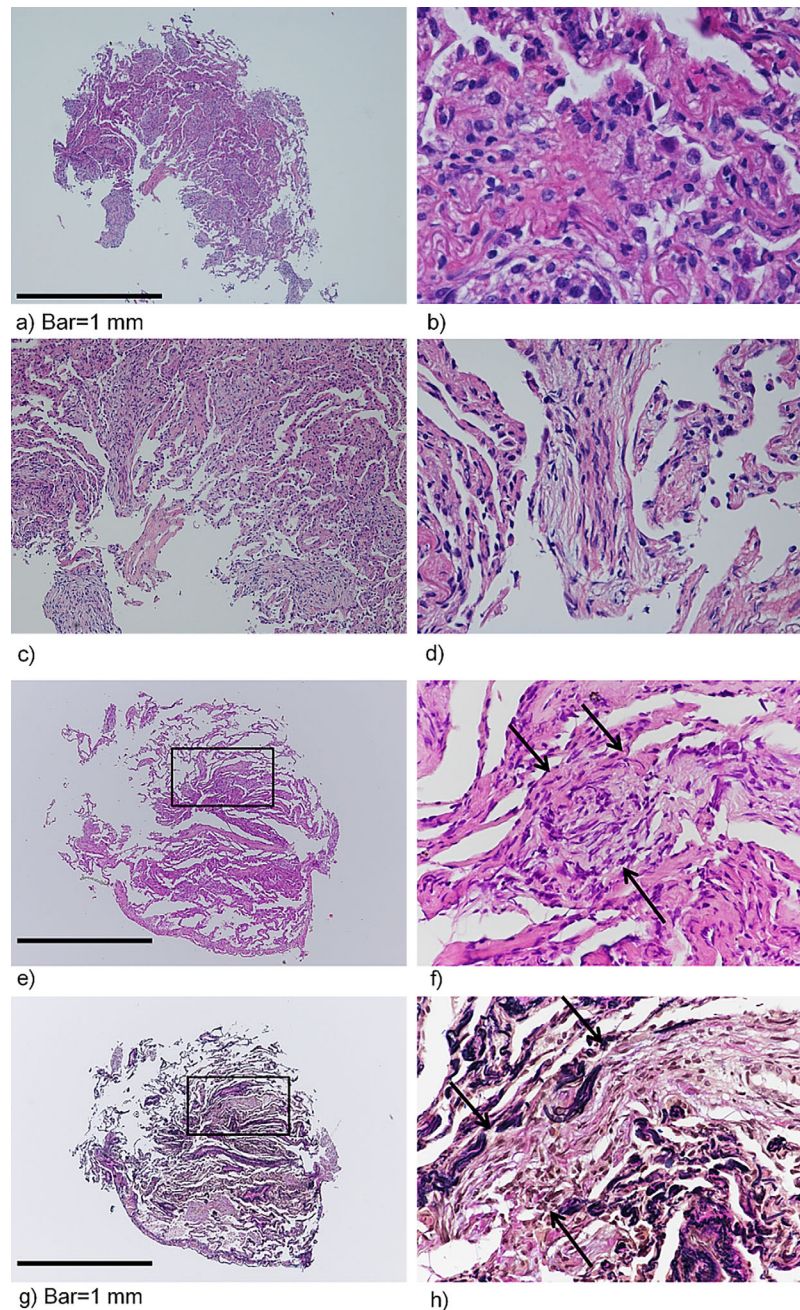


Figure 4. A transbronchial lung biopsy was performed for the right upper and lower lobes. (a-d) Tissue from the rtS²_b. (a) The tissue showed granulation tissues (Masson bodies) formed in the alveolar ducts and adjacent alveoli. (b) The tissue showed hyaline thickening of alveolar walls. (c, d) The tissue showed hyalinisation of the central core of the Masson body. (e-h) The tissue taken from the rtS²_b. (e) The tissue showed granulation in the alveolar ducts and adjacent alveolar spaces, as well as accumulation of foamy cells in the alveolar spaces (lower centre). Relatively normal alveolar walls were noted in the adjacent area of organizing pneumonia. (f) A higher magnification of the rectangular area of (e); the alveolar duct was obliterated with granulation tissue and the alveolar duct walls were adhesive due to intervening granulation tissue (arrowed). (g) An elastic tissue stain showed granulation tissues and foamy cells in the alveolar ducts and alveolar spaces. (h) A higher magnification of the rectangular area of (g); an alveolar duct was obliterated due to the presence of granulation tissue with adhesion of alveolar duct walls (arrowed). Because of the findings (a-d) and (e-h), we made a histologic diagnosis of fibrosing organizing pneumonia (FOP). The findings of (a-h) showed an organizing pneumonia pattern. However, obliterative alveolar duct fibrosis was not observed in previously reported cases of steroid-responsive idiopathic BOOP/COP (9, 17, 23, 24). Staining methods: a-f: Hematoxylin and Eosin staining; g, h: Weigert's elastic van Gieson stain. Magnification: a, e, g×4; c, ×10; b, d, f, h×40. Bar=1 mm.

tologic characteristics of dense hyalinisation and fibrosis of the central core of the Masson bodies and hyalinised fibrotic lesions of alveolar septa, as well as the obliterative fibrotic processes mainly in the alveolar ducts with loss of normal alveolar structure, based on the 1997 report of Yousem, Lohr, and Colby (9, 12). Some severe cases of OP have been published, most of which were diagnosed histologically by high-risk open-lung biopsies (9, 15, 16). Beardley and Rassel pointed out that collagenised Masson bodies become incorporated into the interstitium mainly at the alveolar duct level. To distinguish their diagnosis from diffuse alveolar damage, they showed the histologic finding of relatively normal adjacent alveolar walls in the obliterating fibrotic lesions at the level of the alveolar ducts [see Fig. 6 of Ref 12].

We propose the following histological definition of FOP (3, 11, 12, 14, 17, 23, 24): 1) intraluminal organizing fibrosis in distal airspaces (bronchioles, alveolar ducts, and alveoli); 2) patchy distribution; 3) preservation of lung architecture without honeycombing, even in the area of extensive obliterative alveolar duct fibrosis when observed by an elastic tissue stain; 4) uniform temporal appearance; 5) mild interstitial chronic inflammation; and 6) obliterative alveolar duct fibrosis with adhesions of alveolar duct walls due to the presence of air-space granulation tissues.

In the present case, the fibrotic lesions due to obliterative alveolar duct fibrosis were mild and focal that was observed in one focus as shown in Fig. 4e-h. This was considered to be due to the small size of the lung biopsy samples obtained by the transbronchial biopsy.

The 16 cases of idiopathic BOOP reported by Nagai et al. belonged to steroid-responsive idiopathic BOOP/COP according to the 1997 idiopathic BOOP/COP classifications by Yousem et al (9). The BAL data of those steroid-responsive cases showed a high lymphocytes percentage ($44.4 \pm 7.3\%$) with a low CD4⁺/CD8⁺ ratio (0.97 ± 1.35). However, the BALF data from 4 of 6 cases of rapidly progressive BOOP showed $\geq 26\%$ neutrophils (5 cases from Cohen et al. and 1 case from Lee et al.) (10, 15). The present case also showed an increased neutrophil proportion (23.8% of nucleated cells) with an increased CD4⁺/CD8⁺ ratio (3.2). Therefore, the BALF cell analysis suggested that steroid-responsive and steroid-resistant idiopathic BOOP/COP were different disease conditions. Cases of COP, according to the 2002 ATS/ERS classification of idiopathic interstitial pneumonias, mainly corresponded to those of steroid-responsive idiopathic BOOP/COP, similar to the 1997 description by Yousem et al. (9, 15, 17). High percentages of neutrophils in the BALF might suggest characteristics of steroid-resistant idiopathic BOOP/COP or FOP in the clinical setting of COP.

Bronchoscopy is a useful and low-invasive diagnostic tool. We performed BAL and a TBLB for this case study. A TBLB is commonly performed to confirm the tissue diagnosis of interstitial pneumonia (IP) (18) and appears to be an important diagnostic tool for the diagnosis of IPs; however,

the diagnostic yield of its histopathologic assessment varies and is influenced by factors such as the size of samples and the presence of crush artefacts due to the use of biopsy forceps (19). The accurate diagnostic yield of a TBLB of COP is low (20), and it is difficult to confirm the preservation of normal alveolar structure in the entire lung tissues due to the small size of the samples obtained with a TBLB.

The proposal of FOP is not yet well-defined and is still a relatively new concept. Its definition must be discussed further using more cases successfully histopathologically diagnosed as FOP by a surgical lung biopsy or TBLB. However, we were able to detect dense hyalinisation and fibrosis of the central core of the Masson body and hyalinised fibrotic lesions of alveolar septa in addition to the obliterative fibrotic lesions in the lumen of alveolar ducts (obliterative alveolar duct fibrosis) (Fig. 4). Therefore, we were able to make a diagnosis of FOP based on the clinical and radiological findings. One possible reason for our successful diagnosis using TBLB specimens was the fact that we performed the TBLB when the patient's pulmonary condition was worsening. Bronchoscopy may be a useful diagnostic tool in the clinical setting when encountering rapidly progressive idiopathic BOOP/COP or FOP.

Minimal data have been reported regarding alternative immunosuppressive agents in cases of corticosteroid-refractory OP or rapidly progressive idiopathic BOOP/COP (5-7). Some reports have suggested that early treatment with CY and CsA might be effective, especially in patients that failed to respond to treatment with corticosteroids alone (5, 6). We obtained a good outcome with CY and CsA in the FOP patient. Delayed treatment in rapidly progressive patients receiving steroid therapy can lead to poor outcomes. In our case, a TBLB by bronchoscopy contributed to an accurate pathologic diagnosis of FOP and a prompt decision on therapy. CY and CsA may be beneficial in FOP patients even without a rapid response to steroid treatment. These drug regimens should therefore be considered early for therapeutic trials in these cases.

Patients with connective tissue disorders seem to have a poorer prognosis than COP patients (21). The serologic tests conducted in the present case were all negative (Table). However, due to the unavailability of commercial anti-melanoma differentiation-associated gene 5 (MDA5) antibodies, we were unable to check for MDA5 antibodies, which are myositis-specific antibodies identified in the sera of patients with clinically amyopathic dermatomyositis (CADM) (22). The characteristics of anti-CADM-140-positive dermatomyositis-associated interstitial lung disease are high levels of ferritin, which is a known prognostic factor; a ground glass attenuation (GGA) pattern, a random GGA pattern, or low consolidation; and the absence of interlobular reticular opacities (22). Although the levels of ferritin were increased significantly in the present case, the radiological findings were not similar to those of anti-CADM-140-positive dermatomyositis-associated interstitial lung disease. We were therefore able to exclude this from our differential

diagnosis.

In summary, we presented a rapidly progressive case of FOP diagnosed based on TBLB specimens, including a histologic finding of obliterative alveolar duct fibrosis. The present case responded to drug treatment with high-dose methylprednisolone, CY, and CsA (Fig. 3). She remained idiopathic and well 500 days after the initial presentation in September 2014. The present case is important, as it suggests that bronchoscopic examination, including a TBLB and BAL, may be an important diagnostic tool for a prompt diagnosis and adequate therapy, as well as for predicting the prognosis of OP of unknown etiology.

The authors state that they have no Conflict of Interest (COI).

Acknowledgement

The authors are partially supported by a grant from the Diffuse Lung Disease Research Group from the Ministry of Health, Labour and Welfare, Japan, and a grant from the National Hospital Organisation Respiratory Network, Japan.

References

- Ryu JH. Classification and approach to bronchiolar diseases. *Curr Opin Pulm Med* **12**: 145-151, 2006.
- Epler GR. Bronchiolitis obliterans organizing pneumonia, 25 years: a variety of causes, but what are the treatment options? *Expert Rev Respir Med* **5**: 353-361, 2011.
- American Thoracic Society/European Respiratory Society International Multidisciplinary Consensus Classification of the Idiopathic Interstitial Pneumonias. This joint statement of the American Thoracic Society (ATS) and the European Respiratory Society (ERS) was adopted by the ATS board of directors, June 2001 and by the ERS Executive Committee, June 2001. *Am J Respir Crit Care Med* **165**: 277-304, 2002.
- Wells AU, Behr J, Costabel U, Cottin V, Poletti V, Richeldi L. Hot of the breath: mortality as a primary end-point in IPF treatment trials: the best is the enemy of the good. *Thorax* **67**: 938-940, 2012.
- Purcell IF, Bourke SJ, Marshall SM. Cyclophosphamide in severe steroid-resistant bronchiolitis obliterans organizing pneumonia. *Respir Med* **91**: 175-177, 1997.
- King TE Jr, Mortenson RL. Cryptogenic organizing pneumonitis. The North American experience. *Chest* **102**: 8-13, 1992.
- Koinuma D, Miki M, Ebina M, et al. Successful treatment of a case with rapidly progressive bronchiolitis obliterans organizing pneumonia (BOOP) using cyclosporin A and corticosteroid. *Intern Med* **41**: 26-29, 2002.
- Yoshinouchi T, Ohtsuki Y, Kubo K, Shikata Y. Clinicopathological study on two types of cryptogenic organizing pneumonitis. *Respir Med* **89**: 271-278, 1995.
- Yousem SA, Lohr RH, Colby TV. Idiopathic bronchiolitis obliterans organizing pneumonia/cryptogenic organizing pneumonia with unfavorable outcome: pathologic predictors. *Mod Pathol* **10**: 864-871, 1997.
- Cohen AJ, King TE Jr, Downey GP. Rapidly progressive bronchiolitis obliterans with organizing pneumonia. *Am J Respir Crit Care Med* **149**: 1670-1675, 1994.
- Travis WD, Costabel U, Hansell DM, et al. ATS/ERS Committee on Idiopathic Interstitial Pneumonias. An official American Thoracic Society/European Respiratory Society statement: Update of the international multidisciplinary classification of the idiopathic interstitial pneumonias. *Am J Respir Crit Care Med* **188**: 733-748, 2013.
- Beardsley B, Rassl D. Fibrosing organizing pneumonia. *J Clin Pathol* **66**: 875-881, 2013.
- Du Rand IA, Barber PV, Goldring J, et al; BTS Interventional Bronchoscopy Guideline Group. Summary of the British Thoracic Society guidelines for advanced diagnostic and therapeutic flexible bronchoscopy in adults. *Thorax* **66**: 1014-1015, 2011.
- Colby TV. Pathologic aspects of bronchiolitis obliterans organizing pneumonia. *Chest* **102**: 38S-43S, 1992.
- Lee J, Cha SI, Park TI, Park JY, Jung TH, Kim CH. Adjunctive effects of cyclosporine and macrolide in rapidly progressive cryptogenic organizing pneumonia with no prompt response to steroid. *Intern Med* **50**: 475-479, 2011.
- Alsaghir AH, Al-Mobeireek AF, Al-Jahdali H, Al-Eithan A, Al-Otaif H, Al-Dayel F. Bronchiolitis obliterans organizing pneumonia: experience at three hospitals in Riyadh. *Ann Saudi Med* **27**: 32-35, 2007.
- Nagai S, Kitaichi M, Itoh H, Nishimura K, Izumi T, Colby TV. Idiopathic nonspecific interstitial pneumonia/fibrosis: comparison with idiopathic pulmonary fibrosis and BOOP. *Eur Respir J* **12**: 1010-1019, 1998.
- Romagnoli M, Bigliuzzi C, Casoni G, et al. The role of transbronchial lung biopsy for the diagnosis of diffuse drug-induced lung disease: a case series of 44 patients. *Sarcoidosis Vasc Diffuse Lung Dis* **25**: 36-45, 2008.
- Kulshrestha R, Menon BK, Rajkumar, Vijayan VK. Role of a pattern-based approach in interpretation of transbronchoscopic lung biopsy and its clinical implications. *Indian J Chest Dis Allied Sci* **54**: 9-17, 2012.
- Poletti V, Cazzato S, Minicuci N, Zompatori M, Burzi M, Schiattone ML. The diagnostic value of bronchoalveolar lavage and transbronchial lung biopsy in cryptogenic organizing pneumonia. *Eur Respir J* **9**: 2513-2516, 1996.
- Epler GR, Colby TV, McLoud TC, Carrington CB, Gaensler EA. Bronchiolitis obliterans organizing pneumonia. *N Engl J Med* **312**: 152-158, 1985.
- Tanizawa K, Handa T, Nakashima R, et al. HRCT features of interstitial lung disease in dermatomyositis with anti-CADM-140 antibody. *Respir Med* **105**: 1380-1387, 2011.
- Kitaichi M. Differential diagnosis of bronchiolitis obliterans organizing pneumonia. *Chest* **102**: 44-49, 1992.
- Kitaichi M. Bronchiolitis obliterans organizing pneumonia (BOOP). In: *Basic and Clinical Aspects of Pulmonary Fibrosis*. Takishima T, Ed. CRC Press, Boca Raton, 1994: 463-488.

The Internal Medicine is an Open Access article distributed under the Creative Commons Attribution-NonCommercial-NoDerivatives 4.0 International License. To view the details of this license, please visit (<https://creativecommons.org/licenses/by-nc-nd/4.0/>).