

Received: 2012.11.30
Accepted: 2013.01.14

Usefulness of computed tomography virtual bronchoscopy in the evaluation of bronchi divisions

Michał Adamczyk¹, Grzegorz Tomaszewski², Patrycja Naumczyk, Ewa Kluczevska^{2,3}, Jerzy Walecki⁴

¹ Department Diagnostic Radiology, Central Clinical Hospital of the Ministry of Interior in Warsaw, Warsaw, Poland

² Department of Medical Radiology and Clinical Hospital No. 1, Silesian Medical University in Zabrze, Zabrze, Poland

³ Department of Radiology and Radiodiagnosics, Medical University of Silesia, Zabrze, Poland

⁴ Medical Centre of Postgraduate Education, Warsaw, Poland

Author's address: Adamczyk Michał, Department Diagnostic Radiology, Central Clinical Hospital of the Ministry of Interior in Warsaw, Wofoska 137 St., 02-507 Warsaw, Poland

Summary

Background:

Since introduction of multislice CT scanners into clinical practice, virtual bronchoscopy has gained a lot of quality and diagnostic potential. Nevertheless it does not have established place in diagnostics of tracheal and bronchi disorders and its potential has not been examined enough. Nowadays a majority of bronchial tree variants and lesions are revealed by bronchofiberoscopy, which is an objective and a relatively safe method, but has side effects, especially in higher-risk subjects. Therefore noninvasive techniques enabling evaluation of airways should be consistently developed and updated.

Material/Methods:

Material consisted of 100 adults (45 female, 55 male) aged between 18 and 65 years (mean 40 years, median 40.5 years, SD 14.02), who underwent chest CT examination by means of a 16-slice scanner. Every patient had normal appearance of chest organs, with the exception of minor abnormalities that did not alter airways route.

Results:

Divisions of bronchial tree to segmental level were evaluated and assigned to particular types by means of virtual bronchoscopy projection. In case of difficulties MPR or MinIP projection was used.

The frequency of lobar bronchi divisions other than the typical ones was in: right upper lobar bronchi 45%, left 55%; middle lobar bronchi 21%, lingula 26%; right lower lobar bronchi 28%, left 29%. Subsuperior bronchus or bronchi were found on the right side in 44% and on the left side in 37%. No dependency between types of bronchial divisions on different levels was found.

Key words:

CT • virtual bronchoscopy • anatomical variants

PDF file:

<http://www.polradiol.com/fulltxt.php?ICID=883765>

Background

Computed tomography virtual bronchoscopy imaging (VBCT) provides a possibility to navigate inside the respiratory tracts as well as to assess their walls and lumen. Virtual image of the bronchial tree results from volumetric reconstruction of the two-dimensional thin layers (<2 mm) obtained by multi-slice computed tomography. The parameters utilized to acquire VBCT images vary between centers and different scanners. However, it does not affect significantly the diagnostic capabilities of this method.

The first virtual CT images of bronchial lumen were obtained in the 90s of the 20th century, following the introduction of the spiral CT scanners. However, due to the poor quality of three-dimensional images, they rather showed the right direction than the credibility of the method. More advanced attempts to assess the bronchial lumen using computed tomography started approximately ten years ago, when the introduction of multi-slice CT systems significantly improved the quality of the bronchoscopic images. They were increasingly used in clinical practice as the systems improved their technological capabilities – the development of multi-slice scanners, relevant matrices, as well

as modern techniques of image acquisition and processing applications.

There are numerous studies in the literature showing a virtual image of pathologies within the bronchial lumen, and their correlation with bronchofiberoscopy [1–5], whereas only a few studies, mostly based on single slice CT scanners imaging, discuss the issue of possible use of CT imaging in the assessment of the anatomical variants of the bronchial tree. Multi-slice CT devices, which are nowadays available, make the assessment of bronchial tree anatomy much more precise than in the past. They provide a shorter scan time, which also reduces motion artifacts that can significantly lower the quality of three-dimensional imaging. Currently, using the virtual techniques in multi-slice scanners, it is possible to evaluate the bronchial tree down to the level of 6th/7th generation [2].

Clinical experience suggests that the most important problem in diagnostic bronchoscopy is the difficulty to predict the course of the bronchi and as a consequence – difficulties in performing the examination in a limited time. Therefore, CT virtual bronchoscopy as a non-invasive method that can precede bronchofiberoscopy providing the assessment of the respiratory tract anatomy at the same time, requires a very careful evaluation in terms of its clinical value, in order to become a stable part of diagnostic algorithm in pulmonary diseases.

Material and Methods

The retrospective study included 100 adult patients aged 18 to 65 years (mean age 40 years, median 40.5, standard deviation 14.02), 45 women and 55 men. All participants were performed a chest CT scan using spiral 16-slice CT scanners. In case of 65 participants the imaging results were taken from the database of the Diagnostic Radiology Department of Central Clinical Hospital of the Ministry of Interior in Warsaw. The remaining 35 were examined at the Department of Medical Radiology and Radiodiagnostics, Medical University of Silesia in Zabrze. CT examinations of subjects enrolled in the study were performed throughout following time periods: 10th September 2007 – 31th January 2008 and 1st May 2009 – 31th October 2009 in Warsaw and 15th October 2009 – 8th January 2010 in Zabrze. The study included the examination results of all participants meeting the inclusion and exclusion criteria from these two medical centers. The enrollment was performed by two independent radiologists experienced in chest radiology.

The chairman of the Bioethics Committee of the Medical University of Silesia in Katowice, issued an opinion, that applying for the permission of the Bioethics Committee to carry out this project is not required as it utilizes the data of examinations stored in databases and performed previously and independently of this study.

Inclusion criteria for the study group were as follows:

- good quality studies (no significant artifacts from motion nor metallic objects such as stents, surgical clips, catheters and others);
- examination performed on full inspiration;

Table 1. CT acquisition parameters.

Scanner	Toshiba Aquilion 16 CFX	GE Brightspeed Elite
Collimation [mm]	0.5	0.625
Reconstruction thickness [mm]	1.0	1.25
Pitch	1.438	1.375
Reconstruction increment [mm]	0.8	0.7
Voltage [kV]	120	120
Intensity [mA]	Auto	Auto
Detectors	16×0.5 mm	16×0.625 mm
Filters	Standard	Standard
Number of examinations	58	42

- normal appearance of chest organs, or minor abnormalities: small (up to 5mm), isolated nodules in the lungs, subtle adhesions, minor emphysematous changes.

Exclusion criteria were:

- chest deformations (e.g. spinal deformities, ribs deformations, posttraumatic changes);
- the presence of pathological changes affecting the anatomy of the bronchial tree, such as tumors, cardiac enlargement, hydrothorax, as well as any pathological thoracic lesions other than those specified in the inclusion criteria.

Patients enrolled in the study were referred to chest CT due to the following reasons:

- suspected pulmonary embolism;
- traffic injuries;
- oncological diseases originating outside the chest;
- non-specific changes in chest X-ray;
- clinical suspicion of the chest pathology.

CT protocol

Chest CTs were performed using 16-slice scanners Toshiba Aquilion 16 CFX (Warsaw) and GE Brightspeed Elite (Warsaw and Zabrze). Spiral protocol was used for image acquisition. Examination covered the area from few centimeters above the upper thoracic outlet to the level of the adrenal glands. Examinations obtained at full inspiration were evaluated. Detailed acquisition parameters are presented in Table 1.

All examinations were assessed using Vitrea[®] software at the Diagnostic Radiology Department of Central Clinical Hospital of the Ministry of Interior in Warsaw.

The assessment of bronchial division variants

Bronchial tree nomenclature and numbering system adopted in this study is presented in Table 2. It is derived from the Boyden's system and its subsequent modifications.

Table 2. The bronchi nomenclature used in this paper.

Main	Lobar	Segmental	Subsegmental
Right	Superior	B1, apical	a. apical b. anterior
		B2, posterior	a. apical b. posteriori
		B3, anterior	a. lateral b. anterior
	Middle	B4, lateral	a. lateral b. medial
		B5, medial	a. superior b. inferior
	Lower	B6, superior (apical)	a. medial b. superior c. lateral
		B7, medial basilar	a. anterior b. medial
		B8, anterior basilar	a. lateral b. basilar
		B9, lateral basilar	a. lateral b. basilar
		B10, posterior basilar	a. posterior b. lateral c. basilar
Left	Superior	B1+2, apicoposterior	B1a. apical B1b. anterior B2a. apical B2b. posterior
		B3, anterior	a. lateral b. medial c. superior
		B4, superior lingual	a. lateral b. anterior
		B5, inferior lingual	a. superior b. inferior
	Inferior	B6, superior (apical)	a. medial b. superior c. lateral
		B7, medial basilar	a. medial b. lateral
		B8, anterior basilar	a. lateral b. basilar
		B9, lateral basilar	a. lateral b. basilar
		B10, posterior basilar	a. lateral b. basilar

To evaluate the variants of bronchial subdivision a virtual bronchoscopy projection was used. If necessary multiplanar reformatted images were supportive. The starting point for respiratory tract analysis was the highest visualized point of

trachea. Subsequently the right main bronchus and the right upper lobar bronchus were investigated. Then the intermediate bronchus, right middle lobar bronchus and right lower lobar bronchus were viewed consecutively. Having analyzed the right side, bronchi of the left side were subjected to evaluation starting from main bronchus through upper and lower bronchi. The subdivision of bronchial tree was assessed down to the level of segmental bronchi. Each variant of subdivision was assigned to one of categories.

The following figures show specified variants of bronchial division at particular levels (Figures 1-7).

Comments on distinctive variants of bronchial subdivision

Right upper lobar bronchus. Besides the classical trifurcation, four possible types of bifurcation were distinguished. The variant of B1 arising directly from the trachea, called tracheal bronchus, was also taken into account. This type is classified, similarly to a cardiac bronchus, as a developmental anomaly rather than a anatomical variant.

Left upper lobar bronchus. At first a bifurcation giving off common branches to segments 1., 2., and 3. and segments. 4. and 5., was distinguished along with other possible variants, mostly trifurcation or rarely – bi- or tetrafurcation. In case of a main variant the type of subdivision of branches B1+2+3 was assessed.

Right middle lobar bronchus and lingula. In the presence of bifurcation the direction of division was assessed. If the direction of branching was nearly lateromedial (side-to-side), segments 4. and 5. were located laterally and medially, respectively. Whereas in case of vertical (superior-inferior) subdivision or anterior-posterior subdivision they were localized one above the other. Intermediate variant was also described in cases where the direction of the division was difficult to establish. The trifurcation and accessory bronchus arising from B4+5 trunk were collectively considered as one variant. Additionally on the left side, the absence of B4+5 trunk with segmental bronchi B4 and B5 arising directly from the upper lobar bronchus was classified as a separate variant.

Subsuperior bronchi. The accessory bronchi arising from lower lobar bronchus posteriorly and below the origin of B6 bronchus were recognized as subsuperior. If they originated from B7+8+9+10, B8+9+10 or B9+10 trunk, they were classified as separate variants. The presence of two subsuperior bronchi also formed an isolated type. A variant called suprasuperior bronchus (the presence of two bronchi to segment 6., with one arising above the origin of upper lobar bronchus) was spotted exclusively on the left side. Accessory bronchus arising laterally was classified as the accessory branch leading to segment 8., not as the subsuperior bronchus.

Lower lobar bronchi. Several types of bi- or trifurcation were classified. B7 arising directly from B7+8+9+10 trunk in right lung was omitted in the classification, whereas on the left side in each type the level of B7 origin was taken into consideration.

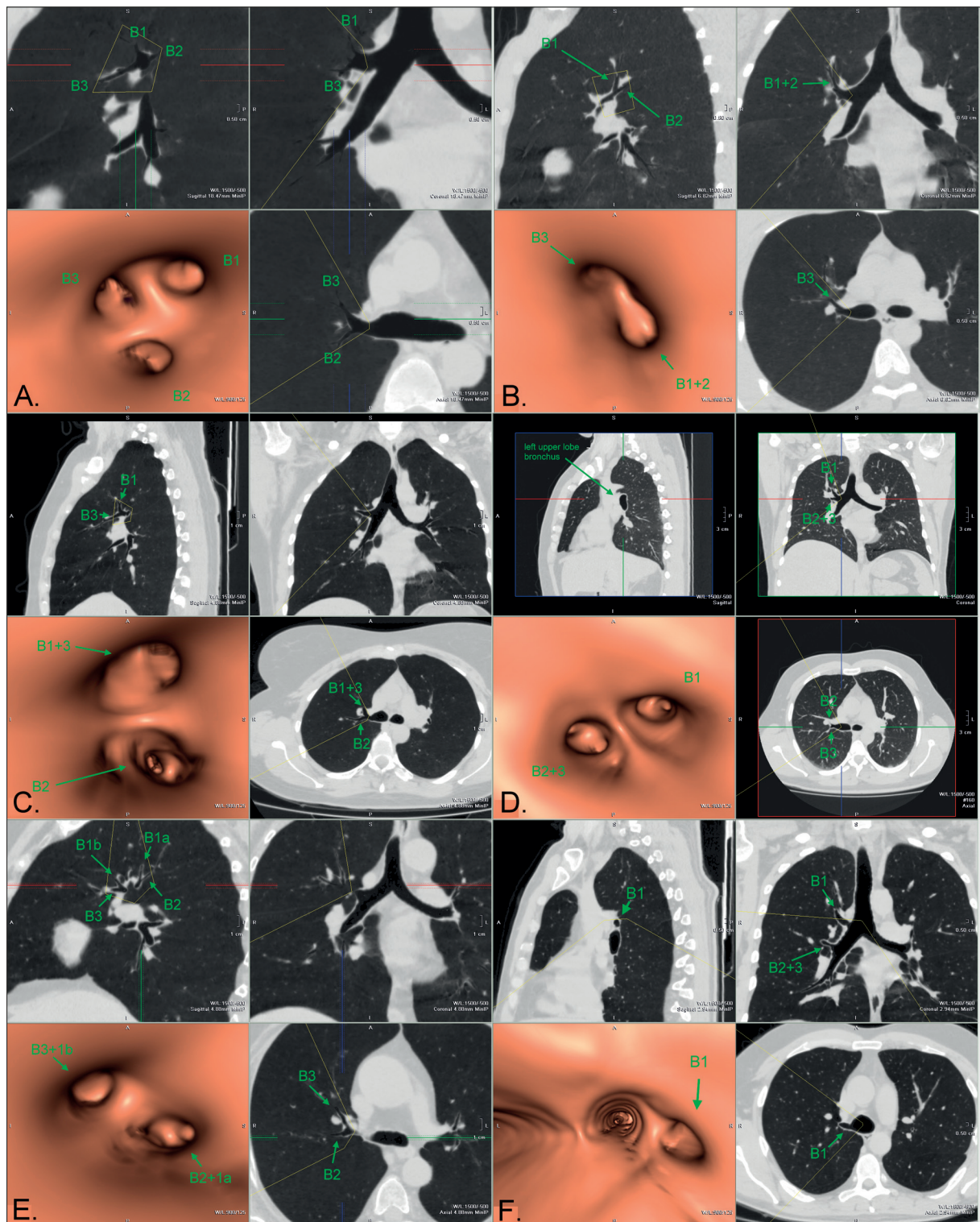


Figure 1. Right upper lobe bronchus division. B – bronchus (for instance: B1 means 1. segmental bronchus; B1a means 1a. subsegmental bronchus). B1+2 – means a common trunk which divides into 1. and 2. segmental bronchi. A. – B1, B2, B3 trifurcation; B. – B1+2, B3 bifurcation; C. – B1+3, B2 bifurcation; D. – B2+3, B1 bifurcation; E. – B2+1a, B3+1b bifurcation; F. – B1 arises from trachea, B2+3 from right main bronchus.

Statistical analysis

Statistical analyzes were performed using SPSS for Windows, version 17PL. As a first stage the prevalence of

particular variant was calculated as well as the percentage distribution of individuals regarding the number of division variants other than commonly seen.

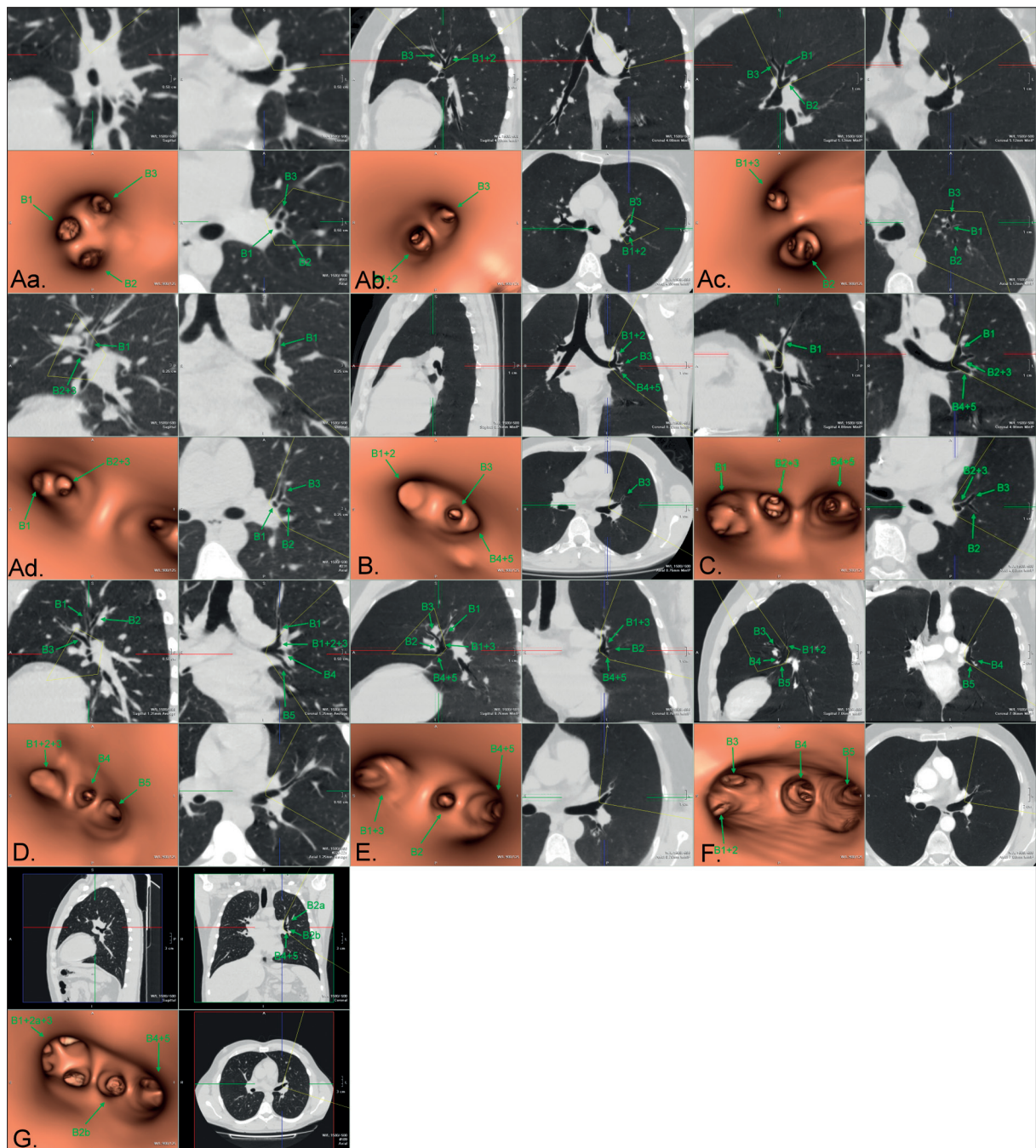


Figure 2. Left upper lobe bronchus division.

A. – apex, lingula bifurcation: a. – B1, B2, B3 trifurcation; b. – B1+2, B3 bifurcation; c. – B1+3, B2 bifurcation; d. – B1, B2+3 bifurcation; B. – B1+2, B3, B4+5 trifurcation; C. – B1, B2+3, B4+5 trifurcation; D. – B1+2+3, B4, B5 trifurcation; E. – B1+3, B2, B4+5 trifurcation; F. – B1+2, B3, B4, B5 quadrifurcation; G. – B1+2a+3, B2b, B4+5 trifurcation.

The second stage a coexistence of different subdivision types at different levels was examined. Due to a small number of patients in each single group, this analysis was performed on larger groups created by combining smaller groups. The aggregation scheme is presented in Table 3. At this stage 10 subjects in total were excluded. To check the statistical significance of the relationship between selected categories χ^2 test was performed.

Results

The prevalence of different variants of bronchial division at investigated levels are presented in Table 4.

Figure 8 shows the percentage distribution of the number of individuals with the same amount bronchial subdivision types other than typical variants at the investigated levels.

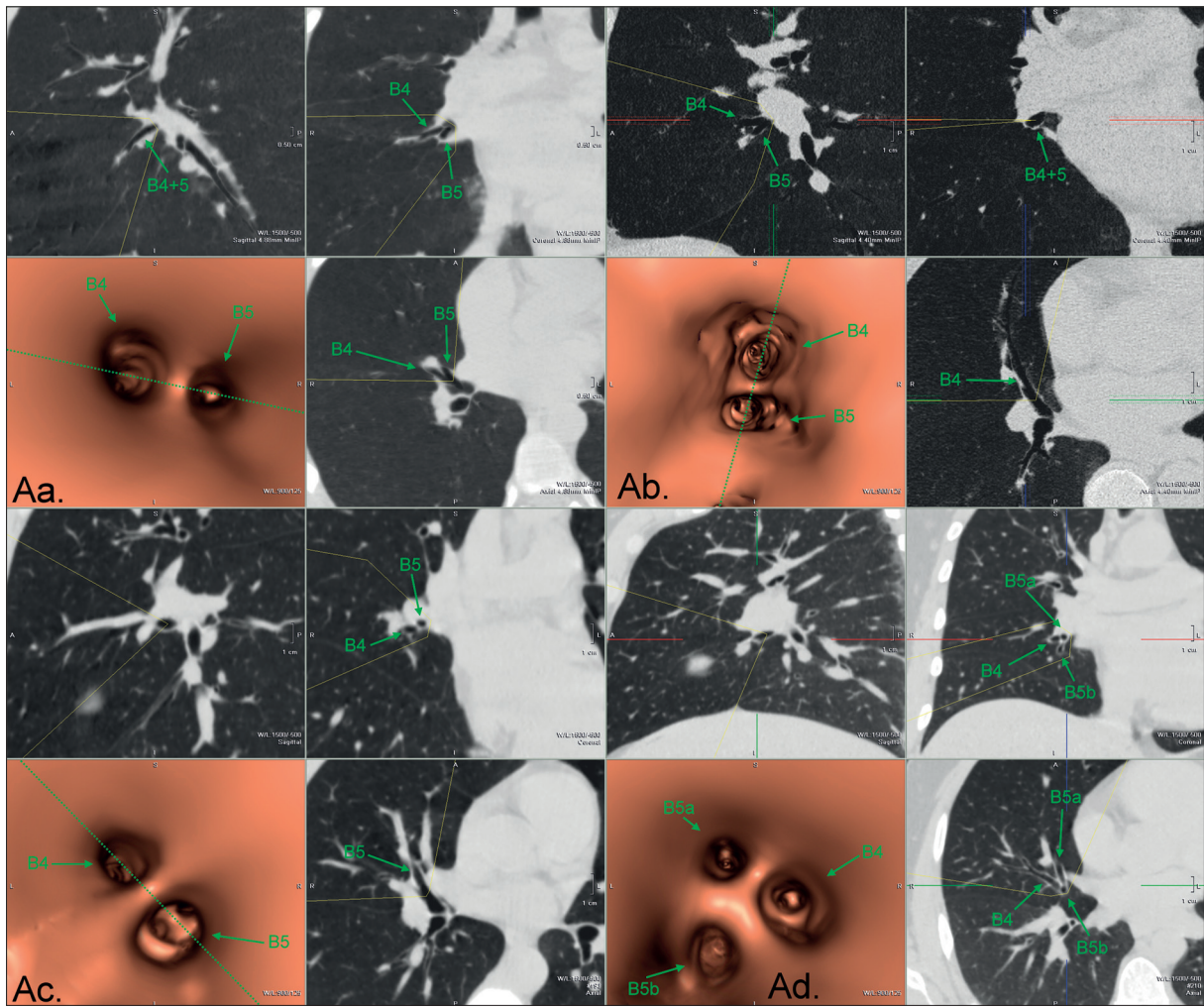


Figure 3. Right middle lobe bronchus division.

A. – B4+5 bifurcation; a. – in lateral direction; b. – in crano-caudal or antero-posterior direction; c. – in intermediate direction; B. – B4, B5a, B5b trifurcation.

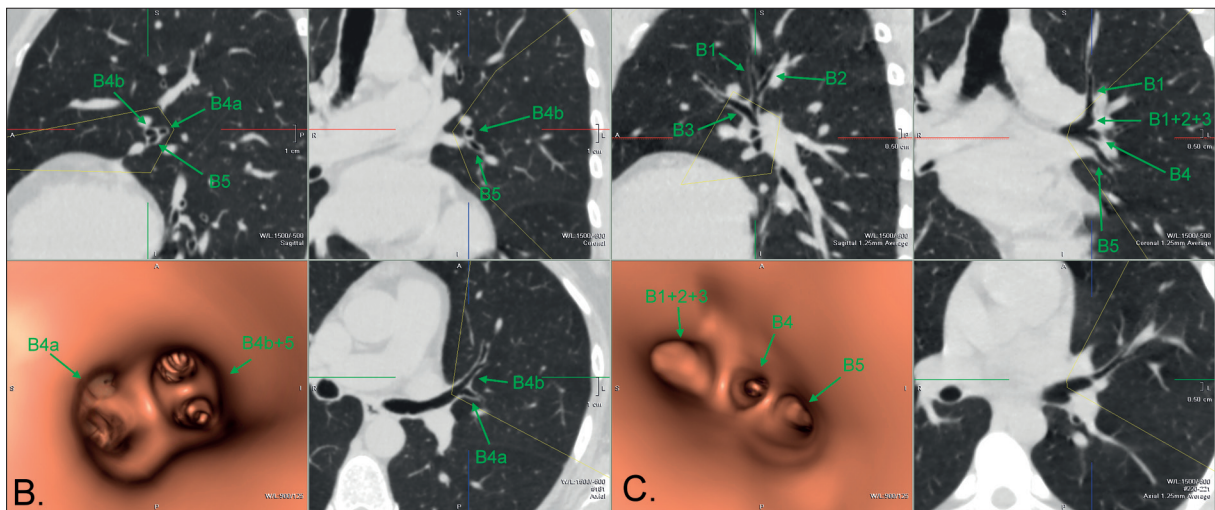


Figure 4. Lingual bronchi division.

A. – the same as in Figure 3; B. – accessory bronchus arising laterally from B4+5 or B4, B5, accessory bronchus trifurcation; C. – lacking B4+5 stem.

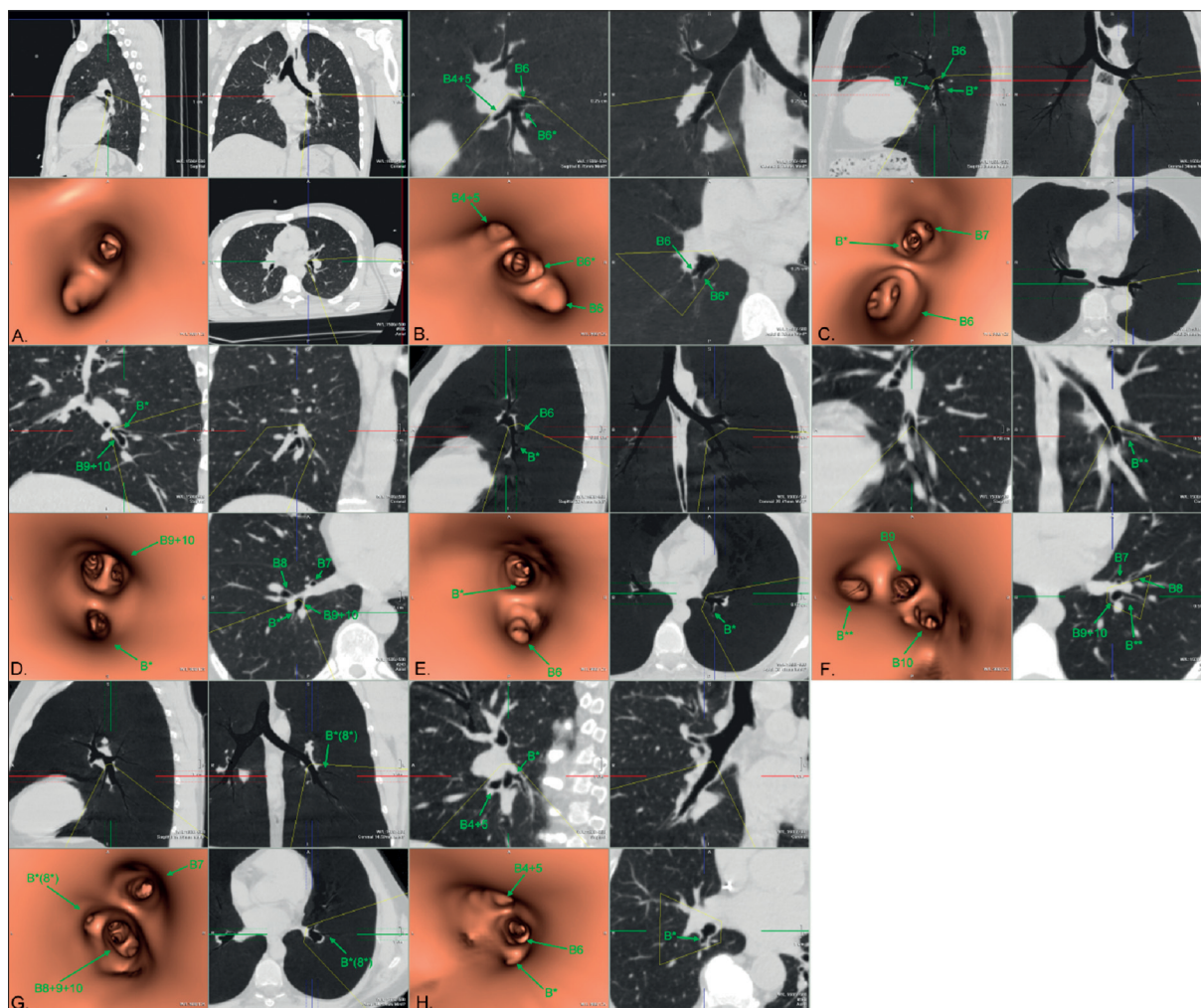


Figure 5. The presence of subsuperior bronchi, right and left sides.

A. – deficient; B. – one arising from B7+8+9+10 stem; C. – one arising from B8+9+10 stem; D. – one arising from B9+10 stem; E. – two; F. – one arising laterally (accessory B8); G. – oversuperior.

There was no correlation between types of bronchial division at all assessed levels. In some cases, it was impossible to examine the correlation power due to a small number of individuals in subgroups.

Discussion

The anatomical knowledge regarding bronchial tree and its variants is an important factor facilitating the diagnosis, examination and treatment of lung diseases, as well as conducting physiological tests of lung function. Clinical experience indicates a strong correlation between the effective therapy and diagnosis and anatomical knowledge and awareness of the bronchial tree structure varieties.

There is a scarcity of literature discussing the problem of the anatomical variability of the bronchial tree evaluated using either bronchofiberscopy [6,7], or CT scans [8-10]. Only one study assessed the bronchial division in left lung using CT virtual bronchoscopy [11].

Gonlugur et al. [6] retrospectively evaluated the types of bronchial subdivision basing on the analysis of

bronchofiberscopies. They found the occurrence of non-classical variants in only 2.6% of individuals. This result differs significantly from this study observations, as well as from the results of other studies evaluating the bronchial tree structure. Although the authors reviewed the descriptions of large amount of fiberscopies (over 2500), the results appear to be questionable. It rises from the fact that these examinations were not intended to evaluate the types of bronchial subdivision and therefore, any findings regarding anatomical variants were rather incidental than structured.

In another study [7], prospectively evaluating the types of bronchial subdivision using bronchofiberscopy, authors found a significantly higher prevalence of non-classical variants (they were present in a total of 42% of the individuals, and the most common, within the lower lobar bronchi bifurcations, were present in about 20% of subjects). However, the prevalence was still lower comparing to studies that used CT techniques (including this study), where Ghaye et al. [10] found a typical trifurcation of the right upper lobar bronchus in only 30% of patients. The disadvantage of almost all published data regarding the use

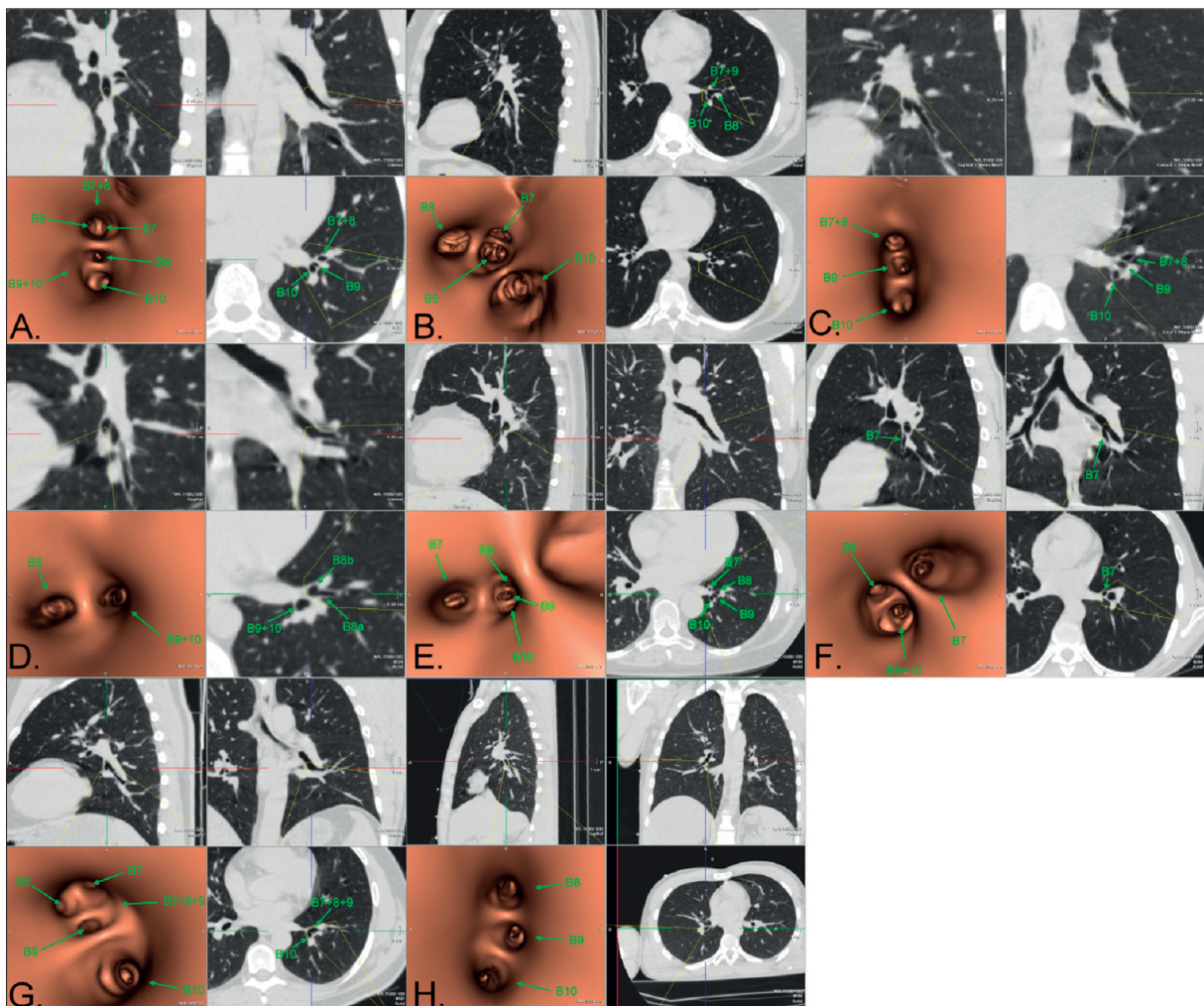


Figure 7. Left lower lobe bronchus division.

A. – B7+8, B9+10 bifurcation; B. – B7+8, B9, B10 trifurcation; C. – B8, B9+10 bifurcation (deficient B7); D. – B8, B9, B10 trifurcation, B7; E. – B8, B9+10 bifurcation, B7; F. – B7+8+9, B10 bifurcation; G. – B7, B8, B9+10 trifurcation; H. – B7+9, B8, B10 trifurcation.

the latter is that the second study used single slice scanner, which increases the duration of procedure and increases the probability of breathing motion artifacts making it difficult to identify minor bronchi.

A novel aspect of this study is a correlation among bronchial branching types at different levels. The statistical analysis revealed no such relationship, however in some cases the correlation could not be investigated due to a low number of particular branching types in subgroups. Based on these results it can be supposed that the branching of each lobar bronchus develops independently of other bronchial subdivisions. Accordingly, the occurrence of particular type of branching in one of the lobar bronchi does not increase or decrease the probability of different type of branching in another lobar bronchus.

Analyzing the number of individuals with branching types different from the most common variants, we found in all of these patients at least one uncommon type (out of 8 investigated categories). In most of these patients (32%) we found 3 different types of bronchial branching. Seven was the highest number of uncommon subdivisions and it was

identified in 1%. Such a large number of atypical subdivisions in the study group results mostly from high prevalence of such uncommon branching in upper lobar bronchi and the presence of subsuperior bronchi (approximately 40–50% each). The least frequent are uncommon variants within middle lobar and lingular bronchus (20–25% each), and their prevalence may be overestimated as the intermediate type of bifurcation was classified as uncommon (3Ac and 7Ac section Results). If this type of subdivision was categorized as one of the most common variants, the percentage of atypical divisions would be reduced by 9%, respectively.

Among the cited publications, only Beder et al. [7] analyzed the bronchial branching in this aspect. They found significantly lower (but still relatively large) number of individuals with uncommon variants, i.e. at least one uncommon subdivision in 47%, (single in 11%, two variants in 16%, three in 9%, and four or five in remaining group). The study by Ghaye et al. [10] performed no such analysis, nevertheless, the percentage of different types of branching was similar to the results of this study or even higher.

Table 3. Bronchi divisions types categories established for statistical analysis.

Right side	Left side
1. Upper lobar bronchus division A B+C+D+E The F category has been omitted	5. Upper lobar bronchus division Ab Aa+Ac+Ad B+C+D+E+F+G+H+I
2. Middle lobar bronchus division Aa Ab + Ac The B and C have been omitted	6. Lingual bronchus division Ab Aa+Ac B+C
3. The presence of subsuperior bronchus (B*) A B+C+D+E+F The G category has been omitted	7. The presence of subsuperior bronchus (B*) A B+C+D+F E The G category has been omitted
4. Lower lobar bronchus division A B C+E+F The D category has been omitted	8. Lower lobar bronchus division A B+C+D+G+I E+F+H

The high prevalence of different types of bronchial branching leads to the assumption that probably a typical subdivision of lobar bronchi can be found only in a small number of people. Taking into consideration the segmental bronchi subdivisions, that in this study were taken into account only in a few cases, and assuming that their variability may be even higher, stating that the fully typical branching of bronchial tree is rare seems to be justified.

The knowledge of the bronchial branching variants can be applied widely in clinical practice and scientific research. The most important aspects are discussed below.

Planning endoscopic biopsy of either the peripheral parts of the lungs [12] or the lymph nodes and other masses adjacent to the bronchi [13–15] is one of the important applications for VBCT potential regarding the assessment of bronchial branching. In addition, it is suggested by many authors that the virtual bronchoscopy viewed before bronchofiberscopy is not sufficient to guide the fiberscope to the proper location for sampling the lesion in the peripheral parts of the lungs. Therefore, a live navigation is used, that displays real-time virtual images moving along the bronchial tree simultaneously with fiberscope [16–18].

Knowing the types of bronchial tree branching may be also be helpful in airway stenting. In adult population, it is performed for two indications: an extrinsic mass effect or persisting bronchial stenosis after ablation of endobronchial lesion that occurs mostly in patients with inoperable bronchial carcinomas [19]. In pediatric population, the usual

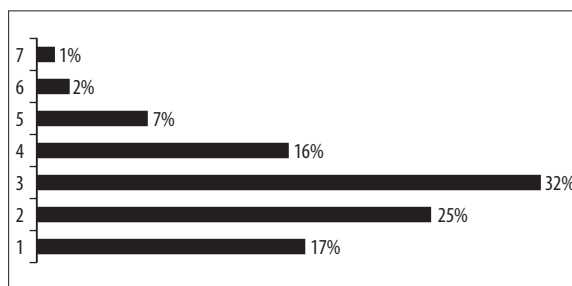


Figure 8. The percentage of people having the same number of variant bronchi divisions.

indications for airway stenting include stenoses caused by non-neoplastic diseases. The most common are: cardiovascular malformations, severe gastroesophageal reflux, esophageal atresia type III [20].

The virtual bronchoscopy used for planning bronchofiberscopy can be useful also to determine the position of a foreign body in the bronchial tree and to arrange its removal, which is most common in children [21,22].

In addition to the clinical use of virtual bronchoscopy to assess the bronchial tree anatomy, many authors also draw attention to its educational value [23–25], especially for pulmonologists and thoracic surgeons during bronchofiberscopy training. The bronchial tree is visualized by VBCT in a same mode. Hence, it provides an opportunity to become familiar with the specificity of endoscopic imaging and bronchial anatomy before performing the procedure unassisted. Colt et al. [26] examined the skills of 5 physicians taking part in bronchofiberscopy training. The authors evaluated the abilities of participants before and after implementing virtual bronchofiberscopy simulation. After simulation physicians could recognize more of segmental bronchi, and less frequently touched the bronchial wall with the tip of the endoscope, what usually evokes coughing. The duration of procedure remain the same. Generally, the beginners achieved effectiveness similar to the experienced operators.

The anatomical knowledge of bronchial tree plays an important role in studies regarding the aerosol distribution in the respiratory tract. The distribution of aerosol particles in the airways significantly depends on the anatomy [27], and the drugs administration can be modified according to the actual type of anatomical structure.

Aerosol distribution in the respiratory tract depends on many factors including, inter alia, the type of airways branching. Since the evaluation of distribution is not possible to perform *in vivo*, three-dimensional models of the bronchial tree are used to test the patterns of aerosol spreading via bronchial lumen [28–32]. Based on these studies, it was found that the deposition of aerosol particles in the respiratory tract is very non-uniform. There are significant differences between bronchi of the same generation (level of subdivision). For example, there is the 2.5 times greater deposition in the left lower lobar bronchus comparing to the corresponding bronchus on the right side, as the left bronchus is longer and characterized by a greater branching angle and curvature [31]. Branching angle also affects the amount of deposited particles. The larger is the

Table 4. The percentage of bronchi division variants.

Right side		Left side	
1. Right upper lobe bronchus division		5. Left upper lobe bronchus division	
A. B1, B2, B3 trifurcation	55	A. apex, lingula bifurcation	
B. B1+2, B3 bifurcation	13	a. B1, B2, B3 trifurcation	12
C. B1+3, B2 bifurcation	7	b. B1+2, B3 bifurcation	45
D. B2+3, B1 bifurcation	18	c. B1+3, B2 bifurcation	7
E. B2+1a, B3+1b bifurcation	6	d. B1, B2+3 bifurcation	13
F. B1 arises from trachea, B2+3 from right main bronchus	1	B. B1+2, B3, B4+5 trifurcation	13
		C. B1, B2+3, B4+5 trifurcation	3
		D. B1+2+3, B4, B5 trifurcation	3
		E. B1+3, B2, B4+5 trifurcation	1
		F. B1+2, B3, B4, B5 quadrifurcation	1
		G. B1+2a+3, B2b, B4+5 trifurcation	2
2. Middle lobe bronchus division		6. Lingula bronchi division	
A. B4+5 bifurcation		A. B4+5 bifurcation	
a. lateral	79	a. lateral	6
b. cranio-caudal or antero-posterior	9	b. cranio-caudal or antero-posterior	74
c. intermediate	8	c. intermediate	9
B. B4, B5a, B5b trifurcation	4	B. accessory bronchus arising laterally from B4+5 or B4, B5, accessory bronchus trifurcation	7
		C. lacking B4+5 stem	4
3. The presence of subsuperior bronchus (B*)		7. The presence of subsuperior bronchus (B*)	
A. absent	56	A. absent	63
B. one from B7+8+9+10 stem	22	B. one from B7+8+9+10 stem	16
C. one from B8+9+10 stem	11	C. one from B8+9+10 stem	3
D. one from B9+10 stem	7	D. one from B9+10 stem	9
E. two	1	E. two	5
F. one arising laterally (accessory B8)	2	F. one arising laterally (accessory B8)	3
G. oversuperior	1	G. oversuperior	1
4. Lower lobar bronchus division		8. Lower lobar bronchus division	
A. B8, B9, B10 trifurcation	7	A. B7+8, B9+10 bifurcation	71
B. B8, B9+10 bifurcation	72	B. B7+8, B9, B10 trifurcation	11
C. B8+9, B10 bifurcation	6	C. B8, B9+10 bifurcation (lacking B7)	3
D. B7+8, B9+10 bifurcation	3	D. B8, B9, B10 trifurcation; B7	5
E. B8+9a, B9b+10 bifurcation	7	E. B8, B9+10 bifurcation; B7	6
F. B7a, B7b; B8, B9+10 bifurcation	5	F. B7+8+9, B10 bifurcation	1
		G. B7, B8, B9+10 trifurcation	1
		H. B7+9, B8, B10 trifurcation	2

branching angle the greater is the deposition. For example, in the right lower apical bronchus the deposition of aerosol particles is more than 10 times greater comparing to other bronchi of the same generation.

Above-cited publications considered the assessment of aerosol deposition using specific and standardized model of bronchial tree. The results of our study demonstrate a considerable variability of bronchial tree, that should be taken into consideration in this type of studies. Some branching variants may favor an increase, while other – a decrease of aerosol deposition on bronchial walls. The configuration of bronchial branching may also affect the penetration

of particles to the alveoli in particular areas of the lungs. While some factors affecting the deposition of the particles in the respiratory tract have been identified, there are still some aspects remaining unknown, such as the effect of tri- or tetrafurcation instead of bifurcation or the presence of accessory bronchi.

Conclusions

CT virtual bronchoscopy is a quick and effective method to assess the bronchial branching down to the level of segmental bronchi, which is characterized by a great anatomical variability.

References:

- Heyer CM, Nuesslein TG, Jung D et al: Tracheobronchial anomalies and stenoses: detection with low-dose multidetector CT with virtual tracheobronchoscopy – comparison with flexible tracheobronchoscopy. *Radiology*, 2007; 242(2): 542–49
- De Wever W, Vandecaveye V, Lanciotti S et al: Multidetector CT-generated virtual bronchoscopy: an illustrated review of the potential clinical indications. *Eur Respir J*, 2004; 23: 776–82

3. Röttgen R, Schürmann D, Pinkernelle J et al: Detection of airways stenoses: comparison of virtual and flexible bronchoscopy. *Rofo*, 2005; 177(3): 338–43
4. Sraga W, Głowacki J, Myga-Porosilo J et al: Wartość Bronchoskopii Wirtualnej (BW) w diagnostyce patologii tchawicy i drzewa oskrzelowego na podstawie własnych przypadków klinicznych. *Pol Przegl Radiol*, 2007; 72(Suppl.1): 189–90 [in Polish]
5. Wojciechowski W, Urbanik A, De Wever W et al: Multislice computed tomography with virtual bronchoscopy in evaluation of airway pathology and grading of tracheobronchial stenosis. *Pol Przegl Radiol*, 2004; 69(Suppl.1): 233
6. Gonlugur U, Efeoglu T, Kaptanoglu M et al: Major anatomical variations of the tracheobronchial tree: bronchoscopic observation. *Anat Sci Int*, 2005; 80(2): 111–15
7. Beder S, Küpeli E, Karnak D et al: Tracheobronchial variations in Turkish population. *Clin Anat*, 2008; 21(6): 531–38
8. Naidich DP, Zinn WL, Ettenger NA et al: Basilar segmental bronchi: thin-section CT evaluation. *Radiology*, 1988; 169(1): 11–16
9. Lee KS, Bae WK, Lee BH et al: Bronchovascular anatomy of the upper lobes: evaluation with thin-section CT. *Radiology*, 1991; 181(3): 765–72
10. Ghaye B, Szapiro D, Fanchamps JM et al: Congenital bronchial abnormalities revisited. *Radiographics*, 2001; 21(1): 105–19
11. Zhao X, Ju Y, Liu C et al: Bronchial anatomy of left lung: a study of multi-detector row CT. *Surg Radiol Anat*, 2009; 31(2): 85–91
12. Shinagawa N, Yamazaki K, Onodera Y et al: CT-guided transbronchial biopsy using an ultrathin bronchoscope with virtual bronchoscopic navigation. *Chest*, 2004; 125(3): 1138–43
13. Weiner GM, Schulze K, Geiger B et al: CT bronchoscopic simulation for guiding transbronchial needle aspiration of extramural mediastinal and hilar lesions: initial clinical results. *Radiology*, 2009; 250(3): 923–31
14. McLennan G, Ferguson JS, Thomas K et al: The use of MDCT-based computer-aided pathway finding for mediastinal and perihilar lymph node biopsy: a randomized controlled prospective trial. *Respiration*, 2007; 74(4): 423–31
15. Wojciechowski W, Urbanik A, Duplaga M et al: Interactive application for transbronchial needle aspiration support. *Pol Przegl Radiol*, 2007; 72(Suppl.1): 51–52
16. Tachihara M, Ishida T, Kanazawa K et al: A virtual bronchoscopic navigation system under X-ray fluoroscopy for transbronchial diagnosis of small peripheral pulmonary lesions. *Lung Cancer*, 2007; 57(3): 322–27
17. Shinagawa N, Yamazaki K, Onodera Y et al: Virtual bronchoscopic navigation system shortens the examination time – feasibility study of virtual bronchoscopic navigation system. *Lung Cancer*, 2007; 56(2): 201–6
18. Higgins WE, Helferty JP, Lu K et al: 3D CT-video fusion for image-guided bronchoscopy. *Comput Med Imaging Graph*. 2008; 32(3): 159–73
19. Lund ME, Garland R, Ernst A: Airway stenting: Applications and practice management considerations. *Chest*, 2007; 131(2): 579–87
20. Antón-Pacheco JL, Cabezaí D, Tejedor R et al: The role of airway stenting in pediatric tracheobronchial obstruction. *Eur J Cardiothorac Surg*, 2008; 33(6): 1069–75
21. Kosucu P, Ahmetoglu A, Koramaz I et al: Low-dose MDCT and virtual bronchoscopy in pediatric patients with foreign body aspiration. *AJR*, 2004; 183: 1771–77
22. Adaletli I, Kurugoglu S, Ulus S et al: Utilization of low-dose multidetector CT and virtual bronchoscopy in children with suspected foreign body aspiration. *Pediatr Radiol*, 2007; 37(1): 33–40
23. De Wever W, Bogaert J, Verschakelen JA: Virtual bronchoscopy: accuracy and usefulness – an overview. *Semin Ultrasound CT MR*, 2005; 26: 364–73
24. Crawford SW, Colt HG: Virtual reality and written assessments are of potential value to determine knowledge and skill in flexible bronchoscopy. *Respiration*, 2004; 71(3): 269–75
25. Buthiau D, Antoine E, Piette JC et al: Virtual tracheo-bronchial endoscopy: educational and diagnostic value. *Surg Radiol Anat*, 1996; 18(2): 125–31
26. Colt HG, Crawford SW, Galbraith O: Virtual reality bronchoscopy simulation: a revolution in procedural training. *Chest*, 2001; 120(4): 1333–39
27. Cebra J, Summers RM: Tracheal and central bronchial aerodynamics using virtual bronchoscopy and computational fluid dynamics. *IEEE Trans Med Imaging*, 2004; 23(8): 1021–33
28. Martonen TB, Schroeter JD, Hwang D et al: Human lung morphology models for particle deposition studies. *Inhal Toxicol*, 2000; 12(Suppl.4): 109–21
29. Ferron GA, Edwards DA: Numerical simulation of air and particle transport in the human conduction airways. *J Aerosol Med*, 1996; 9: 303–16
30. Yeh HC, Schum GM: Models of the human lung airways and their application to inhaled particle deposition. *Bull Math Biol*, 1980; 42: 461–80
31. van Ertbruggen C, Hirsch C, Paiva M: Anatomically based three-dimensional model of airways to simulate flow and particle transport using computational fluid dynamics. *J Appl Physiol*, 2005; 98(3): 970–80
32. Farkas A, Balásházy I, Szocs K: Characterization of regional and local deposition of inhaled aerosol drugs in the respiratory system by computational fluid and particle dynamics methods. *J Aerosol Med*, 2006; 19(3): 329–43