

Cutaneous balamuthiasis: A clinicopathological study



Patricia Alvarez, MD,^a Carlos Torres-Cabala, MD,^b Eduardo Gotuzzo, MD,^{a,c} and Francisco Bravo, MD^{a,d}
Lima, Peru and Houston, Texas

Introduction: *Balamuthia mandrillaris*, a free-living amoeba, causes an uncommon infection that is characterized by cutaneous and neurological involvement, which carries a poor prognosis.

Methods: This is a retrospective observational study including patients with clinical suspicion of cutaneous balamuthiasis, their skin biopsies, and/or a positive direct immunofluorescence test. The data were collected from the Dermatology and Pathology service of the Hospital Cayetano Heredia and the Instituto Tropical Alexander von Humboldt, Lima, Peru, from January 1985 to June 2007. We identified 60 biopsies from 35 patients, from which clinical data were available in 30.

Results: Twenty-two (73%) patients had centofacial lesions, mostly located on the nose. The classical lesion was an asymptomatic, erythematous, or violaceous infiltrated plaque. Twenty-two (73%) patients had neurologic involvement. Fifty (83%) biopsies showed granulomatous dermatitis and 75% showed ill-defined tuberculoid granulomas without caseous necrosis. Multinucleated giant cells were observed in 52 (87%) biopsies. Trophozoite forms were identified in the biopsies of 25 (71%) patients. Direct immunofluorescence was positive in 25 (71%) patients.

Conclusion: *B. mandrillaris* is a pathogen that is capable of inducing a characteristic skin lesion with a reaction pattern of ill-defined tuberculoid granulomas and many giant cells. (JAAD Int 2022;6:51-8.)

Key words: *Balamuthia mandrillaris*; balamuthiasis; free-living amoebas; granulomatous amoebic encephalitis.

INTRODUCTION

Balamuthia mandrillaris, 1 of the 4 species of free-living amoeba that is pathogenic to humans, is associated with subacute granulomatous encephalitis, a nearly always fatal condition.¹⁻⁷

The onset of balamuthiasis is subtle, the course of the disease is insidious, its outcome is poor, and diagnosis is usually made at autopsy, which is when nervous system involvement is identified. The mortality rate of this disease is >98%, although in a single case reported from our institution, a therapeutic regimen including miltefosine resulted in the regression of central nervous system (CNS) and cutaneous involvement and survival of the patient up to 14 years.⁷ An early diagnosis can be made by the

histologic examination of clinically suspicious skin lesions, dramatically improving the prognosis of these patients. However, the diagnosis is rarely made on skin histology, mainly due to a lack of knowledge about the disease and the difficulty in identifying the amoeba on skin tissue.⁸⁻¹⁰

Skin involvement may appear and remain undiagnosed several weeks or months before the onset of neurologic manifestations.¹¹⁻¹³ Thus, an early histopathologic diagnosis followed by treatment may improve the ominous prognosis of the disease. Moreover, in a review of 30 Peruvian cases at our institution, all patients presented at a health care setting or reported a history of a cutaneous lesion, a finding that differs from other

From the Instituto de Medicina Tropical Alexander von Humboldt, Universidad Peruana Cayetano Heredia, Lima^a; Departments of Pathology and Dermatology, The University of Texas, MD Anderson Cancer Center, Houston^b; Departamento de Enfermedades Infecciosas, Tropicales y Dermatológicas, Hospital Nacional Cayetano Heredia, Lima,^c and Departamento de Patología, Hospital Cayetano Heredia, Lima.^d

Funding sources: None.

IRB approval status: Not applicable.

Accepted for publication November 23, 2021.

Correspondence to: Patricia Alvarez, MD, Patología cutánea, Av. Angamos Oeste 896, Miraflores Lima, Peru. E-mail: pacmed22@yahoo.com.

2666-3287

© 2021 Published by Elsevier Inc on behalf of the American Academy of Dermatology, Inc. This is an open access article under the CC BY-NC-ND license (<http://creativecommons.org/licenses/by-nc-nd/4.0/>).

<https://doi.org/10.1016/j.jdin.2021.11.005>

published series.^{14,15} Based on this, balamuthiasis should be included in the differential diagnosis of granulomatous diseases primarily of the facial area and else in both immunocompetent and immunocompromised patients.¹⁶⁻¹⁸

Herein, we describe a series of 35 cases of balamuthiasis and the histopathologic characteristics of the cutaneous infection by this free-living amoeba.

MATERIALS AND METHODS

We collected clinical and pathological data of patients with balamuthiasis who were seen at the Dermatology Service of the Hospital Cayetano Heredia and the Instituto de Medicina Tropical Alexander von Humboldt, Universidad Peruana Cayetano Heredia and whose biopsy specimens were evaluated at the Pathology Department of the Hospital Cayetano Heredia from January 1985 to June 2007. Our search criteria included the following: (1) clinical suspicion of free-living amoeba infection of the skin or (2) identification of the parasite in the skin biopsy by routine histology and/or a positive direct immunofluorescence test. We identified 60 skin biopsies from 35 patients, for whom clinical data were available in 30. Institutional review board approval was not required.

Clinical information such as age, sex, place of origin, clinical appearance and location of lesions, disease duration, exposure to stagnant water, coexistent medical conditions, and neurologic involvement were retrieved from patients' records.

All the skin specimens were fixed in 10% buffered formalin, processed, and embedded in paraffin; 4-mm sections were obtained and stained with hematoxylin-eosin. Special stains were performed in most cases and included Ziehl-Neelsen stain for acid-fast bacilli and periodic acid-Schiff for fungus as work-up for granulomatous infiltrates.

Skin biopsies were reviewed by 3 dermatopathologists and were analyzed for the following histopathologic features: the presence of epidermal, dermal, or subcutaneous fat involvement; the composition of the cellular infiltrate (lymphocytes, plasma cells, eosinophils, neutrophils, histiocytes, and multinucleated giant cells); the presence of well-formed or ill-defined tuberculoid granulomas, vasculitis, perineural inflammatory infiltrate; and the presence of the parasite. Direct immunofluorescence studies were performed at the Parasitology Branch of

the Center for Disease Control and Prevention, Atlanta, Georgia.

Statistical analysis was performed using Stata version 7.0 (StataCorp).

RESULTS

Clinical data were available for 30 of 35 patients with a suspected diagnosis of *B. mandrillaris* infection (Table I). The mean age was 21 years (range, 7-57 years). Fifteen (50%) patients were children (≤ 15 years). Twenty patients were men and 10 were women.

Sixteen patients were from cities located on the North coast of Peru (13 from Piura, 2 from Trujillo, 1 from Chimbote); 10 from the capital Lima, situated on the central Pacific coast, and 4 from Ica, 265-km south of Lima. Seventeen patients had a history of recent exposure to stagnant water.

Clinical features

The duration of the skin lesions at the time of diagnosis ranged from 2 months to 5 years (mean, 15 months). Twenty-two (73%) patients had centrofacial lesions, mostly located on the nose. Thirteen patients had extrafacial lesions. This group included lesions on the knees, thighs, lumbar zone, and abdomen (Fig 1, A and B). Most lesions were asymptomatic, erythematous, or violaceous infiltrated plaques. None of the patients complained of cutaneous pain or tenderness. In 2 cases, the lesions were ulcerated. Eight (27%) patients had multiple lesions. Twenty-two (73%) patients had CNS involvement, with a mortality rate of 91%. The most common neurologic manifestations were headache, altered state of consciousness, and focal neurologic deficits with meningeal signs. No additional clinical data were available.

Histopathologic features

Sixty biopsies from 35 patients were evaluated in this study. The histopathologic characteristics of these biopsies are summarized in Table II.

Most biopsies showed granulomatous dermatitis (50 biopsies, 83%). Psoriasiform hyperplasia was present in 16 (27%) biopsies. Findings were restricted to the dermis in 58 (97%) biopsies, whereas in 17 (28%) biopsies, the subcutaneous fat was also involved. The granulomas were predominantly tuberculoid without caseous necrosis; 45 (75%) cases

CAPSULE SUMMARY

- The present report describes the cutaneous histological findings of *Balamuthia mandrillaris* infection, along with a precise clinicopathological correlation.
- This may allow physicians to lead to an early diagnosis and successful therapy for an otherwise fatal disease.

Abbreviations used:

CNS: central nervous system
FLA: free-living amoeba

showed loose and ill-defined granulomas (Fig 2, A and B), whereas only 5 (8%) cases had well-formed, compact epithelioid cell granulomas. Ten biopsies had a lymphoplasmacytic infiltrate without any evidence of granulomas, and only scattered giant cells were present. Fourteen patients did require >2 biopsies for identification of the microorganism on histology.

The accompanying inflammatory infiltrate was predominantly lymphocytic, admixed with other cells, such as plasma cells (88%), eosinophils (67%), and neutrophils (48%). Multinucleated giant cells (Langhans type) were observed in 52 (87%) biopsies, both inside and outside the granulomas (Fig 3). Perineural inflammatory infiltrate was observed in 10 (17%) biopsies. Vasculitis was seen in 5 (8%) biopsies.

The trophozoite forms of the amoeba, some of them seen within a lacunar space, were identified in biopsies of 25 of 35 (71%) patients. They showed round or irregular morphology (Figs 3 and 4). No cyst forms were detected. Direct immunofluorescence tests for *B. mandrillaris* were performed in 25 (71%) patients, all of them confirming the diagnosis.

DISCUSSION

Four decades ago, the term amoebiasis was restricted to *Entamoeba histolytica* infection. Since then, free-living amoebas (FLAs) have emerged as important pathogens.^{1,2,4} Among the many FLAs that are found in the environment, 4 genera of FLAs have been associated with human disease. These include 1 species of *Naegleria* (*N. fowleri*); 1 species of *Balamuthia* (*B. mandrillaris*); several species of *Acanthamoeba* causing eye, skin, spinal cord, and CNS infections; and *Sappinia pedata* (previously identified as *Sappinia diploidea*), for which a single case of amoebic encephalitis has been described.^{10,19,20}

Following the new classification of the eukaryotes by Visvesvara²¹ into 6 clusters or “supergroups” (Amoebozoa, Opisthokonta, Rhizaria, Archaeplastida, Chromalveolata, and Excavata), *Acanthamoeba* and *Balamuthia* are included under supergroup Amoebozoa: Acanthamoebidae; *Naegleria fowleri* under supergroup Excavata: Heterolobosia: Vahlkampfiidae, and *Sappinia* under supergroup Amoebozoa: Flabellinea: Thecamoebidae. From all

Table I. Clinical characteristics of cutaneous balamuthiasis

1. Age, years	
≤15	15 (50%)
>15	15 (50%)
2. Sex	
Male	20 (67%)
Female	10 (33%)
3. Place of origin	
Piura	13 (43%)
Lima	10 (33%)
Ica	4 (13%)
Trujillo	2 (7%)
Chimbote	1 (4%)
4. Mean time of cutaneous lesion (months)	15
5. No. of lesions	
Single	22 (73%)
Multiple	8 (27%)
6. Location of the lesions	
Centrofacial	22 (73%)
Lower limb	8 (27%)
Back (dorsolumbar)	4 (13%)
Abdomen	1 (3%)
7. Exposure to stagnant water	17 (57%)
8. Neurologic involvement	22 (73%)
9. Mortality rate	
Only skin involvement	0 (0%)
Skin and central nervous system involvement	20 (91%)

these, only *Acanthamoeba* and *B. mandrillaris* cause cutaneous lesions.

B. mandrillaris was first identified in 1986 in the brain of a pregnant mandrill baboon that died of encephalitis in the San Diego Zoo. The organism was initially classified as leptomyxid amoeba, and in an early publication of human cases, 2 of the 16 patients were from Peru.¹ Subsequent microscopic studies showed that the parasite was morphologically and antigenically different from other amoebas of the order Leptomyxida; thus, a new species-genus and family were established to include this microorganism, which was later renamed in the honor of the 20th century protozoologist, Dr William Balamuth.^{1-3,22}

Epidemiologically, *B. mandrillaris* infection is reported mainly in the Americas, with few cases reported in other countries such as Japan, Thailand, Australia, Czech Republic, Portugal, and China.^{6,23-31}

To date, approximately 200 cases of granulomatous meningitis by *B. mandrillaris* have been reported. This may underestimate the real incidence of the disease, considering the lack of pathognomonic findings, the difficulty in recognizing amoebas in

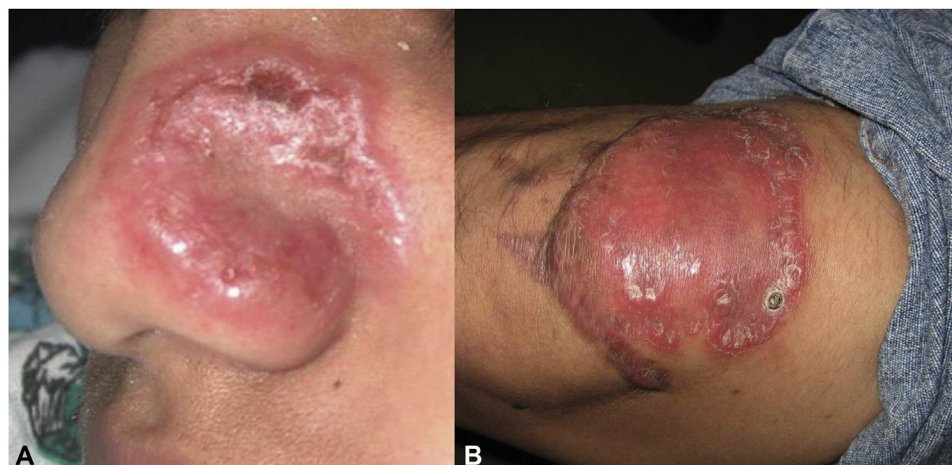


Fig 1. Cutaneous balamuthiasis. **A**, The classical clinical appearance is a painless plaque on the central face, especially on the nose. **B**, The knee is the second most common location.

Table II. Histopathologic features of cutaneous balamuthiasis

1. No. of biopsies	60 (100%)
2. Skin layer involvement	
Psoriasiform hyperplasia	16 (27%)
Dermal involvement	58 (97%)
Subcutaneous adipose tissue involvement	17 (28%)
3. Type of pattern	
a. Granulomatous pattern	50 (83%)
Ill-defined tuberculoid granulomas	45 (75%)
Well-defined tuberculoid granulomas	5 (8%)
b. Lymphoplasmocytic infiltrate	10 (17%)
4. Type of cell	
Lymphocytes	60 (100%)
Plasma cells	53 (88%)
Eosinophils	40 (67%)
Neutrophils	29 (48%)
Multinucleated giant cells	52 (87%)
5. Vasculitis	5 (8%)
6. Perineural infiltrate	10 (17%)
7. Amoeba identified in tissue (in 35 patients)	25 (71%)

skin biopsy tissues, and the fact that the initial cases were regarded as *Acanthamoeba* sp.^{16,23,32}

The most recent collection of cases of infection by *B. mandrillaris* from the United States include 109 cases, with 99% seen with a clinical picture of encephalitis.³³ A high proportion of these cases are Hispanic Americans from the southern and southwest states who are more likely to reside in rural settings and therefore may have exposure to soil and a higher chance of contamination of cuts and other injuries.³³⁻³⁵

Peru has a high prevalence, and 55 cases have been reported from 1975 to 2012, including some of

our cases. In addition, cases have been reported in Chile, Argentina, Venezuela, Brazil, and Bolivia during the last 15 years.^{23,25,36-38} This epidemiologic distribution suggests that certain environmental and genetic factors are associated with the development of the disease.^{11,14,15}

Half of the patients in our series were children, an age group that appears to be more susceptible to the infection, in agreement with previous observations from other series.^{14,15,24,39}

Our patients came from valleys on the desertic Pacific coast of Peru. This suggests that environmental factors like the ocean-atmosphere system (including the El Niño phenomenon and UV-B radiation) may play a role in this infection.⁴⁰ No seasonal variations have been recorded in the epidemiology of *B. mandrillaris* infection.^{15,18,29}

More than half of our patients had a contact history with stagnant water. Although *B. mandrillaris* has never been isolated from water, some studies suggest that exposure to stagnant water may be associated with the disease. The most likely source of infection is soil and dust. *B. mandrillaris* has been isolated from the soil and dust in the United States, Mexico, Iran, Costa Rica, and Jamaica and from the soil in Piura and Lima, Peru.⁴¹⁻⁴⁵ A serologic survey of landscapers and blood donors in southern Arizona concluded that exposure to *B. mandrillaris* (3%) appears to be more common than granulomatous amebic encephalitis.⁴⁶

The route of infection appears to be the respiratory mucosa and skin trauma, a history of which was recorded in 3 of our patients.^{12,18,47} Solid organ transplantation appears to be a concerning and emerging way of transmission.^{48,49}

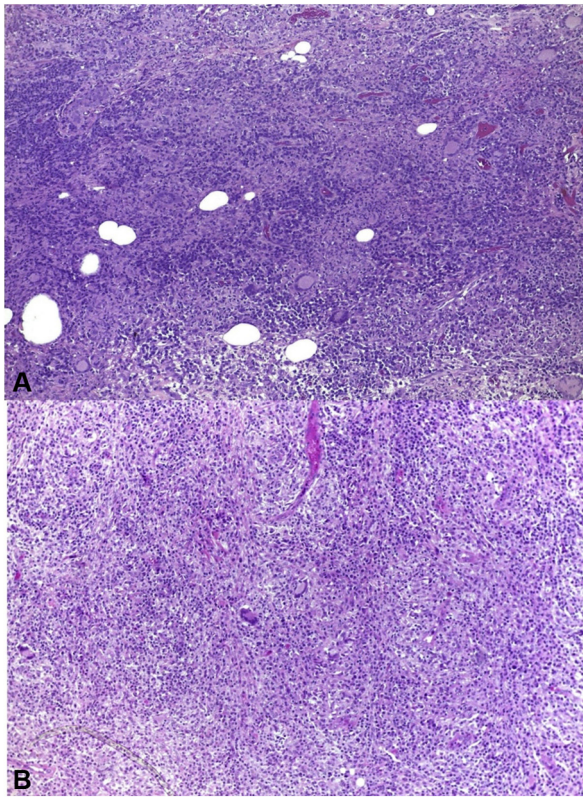


Fig 2. Cutaneous balamuthiasis. **A** and **B**, Histopathologic examination shows a superficial and deep granulomatous infiltrate composed of ill-defined tuberculoid granulomas. Numerous multinucleated giant cells are present within the granulomas and in the interstitial space (**A** and **B**, Hematoxylin-eosin stain; original magnifications: **A**, $\times 40$; **B**, $\times 40$.)

None of our patients were immune deficient due to chronic illness, alcoholism, corticosteroid therapy, HIV, or other diseases, in contrast to those affected by *Acanthamoeba* spp., where immunosuppression is the rule.

A distinct finding in our series is the presence of a cutaneous lesion preceding the CNS involvement in almost all patients. This finding contrasts to what is seen in the United States, where cutaneous lesions were recognized in only 5% of the cases.³³ A recent series of 28 patients from China also demonstrated a high prevalence of cutaneous involvement (100%), and 57% of such cases developed encephalitis.⁶ Genetic factors may account for the observed high occurrence of skin involvement in the Peruvian and Chinese patients in contrast to the scarcity of skin lesions reported in the North American cases. Subtle differences in the mechanisms of innate immunity should be investigated to study the role of macrophages at the early phases of the infection.

Cutaneous lesions in our patients were most commonly located in the centropacial area over the

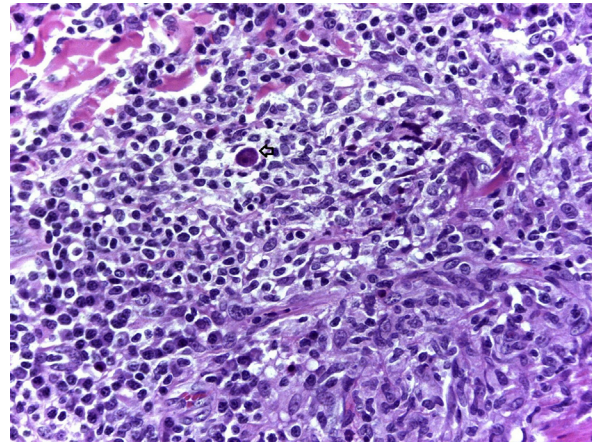


Fig 3. Cutaneous balamuthiasis. Granulomatous infiltration with multinucleated giant cells and a *Balamuthia mandrillaris* trophozoite (Hematoxylin-eosin stain; original magnification: $\times 400$.)

nose, followed by the lower limbs, in agreement with previous reports.^{11,16,50,51} Lesions were usually asymptomatic, solitary erythematous to purplish infiltrated plaques with irregular borders and occasional satellites; when multiple, they were fewer than 4. Ulcers were not common.

In some cases, the skin lesion was detected several months or years before the CNS involvement, as in one of our patients, a 21-year-old woman with a history of cutaneous lesions on her right knee for almost 5 years. In other patients, cutaneous lesions and CNS involvement were identified at the same time.

Along with *Acanthamoeba* spp, *B. mandrillaris* is the only FLA that has been reported to elicit cutaneous lesions. In contrast to *Acanthamoeba* skin infections, which commonly present with ulcers and abscesses and histopathologically only rarely show suppurative or necrotizing granulomas with a few multinucleated giant cells (findings that have been attributed to longstanding immunosuppression and inability to mount a granulomatous reaction around the amoebas), our cases of *B. mandrillaris* infection commonly display a granulomatous pattern on histopathology.⁵¹⁻⁵³

The most common histopathologic pattern seen in our series was that of ill-defined tuberculoid granulomas with multinucleated giant cells inside and outside the granulomas, associated with a diffuse superficial and deep inflammatory infiltrate composed of lymphocytes, plasma cells, and histiocytes. Neutrophils and eosinophils were rarely present. A novel finding was the presence of perineural inflammation, which was observed in 67% of our biopsies. This suggests that the route of spread from

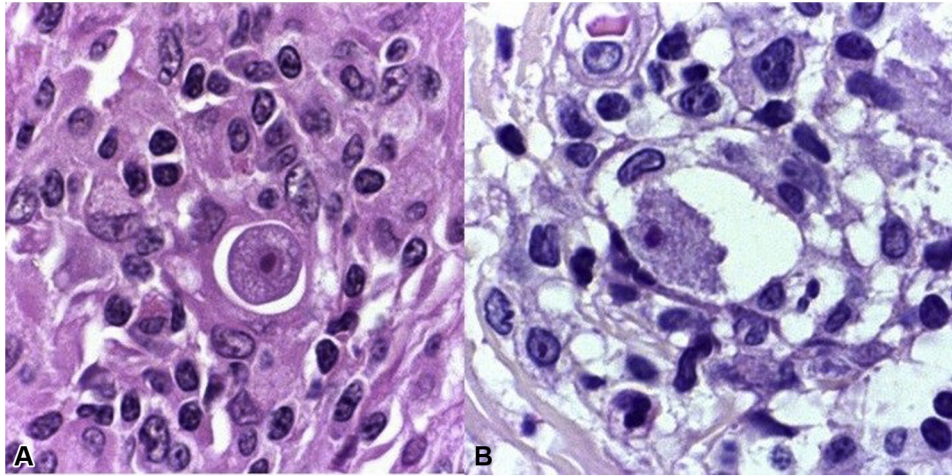


Fig 4. Cutaneous balamuthiasis. **A**, *Balamuthia mandrillaris* trophozoite displays the typical oval shape; small, round nucleus with a large nucleolus; and bubbly cytoplasm. An artifactual retraction around the organism gives the appearance of a lacunar space. **B**, The trophozoites may adopt a more irregular shape and mimic the histiocytes (**A** and **B**, Hematoxylin-eosin stain; original magnifications: **A**, $\times 1000$; **B**, $\times 1000$.)

the skin to the nervous system may be ascending along with the adventitial layer of perineural vessels.

We identified trophozoites in 71% of our biopsies, a rate comparable with that of previous studies.^{16,51,53} They can be seen on routine hematoxylin-eosin-staining and are characterized by a spherical nucleus with a large nucleolus and a dense round or irregular cytoplasm containing empty vacuoles, giving a “bubbly” appearance.^{1,23,54} In some cases, the nucleus could have >1 nucleolus and may show a clear cut central space in the nucleoli of the amoebas that was called “nucleolar perforation,” a feature that could distinguish *B. mandrillaris* from *Acanthamoeba*.¹⁴

In our experience, *B. mandrillaris* trophozoites are difficult to visualize because of their scarcity and histiocyte-like appearance. Sometimes a retraction artifact around the trophozoites was present, giving a lacunar appearance to the organism. Stains such as periodic acid-Schiff or Ziehl-Nielsen did not result in better identification of trophozoites. In contrast to brain lesions of *B. mandrillaris*, the cutaneous lesions lacked thrombosis, hemorrhage, necrosis, and the cyst stage.^{14,24,27,54} Occasional cyst forms have been reported in the skin.^{6,55}

The clinical and histopathologic differential diagnosis of cutaneous balamuthiasis includes leishmaniasis, sporotrichosis, lupus vulgaris, sarcoidosis, Wegener granulomatosis, necrobiosis lipoidica, and natural killer and T-cell lymphomas.

Ancillary tests such as immunofluorescence, molecular biology techniques, and serology are useful to confirm the infection but are not available in most clinical settings. Thus, routine histopathologic

examination remains the most important way to diagnose cutaneous balamuthiasis, with a dramatic impact on the therapy and prognosis of these patients.

CONCLUSION

Cutaneous balamuthiasis is rare and has a high fatality rate when complicated by CNS involvement. In our experience, the best method for early diagnosis is the integration of clinical and histopathologic findings of skin lesions. In view of that, most of our patients had cutaneous lesions before CNS dissemination. Awareness of the histopathologic findings of *B. mandrillaris* cutaneous infection, ill-defined granulomas with many multinucleated giant cells and without necrosis, will help dermatopathologists reach the correct diagnosis. With the discovery of the therapeutic effects of new antiparasitic drugs such as miltefosine in treating *Balamuthia* infections, early diagnosis with subsequent and prompt therapeutic intervention may radically change the prognosis of this otherwise fatal infection.⁷

The authors are grateful to Dr Govinda Visvesvara and the Centers for Disease Control and Prevention, Atlanta, Georgia, for amoeba identification and their continuous support in the care of our patients.

Conflicts of interest

None disclosed.

REFERENCES

1. Visvesvara GS, Martinez AJ, Schuster FL, et al. Leptomyxid amoeba, a new agent of amoebic meningoencephalitis in humans and animals. *J Clin Microbiol*. 1990;28(12):2750-2756.

2. Chimelli L, Hahn MD, Scaravilli F, et al. Granulomatous amoebic encephalitis due to leptomyxid amoebae: report of the first Brazilian case. *Trans R Soc Trop Med Hyg.* 1992;86(6): 635.
3. Visvesvara GS, Schuster FL, Martinez AJ. Balamuthia mandrillaris, N. G., N. Sp., agent of amebic meningoencephalitis in humans and other animals. *J Eukaryot Microbiol.* 1993;40(4): 504-514.
4. Schuster FL, Visvesvara GS. Free-living amoebae as opportunistic and non-opportunistic pathogens of humans and animals. *Int J Parasitol.* 2004;34(9):1001-1027.
5. Doyle JS, Campbell E, Fuller A, et al. Balamuthia mandrillaris brain abscess successfully treated with complete surgical excision and prolonged combination antimicrobial therapy. *J Neurosurg.* 2011;114(2):458-462.
6. Wang L, Cheng W, Li B, et al. Balamuthia mandrillaris infection in China: a retrospective report of 28 cases. *Emerg Microbes Infect.* 2020;9(1):2348-2357.
7. Martínez DY, Seas C, Bravo F, et al. Successful treatment of Balamuthia mandrillaris amoebic infection with extensive neurological and cutaneous involvement. *Clin Infect Dis.* 2010;51(2):e7-e11.
8. Martínez AJ, Visvesvara GS. Free-living, amphizoic and opportunistic amebas. *Brain Pathol.* 1997;7(1):583-598.
9. Martínez AJ, Schuster FL, Visvesvara GS. Balamuthia mandrillaris: its pathogenic potential. *J Eukaryot Microbiol.* 2001;suppl: 6S-9S.
10. White JM, Barker RD, Salisbury JR, et al. Granulomatous amoebic encephalitis. *Lancet.* 2004;364(9429):220.
11. Bravo F, Sánchez MR. New and re-emerging cutaneous infectious diseases in Latin America and other geographic areas. *Dermatol Clin.* 2003;21(4):655-668, viii.
12. Chang OH, Liu F, Knopp E, et al. Centrofacial Balamuthiasis: case report of a rare cutaneous amebic infection. *J Cutan Pathol.* 2016;43(10):892-897.
13. Galarza M, Larrea C, Kumakawa H. Amebiasis cutanea de vida libre. Primer caso reportado en el Hospital Nacional Dos de Mayo, Lima-Perú. *Dermatol Peru.* 1997;7(1):65-69.
14. Recavarren-Arce S, Velarde C, Gotuzzo E, et al. Amoeba angeitic lesions of the central nervous system in Balamuthia mandrillaris amoebiasis. *Hum Pathol.* 1999;30(3):269-273.
15. Campos P, Cabrera J, Gotuzzo E, et al. Neurological involvement in free living amebiasis. Article in Spanish. *Rev Neurol.* 1999;29(4):316-318.
16. Pritzker AS, Kim BK, Agrawal D, et al. Fatal granulomatous amebic encephalitis caused by Balamuthia mandrillaris presenting as a skin lesion. *J Am Acad Dermatol.* 2004;50(2 suppl): S38-S41.
17. Bravo FG, Alvarez PJ, Gotuzzo E. Balamuthia mandrillaris infection of the skin and central nervous system: an emerging disease of concern to many specialties in medicine. *Curr Opin Infect Dis.* 2011;24(2):112-117.
18. Seas RC, Bravo PF. Amebic granulomatous encephalitis due to Balamuthia mandrillaris: fatal disease increasingly recognized in Latin America. Article in Spanish. *Rev Chilena Infectol.* 2006; 23(3):197-199.
19. Schuster FL. Cultivation of pathogenic and opportunistic free-living amebas. *Clin Microbiol Rev.* 2002;15(3):342-354.
20. Qvarnstrom Y, da Silva AJ, Schuster FL, et al. Molecular confirmation of *Sappinia pedata* as a causative agent of amoebic encephalitis. *J Infect Dis.* 2009;199(8):1139-1142.
21. Visvesvara GS. Infections with free-living amebae. *Handb Clin Neurol.* 2013;114:153-168.
22. Henry R. Etymologia: Balamuthia mandrillaris. *Emerg Infect Dis.* 2015;21(5):898.
23. Cuevas PM, Smoje PG, Jofré ML, et al. Meningoencefalitis granulomatosa por Balamuthia mandrillaris: reporte de un caso y revisión de la literatura. *Rev Chilena Infectol.* 2006;23(3): 234-239.
24. Bakardjiev A, Azimi PH, Ashouri N, et al. Amebic encephalitis caused by Balamuthia mandrillaris: report of four cases. *Pediatr Infect Dis J.* 2003;22(5):447-453.
25. Tarauto AL, Monges J, Acefe JC, et al. Leptomyxid amoeba encephalitis: report of the first case in Argentina. *Trans R Soc Trop Med Hyg.* 1991;85(1):77.
26. Riestra-Castañeda JM, Riestra-Castañeda R, González-Garrido AA, et al. Granulomatous amebic encephalitis due to Balamuthia mandrillaris (Leptomyxiidae): report of four cases from Mexico. *Am J Trop Med Hyg.* 1997;56(6):603-607.
27. Itoh K, Yagita K, Nozaki T, et al. An autopsy case of Balamuthia mandrillaris amoebic encephalitis, a rare emerging infectious disease, with a brief review of the cases reported in Japan. *Neuropathology.* 2015;35(1):64-69.
28. Krasaelap A, Prechawit S, Chansaenroj J, et al. Fatal Balamuthia amebic encephalitis in a healthy child: a case report with review of survival cases. *Korean J Parasitol.* 2013;51(3):335-341.
29. Moriarty P, Burke C, McCrossin D, et al. Balamuthia mandrillaris encephalitis: survival of a child with severe meningoencephalitis and review of the literature. *J Pediatric Infect Dis Soc.* 2014;3(1):e4-e9.
30. Kodet R, Nohýnková E, Tichý M, et al. Amebic encephalitis caused by Balamuthia mandrillaris in a Czech child: description of the first case from Europe. *Pathol Res Pract.* 1998;194(6):423-429.
31. Tavares M, Correia da Costa JM, Carpenter SS, et al. Diagnosis of first case of Balamuthia amoebic encephalitis in Portugal by immunofluorescence and PCR. *J Clin Microbiol.* 2006;44(7): 2660-2663.
32. Centers for Disease Control and Prevention (CDC). Balamuthia amebic encephalitis—California, 1999-2007. *MMWR Morb Mortal Wkly Rep.* 2008;57(28):768-771.
33. Cope JR, Landa J, Nethercut H, et al. The epidemiology and clinical features of Balamuthia mandrillaris disease in the United States, 1974-2016. *Clin Infect Dis.* 2019;68(11):1815-1822.
34. Schuster FL, Glaser C, Honarmand S, et al. Balamuthia amebic encephalitis risk, Hispanic Americans. *Emerg Infect Dis.* 2004; 10(8):1510-1512.
35. Díaz JH. The public health threat from Balamuthia mandrillaris in the southern United States. *J La State Med Soc.* 2011;163(4): 197-204.
36. Martínez AJ, Guerra AE, García-Tamayo J, et al. Granulomatous amebic encephalitis: a review and report of a spontaneous case from Venezuela. *Acta Neuropathol.* 1994;87(4):430-434.
37. Silva-Vergara ML, Da Cunha Colombo ER, De Figueiredo Vissotto E, et al. Disseminated Balamuthia mandrillaris amoeba infection in an AIDS patient from Brazil. *Am J Trop Med Hyg.* 2007;77(6):1096-1098.
38. Bodi I, Dutt N, Hampton T, et al. Fatal granulomatous amoebic meningoencephalitis due to Balamuthia mandrillaris. *Pathol Res Pract.* 2008;204(12):925-928.
39. Ballona R, Aquije M. Compromiso cutáneo en encefalitis granulomatosa amebiana fatal causada por Balamuthia mandrillaris. *Folia Dermatol.* 2003;14:28-30.
40. Cabello-Vilchez AM, Rodríguez-Zaragoza S, Piñero J, et al. Balamuthia mandrillaris in South America: an emerging potential hidden pathogen in Perú. *Exp Parasitol.* 2014; 145(suppl):S10-S19.
41. Todd CD, Reyes-Battle M, Piñero JE, et al. Balamuthia mandrillaris therapeutic mud bath in Jamaica. *Epidemiol Infect.* 2015;143(10):2245-2248.

42. Schuster FL, Dunnebacke TH, Booton GC, et al. Environmental isolation of *Balamuthia mandrillaris* associated with a case of amebic encephalitis. *J Clin Microbiol*. 2003;41(7):3175-3180.
43. Dunnebacke TH, Schuster FL, Yagi S, et al. *Balamuthia mandrillaris* from soil samples. *Microbiology (Reading)*. 2004;150(9):2837-2842.
44. Niyyati M, Lorenzo-Morales J, Rezaeian M, et al. Isolation of *Balamuthia mandrillaris* from urban dust, free of known infectious involvement. *Parasitol Res*. 2009;106(1):279-281.
45. Cabello-Vílchez AM, Reyes-Battle M, Montalbán-Sandoval E, et al. The isolation of *Balamuthia mandrillaris* from environmental sources from Peru. *Parasitol Res*. 2014;113(7):2509-2513.
46. Jackson BR, Kucerova Z, Roy SL, et al. Serologic survey for exposure following fatal *Balamuthia mandrillaris* infection. *Parasitol Res*. 2014;113(4):1305-1311.
47. Bravo F, Gotuzzo E. Amebiasis de vida libre. *Dermatol Pediatr Lat*. 2005;3(1):67-70.
48. LaFleur M, Joyner D, Schlakman B, et al. *Balamuthia mandrillaris* meningoencephalitis associated with solid organ transplantation—review of cases. *J Radiol Case Rep*. 2013;7(9):9-18.
49. Farnon EC, Kokko KE, Budge PJ, et al. Transmission of *Balamuthia mandrillaris* by organ transplantation. *Clin Infect Dis*. 2016;63(7):878-888.
50. Bravo FG, Cabrera J, Gotuzzo E. Cutaneous manifestations of infection by free living amebas, with special emphasis on *Balamuthia mandrillaris*. In: Tying SK, Lupi O, Henage UR, eds. *Tropical Dermatology*. Churchill Livingstone; 2005:49-56.
51. Valverde J, Arrese JE, Piérard GE. Granulomatous cutaneous centofacial and meningocerebral amebiasis. *Am J Clin Dermatol*. 2006;7(4):267-269.
52. Steinberg JP, Galindo RL, Kraus ES, Ghanem KG. Disseminated acanthamebiasis in a renal transplant recipient with osteomyelitis and cutaneous lesions: case report and literature review. *Clin Infect Dis*. 2002;35(5):e43-e49.
53. Bravo F, Torres Cabala C, Delgado W, et al. Hallazgos Histopatológicos de la infección de piel y mucosas por *Balamuthia mandrillaris*. Paper presented at: Congreso de la Sociedad Latinoamericana de Patología; October 25, 1999; Lima, Perú.
54. Oddó BD. Infecciones por amebas de vida libre. Comentarios históricos, taxonomía y nomenclatura, protozoología y cuadros anatómo-clínicos. *Rev Chilena Infectol*. 2006;23(3):200-214.
55. Lehmer LM, Ulibarri GE, Ragsdale BD, et al. Cutaneous *Balamuthia mandrillaris* infection as a precursor to *Balamuthia amoebic encephalitis* (BAE) in a healthy 84-year-old Californian. *Dermatol Online J*. 2017;23(7):13030/qt8c8720qm.