

Combined Bilateral Lung Transplantation and Off-Pump Coronary Artery Bypass

Young Woo Do, M.D., Hee Suk Jung, M.D., Chang Young Lee, M.D.,
Jin Gu Lee, M.D., Young-Nam Youn, M.D., Hyo Chae Paik, M.D.

Department of Thoracic and Cardiovascular Surgery, Yonsei University College of Medicine

Coronary artery disease has historically been a contraindication to lung transplantation. We report a successful combined bilateral lung transplantation and off-pump coronary artery bypass in a 62-year-old man. The patient had a progressive decline in lung function due to idiopathic pulmonary fibrosis and a history of severe occlusive coronary artery disease.

Key words: 1. Lung transplantation
2. Coronary artery disease
3. Off-pump
4. Coronary artery bypass surgery

Case report

A 62-year-old man (height, 158 cm; weight, 63 kg; blood type, A⁺) with a history of smoking (35 pack-years) was registered for lung transplantation with a diagnosis of idiopathic pulmonary fibrosis. The patient experienced a progressive decline in lung function for eight months. Symptoms did not improve with medical treatment. The patient's status was New York Heart Association Functional Class III, and the patient had lost 5 kg over a 6-month period. Room air arterial blood gas analysis showed an oxygen partial pressure of 59.1 mm Hg, partial pressure of CO₂ was 39.2 mm Hg, and oxygen saturation was 89.4%. A pulmonary function test revealed a forced vital capacity of 1.60 L (47% of predicted) and a forced expiratory volume in 1 second of 1.52 L (61% of predicted). Computed tomography revealed subpleural and peribronchovascular reticulation with macrocystic honeycombing in both lungs (Fig. 1).

Coronary angiography revealed total occlusion at the mid-right coronary artery, and left ventricular ejection fraction of 61% (Fig. 2). Therefore, we concluded that the patient needed bilateral lung transplantation and also required coronary artery bypass surgery. We decided to perform the coronary artery bypass surgery followed by bilateral lung transplantation.

Two months after being listed for a lung transplant, a suitable donor lung was matched. The donor was a 49-year-old man (height, 170 cm; weight, 52.1 kg; blood type, A⁺) who had an intracranial hemorrhage. The total lung capacity of the recipient was 4.755 L, while that of the donor was 6.078 L, which was a donor-to-recipient size match of 127.8%.

Prior to the lung transplant, the patient's vital signs were stable (heart rate of 98 beats per minute and arterial blood pressure of 115/75 mm Hg). After the induction of general anesthesia, a pulmonary arterial catheter was placed via the left internal jugular vein,

Received: December 1, 2015, Revised: January 20, 2016, Accepted: January 29, 2016, Published online: December 5, 2016

Corresponding author: Hyo Chae Paik, Department of Thoracic and Cardiovascular Surgery, Yonsei University College of Medicine, 50-1 Yonsei-ro, Seodaemun-gu, Seoul 03722, Korea
(Tel) 82-2-2228-2140 (Fax) 82-2-393-6012 (E-mail) hcpaik@yuhs.ac

© The Korean Society for Thoracic and Cardiovascular Surgery. 2016. All right reserved.

© This is an open access article distributed under the terms of the Creative Commons Attribution Non-Commercial License (<http://creativecommons.org/licenses/by-nc/4.0>) which permits unrestricted non-commercial use, distribution, and reproduction in any medium, provided the original work is properly cited.

and the pulmonary arterial pressures were initially 40–50/20–30 mm Hg.

The operation was performed as follows: under general anesthesia, a clamshell incision was made and the hila were prepared for lung transplantation. At the same time, the left greater saphenous vein was harvested for coronary artery bypass. Following a minimal dissection in both hila, the saphenous vein was anastomosed to the ascending aorta using a Heartstring device (Heartstring Proximal Seal System, Guidant, IN, USA), and the right coronary artery was bypassed to the right posterior descending artery via the off-pump technique using a tissue stabilizer. The patency of the saphenous vein was confirmed by a

flowmeter. After coronary revascularization, peripheral venoarterial extracorporeal membrane oxygenation (ECMO) was started. A venous cannula was placed in the right femoral vein and an arterial cannula was placed into the right femoral artery. This was followed by sequential right and left lung transplantation. Each side started with bronchial anastomosis, followed by pulmonary venous anastomosis with a side-biting clamp on the pulmonary veins, and ended with pulmonary artery anastomosis. ECMO was discontinued and decannulated before the patient was transferred from the operating room to the intensive care unit. The total ECMO time was 320 minutes, total operation time was 461 minutes, and total anesthesia time was 565 minutes.

Postoperatively, there was no primary graft dysfunction or acute cellular rejection. Prednisone was used in combination with tacrolimus and mycophenolate for maintenance immunosuppression. On postoperative day (POD) 3, heart rate ranged from 85 to 90 beats per minute, arterial blood pressure ranged from 110 to 120 mm Hg/70 to 80 mm Hg, and pulmonary arterial pressure ranged from 35 to 37 mm Hg/15 to 17 mm Hg.

The patient required a tracheostomy for recovery due to respiratory failure after tracheal extubation on POD 8. After 7 days of tracheostomy, ventilator weaning was possible. The patient was transferred to the general ward on POD 16, the tracheostomy tube was removed on POD 30, and discharged on POD 37 in good condition.

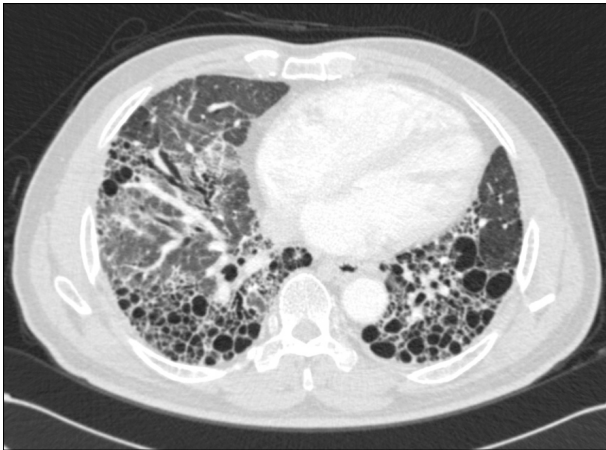


Fig. 1. Preoperative chest computed tomography. Subpleural and peribronchovascular reticulation with macrocystic honeycombing is visible in both lungs.

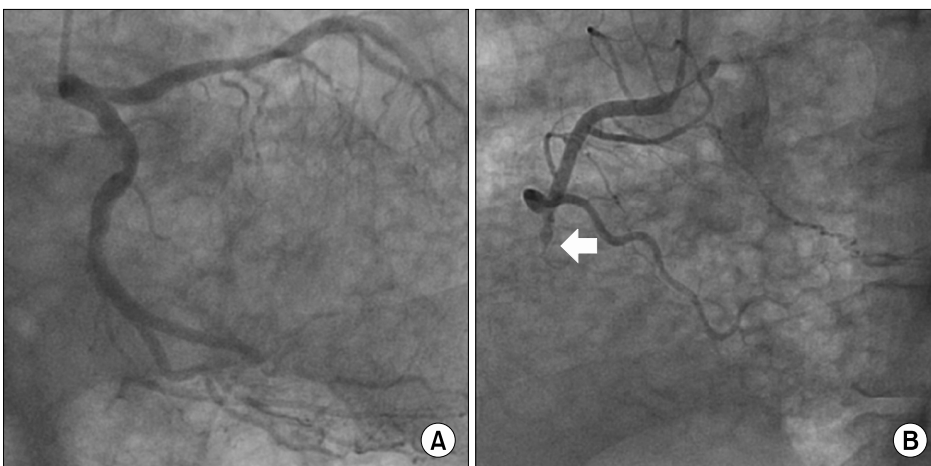


Fig. 2. Preoperative coronary angiography. (A) Normal left coronary artery (left anterior oblique view). (B) Total occlusion of the mid right coronary artery (white arrow, left anterior oblique view).

Discussion

The presence of comorbidities in patients has previously been considered to be a relative contraindication for lung transplantation. In particular, coronary artery disease was considered to be a serious surgical risk [1]. The first lung transplantation was performed at Severance Hospital in July 1996 [2], and since then, the number of lung transplantations has increased. At the same time, the inclusion criteria for lung transplantation have been expanded to include patients with higher surgical risk.

Whether patients with significant coronary artery disease are suitable candidates for lung transplantation is unclear. Some reports have described the long-term survival outcomes following lung transplantation in cases with revascularized coronary arteries. One report demonstrated that the long-term survival following lung transplantation in patients with significant coronary artery disease was influenced by whether they received coronary revascularization prior to lung transplantation [3]. However, some studies have reported successful results in the management of patients who simultaneously received coronary artery revascularization and lung transplantation [4,5]. Patel et al. [4] reported successful simultaneous coronary artery bypass and lung transplantation in a small number of carefully selected patients. Lee et al. [5] also reported combined lung transplantation and coronary bypass grafting in four select cases. However, patients with multivessel disease or left ventricular dysfunction were not considered suitable candidates for lung transplantation.

In this case, combined bilateral lung transplantation and coronary artery bypass grafting was performed in a patient who had a single vessel disease with normal left ventricular function. In terms of surgical technique and devices, the off-pump technique was possible for the coronary bypass grafting through a clamshell incision. Using a saphenous vein graft might have enabled coronary artery grafting to be performed without much difficulty through the usual clamshell incision. In Korea at present, almost 50% of coronary graft bypass surgeries are performed via off-pump technique. Our previous study indicated that off-pump coronary artery bypass surgeries improved myocardial functioning and favored early and mid-term outcomes in the high-risk group [6].

Both single and bilateral lung transplantation have been accepted as worthy of treatment for idiopathic pulmonary fibrosis. Procedure selection should be carefully considering the following factors: recipient, donor, and transplant center. Although single lung transplantation reduced waitlist time and mortality, the long-term outcomes of bilateral lung transplantation were slightly superior [7]. The benefits of bilateral lung transplantation include better lung compliance, improved lung volume, and avoidance of native lung disorders. For these reasons, we performed a bilateral lung transplantation.

Intraoperatively, we used ECMO for cardiopulmonary support. Our center has used both ECMO and conventional cardiopulmonary bypass in the lung transplantation procedure. However, ECMO has been considered the method of choice since 2013 because of its advantages, such as less coagulopathy, less systemic inflammatory response, short postoperative recovery time, and less pulmonary and renal complications [8,9]. With off-pump coronary artery bypass graft surgery, we could use ECMO for cardiopulmonary support instead of conventional cardiopulmonary bypass.

To the best of our knowledge, this case was the first successful bilateral lung transplantation combined with off-pump coronary artery bypass graft surgery in Korea, and we reported a satisfactory outcome following surgery.

Conflict of interest

No potential conflict of interest relevant to this article was reported.

References

1. Aurora P, Boucek MM, Christie J, et al. *Registry of the International Society for Heart and Lung Transplantation: tenth official pediatric lung and heart/lung transplantation report--2007*. *J Heart Lung Transplant* 2007;26:1223-8.
2. Haam SJ, Lee DY, Paik HC. *An overview of lung transplantation in Korea*. *Transplant Proc* 2008;40:2620-2.
3. Seoane L, Arcement LM, Valentine VG, McFadden PM. *Long-term survival in lung transplant recipients after successful preoperative coronary revascularization*. *J Thorac Cardiovasc Surg* 2005;130:538-41.
4. Patel VS, Messier RH, Palmer SM, Davis RD. *Coronary artery revascularization in eligible lung transplant recipients*. *J*

- Heart Lung Transplant 2001;20:223.
5. Lee R, Meyers BF, Sundt TM, Trulock EP, Patterson GA. *Concomitant coronary artery revascularization to allow successful lung transplantation in selected patients with coronary artery disease.* J Thorac Cardiovasc Surg 2002; 124:1250-1.
 6. Youn YN, Yoo KJ, Lee KJ, Bae MK, Shim YH. *The comparison study of early and midterm clinical outcome of off-pump versus on-pump coronary artery bypass grafting in patients with severe left ventricular dysfunction (LVEF< or =35%).* Korean J Thorac Cardiovasc Surg 2006;39:184-93.
 7. Brown AW, Kaya H, Nathan SD. *Lung transplantation in IIP: a review.* Respirology 2016;21:1173-84.
 8. Bermudez CA, Shiose A, Esper SA, et al. *Outcomes of intraoperative venoarterial extracorporeal membrane oxygenation versus cardiopulmonary bypass during lung transplantation.* Ann Thorac Surg 2014;98:1936-42.
 9. Machuca TN, Collaud S, Mercier O, et al. *Outcomes of intraoperative extracorporeal membrane oxygenation versus cardiopulmonary bypass for lung transplantation.* J Thorac Cardiovasc Surg 2015;149:1152-7.