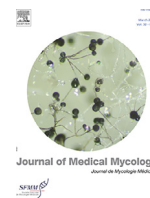




Since January 2020 Elsevier has created a COVID-19 resource centre with free information in English and Mandarin on the novel coronavirus COVID-19. The COVID-19 resource centre is hosted on Elsevier Connect, the company's public news and information website.

Elsevier hereby grants permission to make all its COVID-19-related research that is available on the COVID-19 resource centre - including this research content - immediately available in PubMed Central and other publicly funded repositories, such as the WHO COVID database with rights for unrestricted research re-use and analyses in any form or by any means with acknowledgement of the original source. These permissions are granted for free by Elsevier for as long as the COVID-19 resource centre remains active.



General review

Coincidence or reality behind Mucormycosis, diabetes mellitus and Covid-19 association: A systematic review



Indraneel Sengupta, Tilak Nayak*

Department of Life Science and Biotechnology, Jadavpur University, Kolkata 700032, India

ARTICLE INFO

Article History:

Received 8 July 2021

Revised 31 January 2022

Accepted 17 February 2022

Available online 18 February 2022

Keywords:

Mucormycosis

Covid-19

Diabetes mellitus

Immunosuppression

ABSTRACT

Mucormycosis is a rare but life-threatening disease with high morbidity and mortality and is difficult to diagnose. Mucormycosis, is a severe but rare fungal infection caused by a group of molds called mucormycetes. Diabetes, use of corticosteroids, metabolic/diabetic acidosis and Covid-19 mediated immunosuppression are reported in more than 70% of cases in mucormycosis patients. Coexisting mucormycosis, Covid-19 along with diabetes mellitus increase the likelihood of mortality. Despite its occurrence since the beginning of the pandemic, there are still unanswered concerns regarding the origin of this fungal infection and mortality rate and/or relation with diabetic patients. In this review, we describe the detailed view of causative pathogens responsible for mucormycosis, diabetes mellitus and Covid-19 association along with the morbidity cases during the latest Covid-19 crisis. In the case of mucormycosis diagnosis, imaging, histopathological confirmation, fungal culture and molecular identification methods should be considered. Once mucormycosis is diagnosed, a combined treating method consisting of antifungals administration like amphotericin B, surgical intervention is needed for the reversal of the underlying condition. Early detection of this potentially life-threatening infection and timely care is needed in lowering mortality rates.

© 2022 SFMM. Published by Elsevier Masson SAS. All rights reserved.

1. Introduction

Phycomycosis or zygomycosis was first described in 1885 and later coined as Mucormycosis in 1957 by Baker [1] an American pathologist for infection caused by *Rhizopus spp.* Mucormycosis is a fatal fungal infection caused mainly by the genus by *Rhizopus spp.*, *Mucor spp.*, *Rhizomucor spp.*, *Cunninghamella spp.* and *Lichthemia spp.* where *Rhizopus spp.* is responsible for almost 60% of the total infection [2].

Recently, mucormycosis in people with Covid-19 have been increasingly reported worldwide, in particular from India. The primary cause of facilitating mucorales spores to germinate in patients with mucormycosis associated with Covid-19 is due to low oxygen condition, favorable acidic medium, high glucose level and low phagocytic activity due to immunosuppression (SARS-CoV-2 mediated) along with several other risk factors including background comorbidities and prolonged hospitalization. The mucormycosis varied from 0.005 to 1.7 per million people all over the world, while its prevalence is nearly 80 times higher (0.14 per 1000) in India [3–5]. Although hematological malignancies and organ transplant take the lead in mucormycosis, diabetes mellitus (DM) remains the leading risk factor associated with mucormycosis globally, with an overall mortality of 46% [6–7]. India is the second

largest population with diabetes mellitus (DM) and diabetes has been the most common risk factor linked with mucormycosis, which may be the reason behind this huge prevalence of this infection [8]. In the current scenario of Covid-19 pandemic where corticosteroids are often being used, a rise in cases of mucormycosis in people with Covid-19 with DM has been observed especially in India [9]. Seeing all these reports and cases mucormycosis with Covid-19 with DM may need to be evaluated as an emerging disease association. These findings need a relook in the context of Covid-19 pandemic where rapid spreading of mucormycosis is an alarming concern and even a delay of 12 h in the diagnosis could be fatal [10]. This concern directed us to write a systematic review where we describe in detail disease specific mucormycosis causing fungal strain and published case reports/series of mucormycosis in people with Covid-19 and to find its association with diabetes mellitus. We additionally discussed a mechanistic explanation as to why mucormycosis could be increasingly linked to Covid-19 and diabetes mellitus and possible ways to stay far from this infection. Along with it we also mention the mucormycosis infected patient's symptoms, details diagnosis processes, what to do/don't to overcome its attack and possible treatments.

2. Fungal diversity caused by mucormycosis

In current days one of the most alarming concerns as fungal coinfections in Covid-19 pandemic is the mucormycosis. This

* Corresponding author.

E-mail address: tnayak078@gmail.com (T. Nayak).

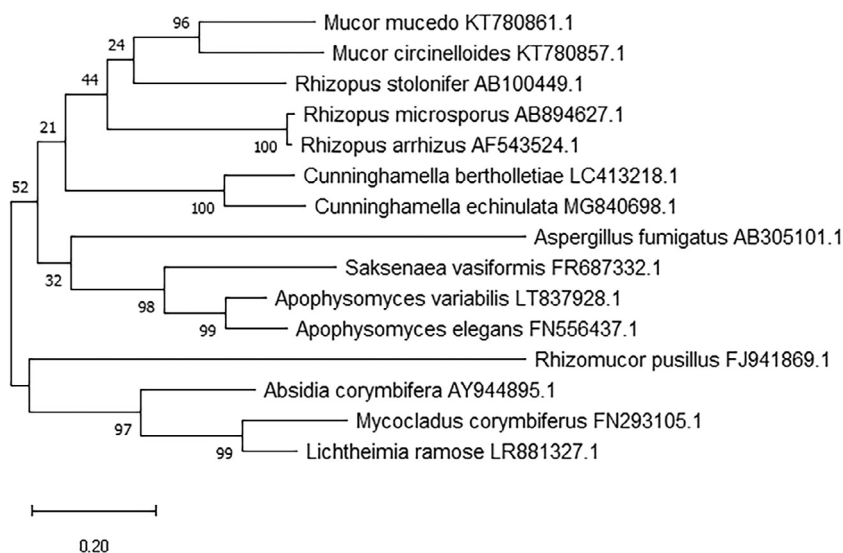


Fig. 1. Phylogenetic tree based mucormycosis diversity/distance visualization. 16S rRNA gene sequences were collected from NCBI Nucleotide database with accession number. Tree was constructed on MEGA X software through Neighbor-joining tree and 1000 Bootstrap method.

infection is mainly caused by the fungi of the order Mucorales [11–12]. Previous reports said that the major pathogens responsible for this infection are *Rhizopus* spp, *Mucor* spp and *Lichtheimia* spp, along with *Rhizomucor* spp, *Cunninghamella* spp, *Apophysomyces* spp and *Saksenaea* spp (Fig. 1) [13–15]. The major pathogen responsible for the infection was identified as *Lichtheimia* spp. in Spain [16]. There are several reports which state that among different kinds of mucormycosis, pulmonary mucormycosis, cutaneous, soft-tissue mucormycosis and rhino-orbito-cerebral mucormycosis are the major ones that have the most severe clinical manifestation [17]. Cutaneous or soft tissue mucormycosis which is caused by *Apophysomyces variabilis* is the most commonly observed mucormycosis caused as a coinfection during skin disruption due to traumatic injury like from natural disasters, motor vehicle accidents, improvised explosive devices in theatres of war/iatrogenic sources, surgery/burns in immunocompetent patients [18–23]. *Lichtheimia corymbifera* is another pathogen responsible for a special skin lesion called ‘black eschar’ often found in patients suffering from mucormycosis [17]. Most diabetic patients are susceptible to rhino-orbito-cerebral mucormycosis whereas pulmonary mucormycosis typically develops in patients with neutropenia and graft-versus-host disease [13, 24]. Besides that, skin damage is another major clinical manifestation associated with mucormycosis which is caused by *R. pusillus*, *M. circinelloides*, *L. corymbifera* and *S. vasiformis* etc. [16]. Finally it was reported that the *Rhizopus* spp is a most common type and along with it *Mucor* spp, *Lichtheimia* spp, *Rhizomucor* spp, *Cunninghamella* spp, *Apophysomyces* spp and *Saksenaea* spp were responsible for mucormycosis cases found in Covid-19 affected DM patients [17].

3. Coincidence or reality behind ‘mucormycosis’, diabetes mellitus and Covid-19 association

Recently, multiple cases of mucormycosis in persons infected with Covid-19 have been recorded all over the world, particularly in India. This infection varied from 0.005 to 1.7 per million people all over the world, while its prevalence is nearly 80 times higher (0.14 per 1000) in India [3–5]. Although, DM is the leading risk factor associated with mucormycosis globally with a 46% mortality rate [7] and this number may appear to be triggered by Covid-19 because of the following reasons (Fig. 2):

- Low pH, due to diabetic ketoacidosis (DKA) is a fertile medium for mucorales spores to germinate. Moreover, intake of corticosteroids reduces the phagocytic activity of WBC like bronchoalveolar macrophages migration, ingestion and phagolysosome fusion may be the reason for diabetic people vulnerable to mucormycosis. In addition, enhances the expression of fungal ligand spore coating homolog (CoH) protein and glucose-regulator protein 78 (GRP-78) of endothelium cells enabling angio-invasion and tissue necrosis.
- In Hyperglycemia, glycosylation of transferrin, ferritin, and reduced iron binding capacity increase free iron level, which is an excellent resource for mucormycosis. An Increase in cytokines (cytokine storm) in patients with Covid-19 especially interleukin-6, increases free iron by increasing ferritin levels due to decreased iron transport may be a probable cause for higher risk of infection to the patient associated with Covid-19.
- Covid-19 often causes endothelialitis, endothelial damage, thrombosis, lymphopenia, and reduction in CD4+ and CD8+ level and thus predisposes to mucormycosis [26].
- In addition, *Rhizopus* species have an active ketone reductase system, which helps *Rhizopus* to grow in the acidic/glucose-rich environment seen in ketoacidosis conditions of diabetic patients [27].
- From reports, it was observed that in extensive mucormycosis, patients had elevated levels of glycated hemoglobin (HbA1c > 10%) of a diabetic patient and were also Covid-19 positive [28].
- Covid-19 is an optimum environment of low oxygen condition which favors the growth of mucorales which are responsible for mucormycosis as well [25].

According to news, there are too many cases (140 cases per million populations) but very few are reported in the literature from India [6, 29, 30]. During the second wave of the Covid-19 pandemic continues (until 19 May 2021) approximately 5500 people were affected with Covid-19 associated mucormycosis in India, resulting in 126 casualties [29]. In another literature a total of 81.2% cases of mucormycosis patients with Covid-19 were reported from India, 8.9% cases from the USA, 3.1% cases from Iran and only 18.8% cases as of now were reported from other parts of the world like UK [25, 31–41]. Reports showed mucormycosis was predominantly seen in males (78.9%), both in people who were active (59.4%) or recovered (those patients who were either discharged from hospital or in-hospital)

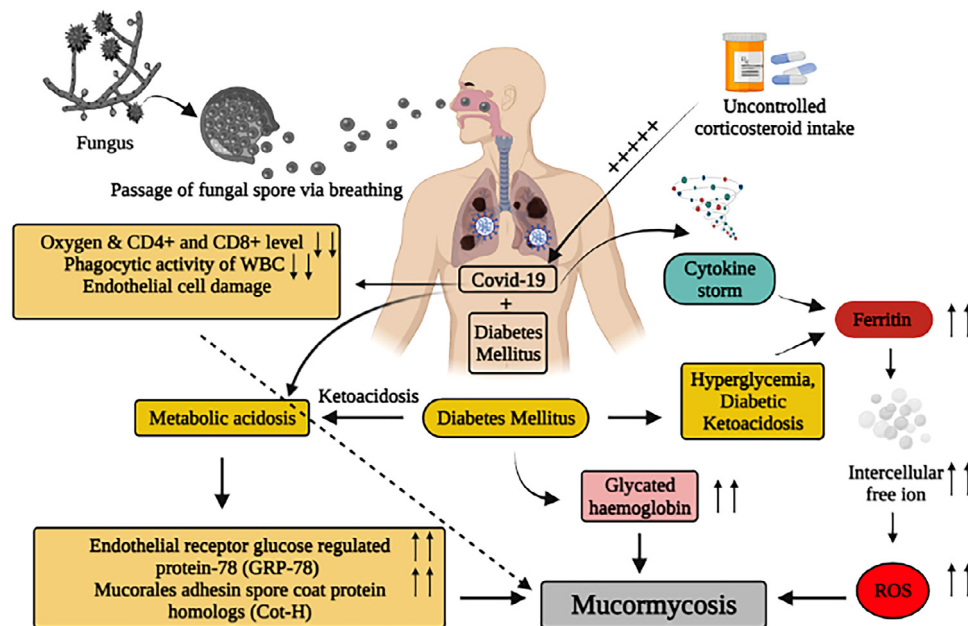


Fig. 2. Molecular level interaction of diabetes mellitus and Covid-19 with mucormycosis.

(40.6%) from Covid-19. Besides that, it was also observed from the report's hyperglycemia was the most prevalent risk factor observed in the majority of cases (83.3%) of mucormycosis in people with Covid-19 followed by cancer (3.0%) and post-transplant (1%) globally. According to literature surveys and reports unarguably it is confirmed that diabetes mellitus is a major risk factor for mucormycosis.

4. Symptoms of mucormycosis with Covid-19

This fungal infection starts in the sinus and progresses to the eyes in Covid-19 patients. In the next 24 h, the mucormycosis will spread to the brain [2]. According to the Centers for Disease Control and Prevention (CDC) the symptoms of mucormycosis differ based on where the infection develops. One-sided facial swelling, nasal/sinus inflammation, cough, fever, and dark lesions on the nasal bridge or upper interior of the mouth are major signs and symptoms that quickly convert into the signs of rhinocerebral mucormycosis. Fever, chest pressure, cough, and shortness of breath are the pulmonary mucormycosis specific symptoms. Improved results in mucormycosis patients are fully dependent on early identification and diagnosis of the infection, as well as timely delivery of effective antifungal therapy [17].

5. Diagnosis methods

The capability of diagnosing mucormycosis truly depends on the availability of techniques and trained personnel. Mucormycosis suspected patients should be referred to the highest care level immediately.

In patients with hematological malignancy, suspected pulmonary mucormycosis, eye and brain pulmonary CT scan or MRI should be conducted in lieu of a CT scan due to substantially greater sensitivity [17]. In diabetic patients, cranial CT or MRI is strongly recommended to determine if sinusitis with facial pain, sinusitis, proptosis and ophthalmoplegia symptoms. If sinusitis is diagnosed, endoscopy is needed to diagnose mucormycosis. Mucormycosis is usually suspected based on direct microscopy of clinical specimens stained with fluorescent dye blankophor (Tanatax Chemicals, Ede, The Netherlands) or calcofluor white (Sigma Aldrich, St Louis, MO, USA) [42]. However, based on these characteristics distinguishing of Mucorales from other moulds is sometimes difficult. Therefore, it is strongly

suggested to confirm the diagnosis of mucormycosis in tissue by culture or by application of molecular or in-situ identification techniques.

The application of immunohistochemistry with commercially available monoclonal antibodies or PCR techniques on either fresh or formalin-fixed paraffin-embedded tissue is highly specific, although a variation in sensitivity has been reported, in addition, these tests might not be widely available [43–46]. Molecular identification of internal transcribed spacer (ITS) sequencing is strongly supported followed by Matrix assisted laser desorption ionization time of flight (MALDI-TOF) identification is moderately supported and preferred over morphology [17].

6. Feasible treatments for mucormycosis in Indian scenario

Mucormycosis remains a therapeutic challenge in India. In India in conjunction with surgical interventions lipid formulation of amphotericin B was widely administered to treat the infection. Along with that, removal of prejudicing factors for infection such as hyperglycemia, metabolic acidosis, immunosuppressive drugs and neutropenia, is also vital. In several patients, infected tissues or organs were removed to stop the infection and save lives [47]. So far, only three potential antifungal drugs like amphotericin B, posaconazole, and isavuconazole are available for the efficient treatment of this infection. While amphotericin B and posaconazole were the most effective antifungal drugs, but their effectiveness varies depending on the species [47]. Therefore, accurate species identification is crucial not only for the correct diagnosis of the disease but also for their treatment. Therefore, accurate and rapid species identification is urgently needed to save patients' lives in the mucormycosis outbreak among COVID-19 patients.

7. Conclusion

The Alarming rise of mucormycosis in the global scenario appears to be an unholy intersection of diabetes and Covid-19. *Rhizopus* spp is the most common species and along with it *Mucor* spp, *Lichtheimia* spp, *Rhizomucor* spp, *Cunninghamella* spp, *Apophysomyces* spp and *Saksenaia* spp were responsible for mucormycosis cases found in Covid-19 affected DM patients. The reason which facilitates Mucorales spores to infect people affected with Covid-19 along with

diabetes mellitus is an optimum environment of low oxygen condition, diabetes/hyperglycemia, metabolic/diabetic acidosis, increased ferritin and decreased phagocytic activity of white blood cells was achieved due to Covid-19 mediated immunosuppression. There are several techniques to diagnose the pathogen that can be used by a diagnosis lab according to their available/suitable procedure but our recommendation is using more than one technique for better confirmation. There have been significant challenges in treatment modality and outcome due to the Covid-19 pandemic. The possible key behind the successful recovery from this deadliest infection is an early and timely diagnosis, as well as an effort to recover from the predisposing factors. All efforts should be made to use proper antifungal therapy, control diabetes and proper evidence-based medication for Covid-19 patients is recommended to minimize the fatality of mucormycosis.

Funding

None

Author contributions

Conceptualization: Tilak Nayak

Investigation: Tilak Nayak.

Writing – original draft: Tilak Nayak & Indraneel Sengupta.

Writing – review & editing: Tilak Nayak & Indraneel Sengupta.

Declaration of Competing Interest

Authors declare that the research is free from any potential conflict of interest.

Acknowledgments

The authors are thankful to the Department of Life Science & Biotechnology, Jadavpur University for carrying the research and also acknowledging the Department of Biotechnology India for providing student fellowship (Grant No. DBT/2016/JU/732).

References

- Baker RD. Mucormycosis—A new disease? *J Am Med Assoc* 1957;163:805–8. doi: [10.1001/jama.1957.02970450007003](https://doi.org/10.1001/jama.1957.02970450007003).
- Athar F, Bhat I, Beg MA. A contemporary intimidation for COVID-19 patients coinfecting with mucormycosis in India. *J Bacteriol Mycol Open Access* 2021;9:69–71. doi: [10.15406/jbmoa.2021.09.00298](https://doi.org/10.15406/jbmoa.2021.09.00298).
- Skiada A, Pavleas I, Drogari-Apiranthitou M. Epidemiology and diagnosis of mucormycosis: An update. *J Fungi* 2020;6:1–20. doi: [10.3390/jof6040265](https://doi.org/10.3390/jof6040265).
- Chander J, Kaur M, Singla N, Punia RPS, Singhal SK, Attri AK, et al. Mucormycosis: Battle with the deadly enemy over a five-year period in India. *J Fungi* 2018;4. doi: [10.3390/jof4020046](https://doi.org/10.3390/jof4020046).
- Prakash H, Chakrabarti A. Global epidemiology of mucormycosis. *J Fungi* 2019;5. doi: [10.3390/jof5010026](https://doi.org/10.3390/jof5010026).
- Sahoo JP, Mishra AP, Pradhan P, Samal KC. Misfortune Never Comes Alone - The New "Black Fungus" Accompanying COVID-19 Wave. *Biot Res Today* 2021;3:318–20.
- Jeong W, Keighley C, Wolfe R, Lee WL, Slavin MA, Kong DCM, et al. The epidemiology and clinical manifestations of mucormycosis: a systematic review and meta-analysis of case reports. *Clin Microbiol Infect* 2019;25:26–34. doi: [10.1016/j.cmi.2018.07.011](https://doi.org/10.1016/j.cmi.2018.07.011).
- Karuranga S, Malanda B, Saeedi P, Salpea P. IDF Atlas 9th edition and other resources. *Int Diabetes Fed* 2019;1–176 9th editio <https://diabetesatlas.org/en/resources/> (accessed June 21, 2021).
- Lionakis MS, Kontoyiannis DP. Glucocorticoids and invasive fungal infections. *Lancet* 2003;362:1828–38. doi: [10.1016/S0140-6736\(03\)14904-5](https://doi.org/10.1016/S0140-6736(03)14904-5).
- Maartens G, Wood MJ. The clinical presentation and diagnosis of invasive fungal infections. *J Antimicrob Chemother* 1991;28:13–22. doi: [10.1093/jac/28.sup-pl.a.13](https://doi.org/10.1093/jac/28.sup-pl.a.13).
- Hibbett DS, Binder M, Bischoff JF, Blackwell M, Cannon PF, Eriksson OE, et al. A higher-level phylogenetic classification of the Fungi. *Mycol Res* 2007;111:509–47. doi: [10.1016/j.mycres.2007.03.004](https://doi.org/10.1016/j.mycres.2007.03.004).
- Kwon-Chung KJ. Taxonomy of fungi causing mucormycosis and entomophthoromycosis (zygomycosis) and nomenclature of the disease: Molecular mycologic perspectives. *Clin Infect Dis* 2012;54:58. doi: [10.1093/cid/cir864](https://doi.org/10.1093/cid/cir864).
- Roden MM, Zaoutis TE, Buchanan WL, Knudsen TA, Sarkisova TA, Schaufele RL, et al. Epidemiology and outcome of zygomycosis: A review of 929 reported cases. *Clin Infect Dis* 2005;41:634–53. doi: [10.1086/432579](https://doi.org/10.1086/432579).
- Skiada A, Pagano L, Groll A, Zimmerli S, Dupont B, Lagrou K, et al. Zygomycosis in Europe: Analysis of 230 cases accrued by the registry of the European Confederation of Medical Mycology (ECMM) Working Group on Zygomycosis between 2005 and 2007. *Clin Microbiol Infect* 2011;17:1859–67. doi: [10.1111/j.1469-0691.2010.03456.x](https://doi.org/10.1111/j.1469-0691.2010.03456.x).
- Sridhara SR, Paragache G, Panda NK, Chakrabarti A. Mucormycosis in immunocompetent individuals: An increasing trend. *J Otolaryngol* 2005;34:402–6. doi: [10.2310/7070.2005.34607](https://doi.org/10.2310/7070.2005.34607).
- Guinea J, Escribano P, Vena A, Muñoz P, Martínez-Jiménez MDC, Padilla B, et al. Increasing incidence of mucormycosis in a large Spanish hospital from 2007 to 2015: Epidemiology and microbiological characterization of the isolates. *PLoS One* 2017;12. doi: [10.1371/journal.pone.0179136](https://doi.org/10.1371/journal.pone.0179136).
- Cornely OA, Alastruey-Izquierdo A, Arenz D, Chen SCA, Dannaoui E, Hochhegger B, et al. Global guideline for the diagnosis and management of mucormycosis: an initiative of the European Confederation of Medical Mycology in cooperation with the Mycoses Study Group Education and Research Consortium. *Lancet Infect Dis* 2019;19:e405–21. doi: [10.1016/S1473-3099\(19\)30312-3](https://doi.org/10.1016/S1473-3099(19)30312-3).
- Singla K, Samra T, Bhatia N. Primary cutaneous mucormycosis in a trauma patient with morel-lavallée lesion. *Indian J Crit Care Med* 2018;22:375–7. doi: [10.4103/ijccm.IJCCM_343_17](https://doi.org/10.4103/ijccm.IJCCM_343_17).
- Neblett Fanfair R, Benedict K, Bos J, Bennett SD, Lo Y-C, Adebajo T, et al. Necrotizing Cutaneous Mucormycosis after a Tornado in Joplin, Missouri, in 2011. *N Engl J Med* 2012;367:2214–25. doi: [10.1056/nejmoa1204781](https://doi.org/10.1056/nejmoa1204781).
- Al-Tarrah K, Abdelaty M, Behbahani A, Mokaddas E, Soliman H, Albader A. Cutaneous mucormycosis postcosmetic surgery. *Med (United States)* 2016;95. doi: [10.1097/MD.0000000000004185](https://doi.org/10.1097/MD.0000000000004185).
- Warkentien T, Rodriguez C, Lloyd B, Wells J, Weintrob A, Dunne JR, et al. Invasive mold infections following combat-related injuries. *Clin Infect Dis* 2012;55:1441–9. doi: [10.1093/cid/cis749](https://doi.org/10.1093/cid/cis749).
- Rodriguez CJ, Tribble DR, Malone DL, Murray CK, Jessie EM, Khan M, et al. Treatment of suspected invasive fungal infection in war wounds. *Mil Med* 2018;183:142–6. doi: [10.1093/milmed/usy079](https://doi.org/10.1093/milmed/usy079).
- Hay RJ. Mucormycosis: An infectious complication of traumatic injury. *Lancet* 2005;365:830–1. doi: [10.1016/S0140-6736\(05\)71020-5](https://doi.org/10.1016/S0140-6736(05)71020-5).
- Xhaard A, Lantermier F, Porcher R, Dannaoui E, Bergeron A, Clement L, et al. Mucormycosis after allogeneic haematopoietic stem cell transplantation: A French Multicentre Cohort Study (2003–2008). *Clin Microbiol Infect* 2012;18. doi: [10.1111/j.1469-0691.2012.03908.x](https://doi.org/10.1111/j.1469-0691.2012.03908.x).
- Singh AK, Singh R, Joshi SR, Misra A. Mucormycosis in COVID-19: A systematic review of cases reported worldwide and in India. *Diabetes Metab Syndr Clin Res Rev* 2021;15:102146. doi: [10.1016/j.dsx.2021.05.019](https://doi.org/10.1016/j.dsx.2021.05.019).
- Anand VK, Alemar G, Griswold JA. Intracranial complications of mucormycosis: An experimental model and clinical review. *Laryngoscope* 1992;102:656–62. doi: [10.1288/00005537-199206000-00011](https://doi.org/10.1288/00005537-199206000-00011).
- Satish D, Joy D, Ross A. B. Mucormycosis coinfection associated with global COVID-19: a case series from India. *Int J Otorhinolaryngol Head Neck Surg* 2021;7:815. doi: [10.18203/issn.2454-5929.ijohns20211574](https://doi.org/10.18203/issn.2454-5929.ijohns20211574).
- Banerjee M, Pal R, Bhadada SK. Intercepting the deadly trinity of mucormycosis, diabetes and COVID-19 in India. *Postgrad Med J* 2021;0:1–2. doi: [10.1136/postgradmedj-2021-140537](https://doi.org/10.1136/postgradmedj-2021-140537).
- Dyer O. Covid-19: India sees record deaths as "black fungus" spreads fear. *BMJ* 2021;373:n1238. doi: [10.1136/bmj.n1238](https://doi.org/10.1136/bmj.n1238).
- Mehta S, Pandey A. Rhino-Orbital Mucormycosis Associated With COVID-19. *Cureus* 2020;12. doi: [10.7759/cureus/7026](https://doi.org/10.7759/cureus/7026).
- Garg D, Muthu V, Sehgal IS, Ramachandran R, Kaur H, Bhalla A, et al. Coronavirus Disease (Covid-19) Associated Mucormycosis (CAM): Case Report and Systematic Review of Literature. *Mycopathologia* 2021;186:289–98. doi: [10.1007/s11046-021-00528-2](https://doi.org/10.1007/s11046-021-00528-2).
- Maini A, Tomar G, Khanna D, Kini Y, Mehta H, Bhagyashree V. Sino-orbital mucormycosis in a COVID-19 patient: A case report. *Int J Surg Case Rep* 2021;82. doi: [10.1016/j.ijscr.2021.105957](https://doi.org/10.1016/j.ijscr.2021.105957).
- Mekonnen ZK, Ashraf DC, Jankowski T, Grob SR, Vagefi MR, Kersten RC, et al. Acute Invasive Rhino-Orbital Mucormycosis in a Patient with COVID-19-Associated Acute Respiratory Distress Syndrome. *Ophthal Plast Reconstr Surg* 2021;37:E40–2. doi: [10.1097/IOP.0000000000001889](https://doi.org/10.1097/IOP.0000000000001889).
- Alekseyev K, Didenko L, Chaudhry B. Rhinocerebral Mucormycosis and COVID-19 Pneumonia. *J Med Cases* 2021;12:85–9. doi: [10.14740/jmc3637](https://doi.org/10.14740/jmc3637).
- Johnson AK, Ghazarian Z, Cendrowski KD, Persichino JG. Pulmonary aspergillosis and mucormycosis in a patient with COVID-19. *Med Mycol Case Rep* 2021;32:64–7. doi: [10.1016/j.mmcr.2021.03.006](https://doi.org/10.1016/j.mmcr.2021.03.006).
- Kanwar A, Jordan A, Olewiler S, Wehberg K, Cortes M, Jackson BR. A fatal case of rhizopus azygosporus pneumonia following covid-19. *J Fungi* 2021;7:1–6. doi: [10.3390/jof7030174](https://doi.org/10.3390/jof7030174).
- Khatiri A, Chang KM, Berlinrnt I, Wallach F. Mucormycosis after Coronavirus disease 2019 infection in a heart transplant recipient – Case report and review of literature. *J Med Mycol* 2021;31. doi: [10.1016/j.mycmed.2021.101125](https://doi.org/10.1016/j.mycmed.2021.101125).
- Karimi-Galougahi M, Arastou S, Haseli S. Fulminant mucormycosis complicating coronavirus disease 2019 (COVID-19). *Int Forum Allergy Rhinol* 2021;11:1029–30. doi: [10.1002/alr.22785](https://doi.org/10.1002/alr.22785).
- Veisi A, Bagheri A, Eshaghi M, Rikhtehgar MH, Rezaei Kanavi M, Farjad R. Rhino-orbital mucormycosis during steroid therapy in COVID-19 patients: A case report. *Eur J Ophthalmol* 2021. doi: [10.1177/11206721211009450](https://doi.org/10.1177/11206721211009450).

- [40] Hanley B, Naresh KN, Roufousse C, Nicholson AG, Weir J, Cooke GS, et al. Histopathological findings and viral tropism in UK patients with severe fatal COVID-19: a post-mortem study. *The Lancet Microbe* 2020;1:e245–53. doi: [10.1016/S2666-5247\(20\)30115-4](https://doi.org/10.1016/S2666-5247(20)30115-4).
- [41] Kung HC, Huang PY, Chen WT, Ko BS, Chen YC, Chang SC, et al. 2016 guidelines for the use of antifungal agents in patients with invasive fungal diseases in Taiwan. *J Microbiol Immunol Infect* 2018;51:1–17 doi:[10.1016/j.jmii.2017.07.006](https://doi.org/10.1016/j.jmii.2017.07.006).
- [42] Jung J, Park YS, Sung H, Song JS, Lee SO, Choi SH, et al. Using immunohistochemistry to assess the accuracy of histomorphologic diagnosis of aspergillosis and mucormycosis. *Clin Infect Dis* 2015;61:1664–70. doi: [10.1093/cid/civ660](https://doi.org/10.1093/cid/civ660).
- [43] Sunagawa K, Ishige T, Kusumi Y, Asano M, Nisihikawa E, Kato M, et al. Renal abscess involving mucormycosis by immunohistochemical detection in a patient with acute lymphocytic leukemia: A case report and literature review. *Jpn J Infect Dis* 2013;66:345–7. doi: [10.7883/jyoken.66.345](https://doi.org/10.7883/jyoken.66.345).
- [44] Bernal-Martínez L, Buitrago MJ, Castelli MV, Rodríguez-Tudela JL, Cuenca-Estrella M. Development of a single tube multiplex real-time PCR to detect the most clinically relevant Mucormycetes species. *Clin Microbiol Infect* 2013;19:E1. doi: [10.1111/j.1469-0691.2012.03976.x](https://doi.org/10.1111/j.1469-0691.2012.03976.x).
- [45] Drogari-Apiranthitou M, Panayiotides I, Galani I, Konstantoudakis S, Arvanitidis G, Spathis A, et al. Diagnostic value of a semi-nested PCR for the diagnosis of mucormycosis and aspergillosis from paraffin-embedded tissue: A single center experience. *Pathol Res Pract* 2016;212:393–7. doi: [10.1016/j.prp.2016.02.010](https://doi.org/10.1016/j.prp.2016.02.010).
- [46] Baldin C, Ibrahim AS. Molecular mechanisms of mucormycosis—The bitter and the sweet. *PLoS Pathog* 2017;13. doi: [10.1371/journal.ppat.1006408](https://doi.org/10.1371/journal.ppat.1006408).
- [47] Divakar PK. Fungal Taxa Responsible for Mucormycosis/“Black Fungus” among COVID-19 Patients in India. *J Fungi* 2021;7:641. doi.org/[10.3390/jof7080641](https://doi.org/10.3390/jof7080641).