

A Case of Disseminated Infection with Skin Manifestation due to Non-*neoformans* and Non-*gattii* *Cryptococcus* in a Patient with Refractory Acute Myeloid Leukemia

Sun Seob Park¹, Hyewon Lee², Weon Seo Park³, Sang Hyun Hwang⁴, Sang Il Choi¹, Mi Hong Choi¹, Si Won Lee¹, Eun Jung Ko¹, Young Ju Choi⁵, and Hyeon-Seok Eom²

¹Department of Internal Medicine, ²Hematologic Oncology Clinic, ³Department of Pathology, ⁴Department of Laboratory Medicine, and ⁵Infectious Disease Clinic, National Cancer Center, Goyang, Korea

Cryptococcus spp. other than *Cryptococcus neoformans* or *Cryptococcus gattii* were previously considered saprophytes and thought to be non-pathogenic to humans. However, opportunistic infections associated with non-*neoformans* and non-*gattii* species, such as *Cryptococcus laurentii* and *Cryptococcus albidus*, have increased over the past four decades. We experienced a case of cryptococcosis caused by non-*neoformans* and non-*gattii* spp. in a 47-year-old female with refractory acute myeloid leukemia after allogeneic hematopoietic stem cell transplantation. The patient underwent salvage chemotherapy with fluconazole prophylaxis and subsequently developed neutropenic fever with multiple erythematous umbilicated papules. A skin biopsy revealed fungal hyphae and repetitive blood cultures showed yeast microorganisms that were identified later as *C. laurentii* by Vitek-II®. Skin lesions and fever began to improve with conventional amphotericin B therapy. The treatment regimen was continued for 21 days until the disseminated cryptococcosis was completely controlled.

Key Words: Cryptococcosis; *Cryptococcus laurentii*; Non-*neoformans*; Non-*gattii* cryptococci

Introduction

Cryptococcosis is a systemic and local fungal infection caused by *Cryptococcus* spp. It is generally agreed that most cryptococcal infections are acquired by the inhalation of infectious propagules [1].

Cryptococcosis, which is usually due to *Cryptococcus neoformans* and *Cryptococcus gattii*, is considered to be one of

the most serious fungal infections in immunocompromised patients [2]. *Cryptococcus* spp. other than *C. neoformans* and *C. gattii* were previously considered to be saprophytes and non-pathogenic to humans; however, opportunistic infections associated with rare *Cryptococcus* spp., such as *Cryptococcus laurentii* and *Cryptococcus albidus*, have increased over the past four decades [1, 3].

Despite changing trends in opportunistic infections, infec-

Received: March 16, 2015 **Accepted:** July 13, 2015 **Published online:** January 16, 2017

Corresponding Author : Hyeon-Seok Eom, MD, PhD

Department of Internal Medicine, National Cancer Center, 323 Ilsan-ro, Ilsandong-gu, Goyang 10408, Korea

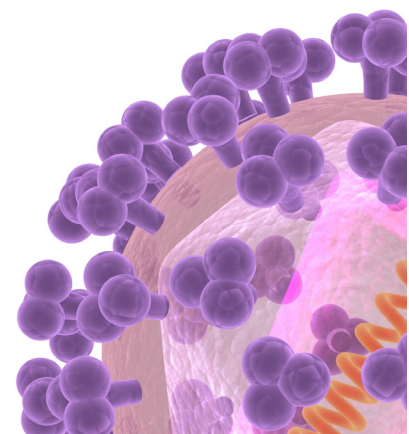
Tel: +82-31-920-2402, Fax: +82-31-920-1163

E-mail: hseom@ncc.re.kr

This is an Open Access article distributed under the terms of the Creative Commons Attribution Non-Commercial License (<http://creativecommons.org/licenses/by-nc/3.0>) which permits unrestricted non-commercial use, distribution, and reproduction in any medium, provided the original work is properly cited.

Copyrights © 2017 by The Korean Society of Infectious Diseases | Korean Society for Chemotherapy

www.icjournal.org



tions caused by non-*neoformans* and non-*gattii* *Cryptococcus* are rare. We recently experienced an immunocompromised patient with refractory acute myeloid leukemia (AML) after allogeneic hematopoietic stem cell transplantation (HSCT) who presented with fungemia and a disseminated cutaneous infection caused by non-*neoformans* and non-*gattii* *Cryptococcus*.

Case Report

A 47-year-old female diagnosed with AML underwent induction and consolidation chemotherapy. Allogeneic HSCT was subsequently performed after achieving complete remission in February 2009. Over the next 3 years, the patient showed no evidence of relapse. Then, the patient developed extramedullary relapse in the breast which was diagnosed by breast tissue biopsy.

Reinduction chemotherapy with a total of 40 Gy of radiation was administered to treat the breast mass. However, the mass increased in size after radiation therapy and a subsequent bone marrow biopsy showed the full-blown hematologic recurrence of AML. Therefore, salvage chemotherapy with fludarabine, cytarabine, and idarubicin was started for progressive AML.

During salvage chemotherapy, the patient took 250 mg of ciprofloxacin twice daily and 100 mg of fluconazole per day for prophylaxis. On day 4 after starting chemotherapy, the patient developed a fever of 38.4°C. It subsided over the course of a day following empirical antibiotic treatment with 4.5 g of pip-

eracillin/tazobactam four times per day.

On day 18, the patient again developed a high fever (38.8°C) and she exhibited multiple erythematous papules on her back, right thigh, and both arms. All other vital signs were stable, with a blood pressure of 120/80 mmHg, pulse rate of 104/min, and a breathing rate of 20/min. At this point, the patient did not have any other symptoms or signs except for an itching sensation, pain, and multiple pinhead- to matchhead-sized erythematous papules and vesicles with erythema on her back, right thigh, and extremities. Laboratory studies revealed a white blood cell count of 30/ μ L (neutrophils, 0%; lymphocytes, 80%; and monocytes, 20%), absolute neutrophil count (ANC) of 0/ mm^3 , hemoglobin level of 7.5 g/dL, platelet count of $32 \times 10^3/\text{mm}^3$, and total bilirubin level of 1.3 mg/dL. Chest and abdominal X-rays did not reveal any specific abnormalities.

Empirical antibiotic therapy was changed to cefepime (2 g, three times per day) and vancomycin (1 g, twice daily) because of the patient's persistent fever. Blood cultures, fungal cultures, and viral serologic tests were negative at this time.

Though the administered antibiotics had been modified, the patient's fever and skin lesions worsened. The cutaneous lesions changed to bullae with hemorrhagic patches (Fig. 1A) and edematous plaques (Fig. 1B). Repeated culture studies were performed; then, on day 21 after salvage chemotherapy, one set of blood culture from peripheral vein in four sets of them showed round to oval budding encapsulated yeast cells that were confirmed to be *C. laurentii*. In repeated blood culture on day 24, two sets of peripheral blood culture in four sets of blood culture examinations showed *C. laurentii* again. Bio-

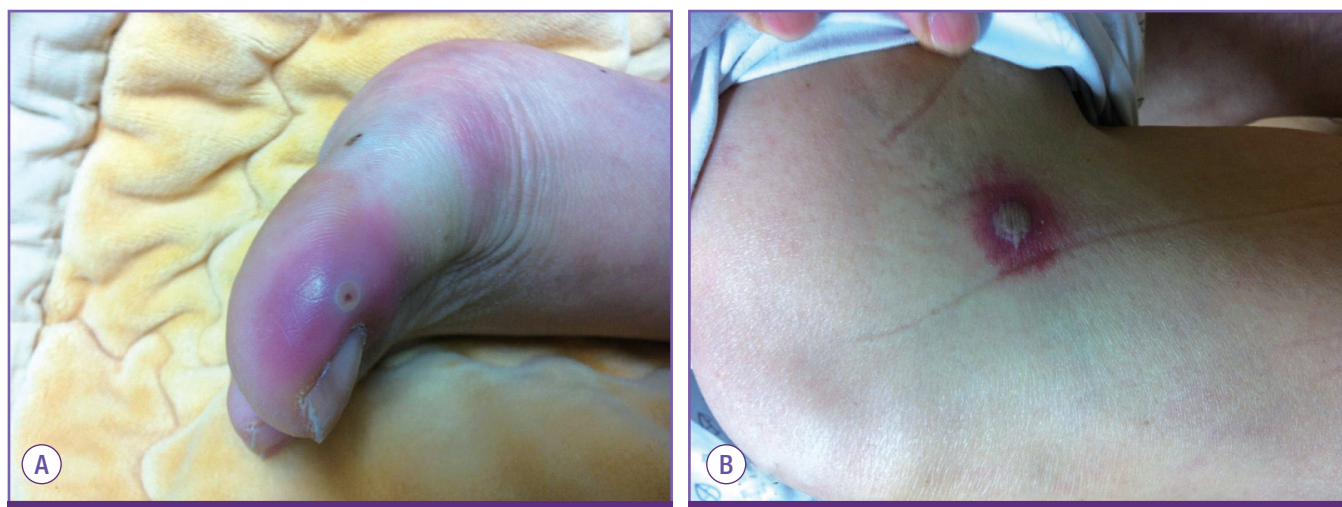


Figure 1. A skin lesion observed on day 18 after salvage chemotherapy. Multiple pinhead- to matchhead-sized papules and vesicles with erythema were observed initially, followed by 1 cm-sized bullae with hemorrhagic patches (A) and 2 cm-sized erythematous and edematous plaques with central bullous changes (B).

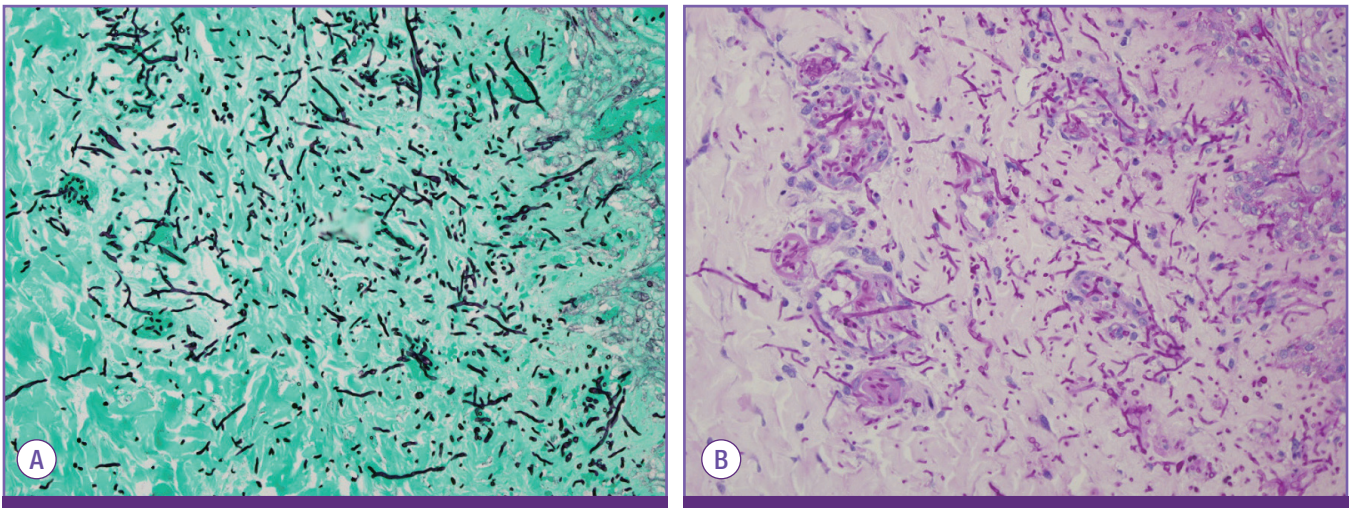


Figure 2. Pathologic findings from a skin biopsy. Fungal hyphae were observed using Grocott's methenamine silver stain (A, $\times 400$) and Periodic acid-Schiff staining (B, $\times 400$).

chemical identification of the culture was conducted by automated Vitek-II[®] (bioMérieux, Durham, NC, USA). A skin biopsy was also performed on day 26, and it revealed the presence of fungal hyphae (Fig. 2).

The patient was administered conventional amphotericin B (1 mg/kg, daily) beginning on day 27, immediately after the cryptococcosis was documented. The patient's cutaneous lesions started to improve and her fever subsided after 2 days of treatment. Follow-up blood cultures became negative within 4 days. On day 29 after salvage chemotherapy, the ANC was recovered to $1,500/\text{mm}^3$. Amphotericin B was given for 3 weeks (cumulative dose, 1,284 mg), after which the disseminated cryptococcosis was deemed completely controlled.

Discussion

Cryptococcus spp. are encapsulated, basidiomycetous yeasts that are present in the environment worldwide. *Cryptococcus* spp. generally occur in soil contaminated with pigeon feces and are often transmitted to humans through inhaled fomites [4, 5]. There have been increasing reports of non-*neoformans* and non-*gattii* cryptococcosis over the past four decades [1, 6].

Cryptococcus spp. other than *C. neoformans* or *C. gattii* is extremely rare and includes *C. laurentii* and *C. albidus*. We identified *C. laurentii* from presented case by automated Vitek-II[®] (bioMérieux, USA), and it has high probability to be *C. laurentii*. Although we tried to perform DNA sequencing with paraffin-embedded skin block, we failed to amplify fungal DNA.

Although non-*neoformans* and non-*gattii* cryptococcosis has been reported as occurring worldwide, its natural habitat

or clinical characteristics have not been thoroughly established because of a lack of cases [1, 2]. Bloodstream and central nervous system infections are the most common forms of non-*neoformans* and non-*gattii* cryptococcosis. In the current case, the patient had a disseminated infection that presented with early skin manifestations. The patient had a refractory hematologic malignancy after allogeneic HSCT and was treated with multi-agent chemotherapy.

Cryptococcus spp. is capable of assuming different morphotypes: yeast, pseudohyphae, and hyphae. The yeast form is the most common cell type observed clinically [7]. The hyphal and pseudohyphal forms are rarely observed in the clinical setting and are considered attenuated in virulence during cryptococcosis in a mammalian host [7, 8]. The regulation of Ace2 and morphogenesis (RAM) pathway and the transcription factor ZNF2 is the master activator of the yeast transformation [7]. Any mutations of RAM pathway in *Cryptococcus* render cells constitutively in the pseudohyphal form and elevated expression of ZNF2 drives hyphal growth [7, 9].

The existing antifungal options and duration of treatment for cryptococcosis have been established largely for *C. neoformans* infections. The mainstay of treatment for cryptococcosis is combination therapy with amphotericin B and 5-flucytosine or monotherapy with amphotericin B [1, 10]. According to the case reports published thus far, the initial treatment for a rare *Cryptococcus* spp. infection is removal of the infection source either through the combined use of amphotericin B and 5-flucytosine or monotherapy with amphotericin B or fluconazole [1, 3]. Monotherapy with fluconazole or itraconazole can be used for patients that have only regional symptoms without a central nervous system or systemic infection [11, 12]. In pa-

tients with fungemia, combined treatment with amphotericin B and 5-flucytosine for the first 10–14 days followed by monotherapy with fluconazole or itraconazole for several weeks has been reported [1, 11]. However, there is no validated standard treatment for rare *Cryptococcus* spp. infections because of the lack of cases. In the presented case, the infection occurred during fluconazole prophylaxis, indicating the possibility of an azole-resistant pathogen. Therefore, we switched to amphotericin B, which showed good efficacy.

Non-*neoformans* and non-*gattii* cryptococcosis, especially disseminated infections with a cutaneous manifestation, are rare; However these rare *Cryptococcus* spp. Infections have increased in recent years. In severely immunocompromised patients with persistent febrile neutropenia, non-*neoformans* and non-*gattii* cryptococcosis should be considered, especially when an azole-resistant fungal infection is suspected.

Conflicts of Interest

No conflicts of interest.

ORCID

Sun Seob Park <https://orcid.org/0000-0001-6091-4873>

Hyeon-Seok Eom <https://orcid.org/0000-0002-0484-2067>

References

1. Khawcharoenporn T, Apisarnthanarak A, Mundy LM. Non-*neoformans* cryptococcal infections: a systematic review. *Infection* 2007;35:51-8.
2. Shankar EM, Kumarasamy N, Bella D, Renuka S, Kownhar H, Suniti S, Rajan R, Rao UA. Pneumonia and pleural effusion due to *Cryptococcus laurentii* in a clinically proven case of AIDS. *Can Respir J* 2006;13:275-8.
3. Cheng MF, Chiou CC, Liu YC, Wang HZ, Hsieh KS. *Cryptococcus laurentii* fungemia in a premature neonate. *J Clin Microbiol* 2001;39:1608-11.
4. Gupta RK, Khan ZU, Nampoory MR, Mikhail MM, Johnny KV. Cutaneous cryptococcosis in a diabetic renal transplant recipient. *J Med Microbiol* 2004;53:445-9.
5. Chand-Goyal T, Spotts RA. Enumeration of bacterial and yeast colonists of apple fruits and identification of epiphytic yeasts on pear fruits in the Pacific Northwest United States. *Microbiol Res* 1996;151:427-32.
6. Johnson LB, Bradley SE, Kauffman CA. Fungaemia due to *Cryptococcus laurentii* and a review of non-*neoformans* cryptococcaemia. *Mycoses* 1998;41:277-80.
7. Lin J, Idnurm A, Lin X. Morphology and its underlying genetic regulation impact the interaction between *Cryptococcus neoformans* and its hosts. *Med Mycol* 2015;53:493-504.
8. Magditch DA, Liu TB, Xue C, Idnurm A. DNA mutations mediate microevolution between host-adapted forms of the pathogenic fungus *Cryptococcus neoformans*. *PLoS Pathogens* 2012;8:e1002936.
9. Walton FJ, Heitman J, Idnurm A. Conserved elements of the RAM signaling pathway establish cell polarity in the basidiomycete *Cryptococcus neoformans* in a divergent fashion from other fungi. *Mol Biol Cell* 2006;17:3768-80.
10. Kulkarni A, Sinha M, Anandh U. Primary cutaneous cryptococcosis due to *Cryptococcus laurentii* in a renal transplant recipient. *Saudi J Kidney Dis Transpl* 2012;23:102-5.
11. Saag MS, Graybill RJ, Larsen RA, Pappas PG, Perfect JR, Powderly WG, Sobel JD, Dismukes WE. Practice guidelines for the management of cryptococcal disease. *Clin Infect Dis* 2000;30:710-8.
12. Husain S, Wagener MM, Singh N. *Cryptococcus neoformans* infection in organ transplant recipients: variables influencing clinical characteristics and outcome. *Emerg Infect Dis* 2001;7:375-81.