



## Original Article

# Anatomical study of the posterior cruciate ligament with the knee flexed at 90°<sup>☆,☆☆</sup>



Daniel Kyubin Cho, Sthéphano Pellizzaro Rosa, Guilherme Bello Prestes, Luiz Antônio Munhoz da Cunha, Márcio Fernando Aparecido de Moura, Edmar Stieven Filho\*

Universidade Federal do Paraná (UFPR), Curitiba, PR, Brazil

## ARTICLE INFO

## Article history:

Received 15 July 2013

Accepted 20 August 2013

Available online 27 August 2014

## Keywords:

Posterior cruciate ligament

Anatomy

Cadaver

## ABSTRACT

**Objective:** To study the anatomy of the posterior cruciate ligament (PCL) and define anatomical parameters with the knee flexed at 90°.

**Methods:** Eight knees from cadavers were dissected in order to make measurements from the center of the anterolateral band to the roof (AL1), from the center of the anterolateral band to the anterior cartilage (AL2), from the center of the posteromedial band to the roof (PM1), from the center of the posteromedial band to the anterior cartilage (PM2), from the center of the tibial insertion to the medial region of the tibia (TIM), from the center of the tibial insertion to the lateral region of the tibia (TIL), from the center of the medial insertion to the medial meniscus (IMM) and the width of the origin of the PCL (WO). To obtain the results from each anatomical structure, the means and standard deviations of the measurements were calculated.

**Results:** The measurements in millimeters that were found were AL1, 6.2; AL2, 4.9; PM1, 11.7; PM2, 5.5; TIM, 32.5; TIL, 40.6; IMM, 9.4; and WO, 32.5.

**Conclusions:** The PCL has an extensive origin. The center of the anterolateral band is 6 mm from the roof and 5 mm from the anterior cartilage of the knee. The tibial insertion is slightly medial and 10 mm distal to the posterior cornu of the medial meniscus.

© 2014 Sociedade Brasileira de Ortopedia e Traumatologia. Published by Elsevier Editora Ltda. All rights reserved.

## Estudo anatômico do ligamento cruzado posterior com o joelho em 90° de flexão

## RESUMO

**Objetivo:** Estudar a anatomia do ligamento cruzado posterior (LCP) e definir parâmetros anatômicos com o joelho em 90° de flexão.

## Palavras-chave:

Ligamento cruzado posterior

<sup>☆</sup> Please cite this article as: Cho DK, Rosa SP, Prestes GB, da Cunha LAM, de Moura MFA, Stieven Filho E. Estudo anatômico do ligamento cruzado posterior com o joelho em 90° de flexão. Rev Bras Ortop. 2014;49(5):494-8.

<sup>☆☆</sup> Work developed in the Biological Sciences Sector, Universidade Federal do Paraná (UFPR), Curitiba, PR, Brazil.

\* Corresponding author.

E-mail: [edmar.filho@ufpr.br](mailto:edmar.filho@ufpr.br), [filho2000@gmail.com](mailto:filho2000@gmail.com) (E. Stieven Filho).

<http://dx.doi.org/10.1016/j.rboe.2014.08.003>

2255-4971/© 2014 Sociedade Brasileira de Ortopedia e Traumatologia. Published by Elsevier Editora Ltda. All rights reserved.

Anatomia  
Cadáver

**Métodos:** Oito joelhos de cadáveres foram dissecados para tirar as medidas do centro da banda anterolateral ao teto (AL1), do centro da banda anterolateral à cartilagem anterior (AL2), do centro da banda posteromedial ao teto (PM1), do centro da banda posteromedial à cartilagem anterior (PM2), do centro da inserção tibial à região medial da tibia (ITM), do centro da inserção tibial à região lateral da tibia (ITL), do centro da inserção medial ao menisco medial (IMM) e da largura da origem do LCP (LO). Para a obtenção dos resultados de cada estrutura anatômica foram calculados os valores de média e desvio padrão das medições.

**Resultados:** As medidas, em milímetros, encontradas foram AL1, 6,2; AL2, 4,9; PM1, 11,7; PM2, 5,5; ITM, 32,5; ITL, 40,6; IMM, 9,4; e LO, 32,5.

**Conclusões:** O LCP tem uma origem extensa. O centro da banda anterolateral fica a 6 mm do teto e a 5 mm da cartilagem anterior do joelho. A inserção tibial fica levemente medial e 10 mm distal ao corno posterior do menisco medial.

© 2014 Sociedade Brasileira de Ortopedia e Traumatologia. Publicado por Elsevier Editora Ltda. Todos os direitos reservados.

## Introduction

The posterior cruciate ligament (PCL) is one of the static stabilizers of the knee. It provides primary restraint in relation to posterior displacement of the tibia and secondary restraint in relation to varus, valgus and external rotation.<sup>1</sup>

Controversy continues regarding the treatment for PCL injuries.<sup>2</sup> There is insufficient data in the literature to be able to standardize the indication.<sup>3</sup> Some authors have recommended reconstruction of the PCL in patients with more than 10 mm of posterior displacement who present complaints of pain and instability and who do not improve with conservative treatment.<sup>2,4</sup> This recommendation is based on the fact that 75% of the results from PCL reconstruction are good.<sup>5</sup>

No technique presenting precision and reproducibility for guiding tunnel positioning in PCL reconstruction has yet been developed. This may be because most studies have been conducted with the knee in the anatomical position (extension), whereas the surgical procedure is performed with the knee flexed.<sup>6-8</sup> The aim of this study was analyze the anatomy of the PCL and define objective anatomical parameters with the knee flexed at 90°.

## Materials and methods

Eight knees from cadavers were dissected with the aim of studying the anatomy and making measurements on the structures and anatomical relationships of the PCL.

As an inclusion criterion, we selected knees from cadavers with intact knee structures, including the joint capsule, without any previous arthrotomy. All the knees had been conserved in formol.

To make measurements, 40 × 12 needles were used to mark out specific points and then an Aero Space® metal pachymeter (150 mm) was used.

The following measurements were made:

- center of the anterolateral band to the roof (Fig. 1);
- center of the anterolateral band to the anterior cartilage (Fig. 1);

- center of the posteromedial band to the roof (Fig. 1);
- center of the posteromedial band to the anterior cartilage (Fig. 1);
- center of the tibial insertion to the medial region of the tibia (Fig. 2);
- center of the tibial insertion to the lateral region of the tibia (Fig. 2);
- center of the medial insertion to the medial meniscus (Fig. 2);
- width of the origin of the PCL (Fig. 3).

One of the measurements was the width of the origin of the PCL. This was measured with the aid of a colored string, which was laid along the entire length of the ligament (Fig. 3).

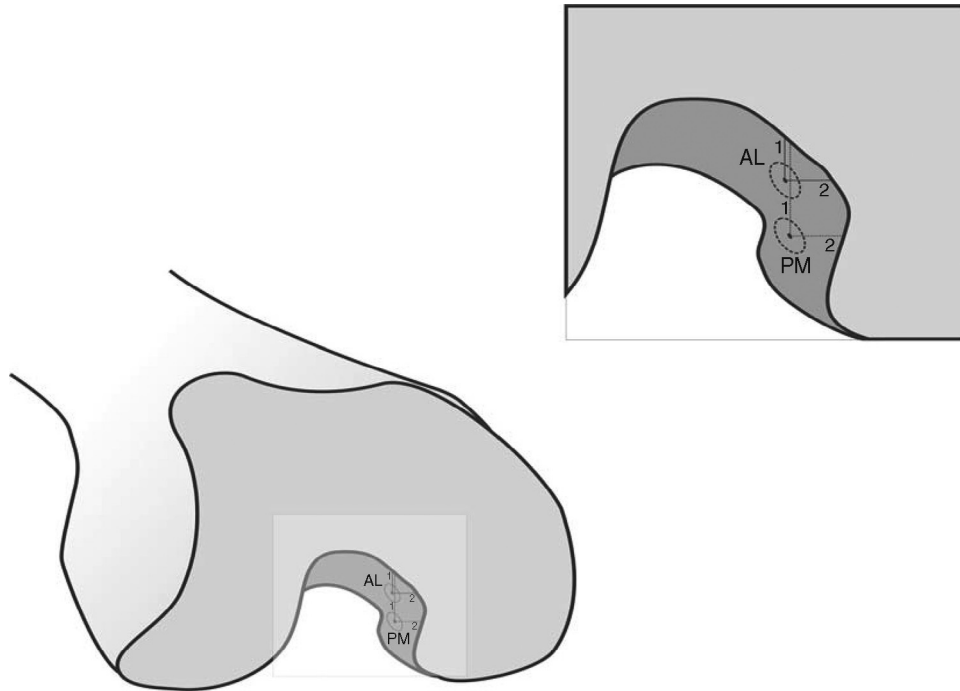
## Results

The means and standard deviations (SD) resulting from the measurements on the PCL at the femoral origin and tibial insertion are presented in Tables 1 and 2.

## Discussion

Most studies have measured the cruciate ligaments in the anatomical position, i.e. with the knee extended. These measurements have been based on the sagittal view, with removal of the femoral condyle.<sup>8</sup> In the present study, the anatomical measurements were made with the knee flexed at 90°, with the intention of increasing the applicability of the study to arthroscopic procedures.<sup>6</sup> Even with similar measurements, the results may show discrepancies if obtained in different manners.<sup>7,8</sup>

The PCL originates from a large area of the medial femoral condyle and is inserted in a depression between the tibial plateaus called the fossa of the PCL.<sup>1</sup> It is slightly medial to the imaginary axis of knee rotation.<sup>9</sup> The results from anatomical studies on the tibial insertion of the PCL corroborate this affirmation. Lorenz et al.<sup>10</sup> found the center of the tibial insertion 45 mm from the lateral edge of the tibial plateau and 43 mm from the medial edge. The results from the present



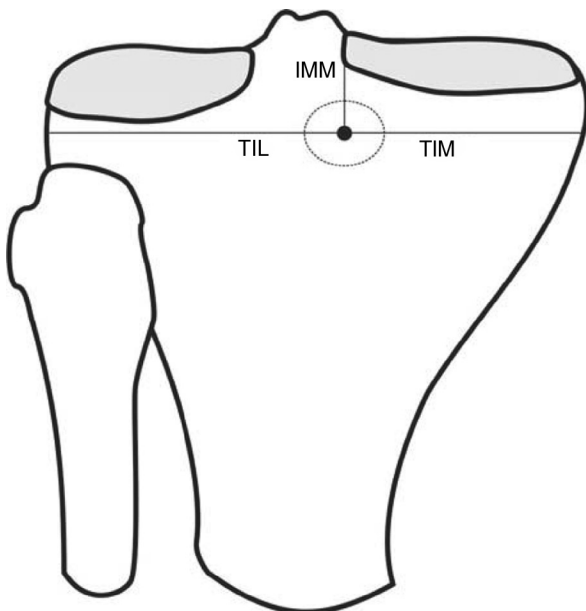
**Fig. 1 – Measurements from the femoral origin of the posterior cruciate ligament. AL1: center of the anterolateral band to the roof; AL2: center of the anterolateral band to the anterior cartilage; PM1: center of the posteromedial band to the roof; PM2: center of the posteromedial band to the anterior cartilage.**

study demonstrated an even more medial position, with the center of the PCL in the tibia at 40.6 mm from the lateral edge and 32.5 mm from the medial edge.

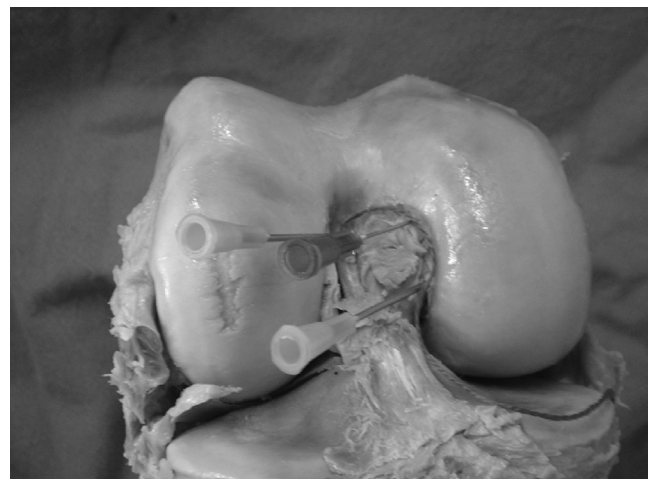
Girgis et al.<sup>11</sup> evaluated the length of the femoral origin of the PCL and arrived at a value of 32 mm. They made the

measurement as a straight line between the two furthest extremities and neglected its oval format. In the present study, the measurement was made in a similar manner, but the half-circumference was evaluated and a value of 28.6 mm was obtained.

The great extent of the origin means that the fibers of the PCL behave differently according to the degree of knee flexion. Thus, there will always be some fibers under tension, independent of the position of the knee. This phenomenon was analyzed back in the 1970s, but in a description of the PCL as a single structure.<sup>11</sup> Studies conducted more recently have separated the PCL into two bands: the anterolateral band



**Fig. 2 – Measurements from the femoral origin of the posterior cruciate ligament. TIL: center of the tibial insertion to the lateral region of the tibia; TIM: center of the tibial insertion to the medial region of the tibia; IMM: center of the medial insertion to the medial meniscus.**



**Fig. 3 – Measurement of the width of the origin of the posterior cruciate ligament, using colored string.**

**Table 1 – Means and standard deviations (SD) of the PCL measurements at the femoral origin.**

Values	WO	AL1	AL2	PM1	PM2
Mean	28.6	6.2	4.9	11.7	5.5
SD	1.7	1.2	1.1	2	1.2

WO, width at origin; AL1, center of the anterolateral band to the roof; AL2, center of the anterolateral band to the anterior cartilage; PM1, center of the posteromedial band to the roof; PM2, center of the posteromedial band to the anterior cartilage.

remains tense during flexion and the posteromedial, during extension.<sup>12</sup>

The oval origin measuring 30 mm makes reproduction in surgical procedures difficult. One of the proposals for coming closer to the original anatomy has been to perform the reconstruction as a double band. Nonetheless, although double bands demonstrate greater in vitro stability, clinical studies have not demonstrated any advantages in comparison with single bands.<sup>8</sup> Even some biomechanical studies have not found any difference between the two techniques, especially in clinical analyses.<sup>13</sup>

There were five studies in the literature, in which the methodology enabled comparisons with some of the results from the present study. The distance from the center of the anterolateral band to the roof was found to range from 13 to 4.8 mm. In the present study, this distance was 6.2. The distance from the posteromedial band to the roof ranged from 20 to 11.4 mm. In the present study, it was 11.7.<sup>8,14-16</sup> Differences of this type between studies are common, because they are absolute measurements and are influenced by the evaluator, the sample and the material used for collection.

Regarding the measurements from the center of the bands to the anterior cartilage, there was a discrepancy in relation to the data found in the literature. The distance from the anterolateral band to the anterior cartilage ranged from 13 to 7 mm. In the present study, this distance was 4.9. For the posteromedial band, the range was from 10.6 to 8 mm. The value found was 5.5.<sup>8,14-16</sup> One possibility for this difference, in addition to those put forward in the above paragraph, was undervaluation of Hamphey's ligament.

The arthroscopic reference points for determining the position of the PCL are a source of confusion in the literature. One of the methods used has been a clock-face method. However, studies have shown that there is imprecision in reproducing this technique. In some cases, differences of more than one hour were found in the evaluations between observers.<sup>17,18</sup>

**Table 2 – Means and standard deviations (SD) of the PCL measurements at the tibial insertion.**

Values	TIM	TIL	IMM
Mean	32.5	40.6	9.4
SD	3.5	4.4	2.3

TIM, center of the tibial insertion to the medial region of the tibia; TIL, center of the tibial insertion to the lateral region of the tibia; IMM, center of the medial insertion to the medial meniscus.

Another method used consists of a tabulated guide. This is useful for guiding the tunnels on lateral images. This method standardizes the individualization of the bands and their positions in relation to the size of the knee. This method should perhaps be the standard for navigated surgery, since it is mathematically more precise. On the other hand, for application to conventional arthroscopic surgery, it is very limited.<sup>18</sup>

Even with all these parameters, some decisions regarding the positioning of the tunnel during the surgery, in relation to both the joint face and the tunnel direction, are dependent on the surgeon's subjective choices and the particular features of the case operated.

## Conclusions

The PCL has an extensive origin. The center of the anterolateral band is 6 mm from the roof and 5 mm from the anterior cartilage of the knee. The tibial insertion is slightly medial and 10 mm distal to the posterior cornu of the medial meniscus.

## Conflicts of interest

The authors declare no conflicts of interest.

## REFERENCES

1. Fanelli GC, Beck JD, Edson CJ. Current concepts review: the posterior cruciate ligament. *J Knee Surg.* 2010;23(2):61-72.
2. Montgomery SR, Johnson JS, McAllister DR, Petrigliano FA. Surgical management of PCL injuries: indications, techniques, and outcomes. *Curr Rev Musculoskelet Med.* 2013;6(2):115-23.
3. Peccin MS, Almeida GJM, Amaro J, Cohen M, Soares BGO, Atallah AN. Interventions for treating posterior cruciate ligament injuries of the knee in adults. *Cochrane Database Syst Rev.* 2005;18(2):CD002939.
4. Camargo OPA, Chamecki A. Lesão do ligamento cruzado posterior: incidência e tratamento. *Rev Bras Ortop.* 1996;31(6):491-6.
5. Kim YM, Lee CA, Matava MJ. Clinical results of arthroscopic single-bundle transtibial posterior cruciate ligament reconstruction: a systematic review. *Am J Sports Med.* 2011;39(2):425-34.
6. Stieven-Filho E, Garschagen ET, Namba M, Silva JLV, Malafaia O, Cunha LAM. Estudo anatômico das duas bandas do ligamento cruzado anterior com o joelho em 90° de flexão. *Rev Col Bras Cir.* 2011;38(5):338-42.
7. Johannsen AM, Anderson CJ, Wijdicks C, Engebretsen L, LaPrade RF. Radiographic landmarks for tunnel positioning in posterior cruciate ligament reconstructions. *Am J Sports Med.* 2013;41(1):35-42.
8. Anderson CJ, Ziegler CG, Wijdicks CA, Engebretsen L, LaPrade RF. Arthroscopically pertinent anatomy of the anterolateral and posteromedial bundles of the posterior cruciate ligament. *J Bone Joint Surg Am.* 2012;94(21):1936-45.
9. Cury RPL, Severino NR, Camargo OPA, Aihara T, Batista Neto LV, Goarayeb DN. Estudo anatômico da inserção femoral do ligamento cruzado posterior. *Rev Bras Ortop.* 2011;46(5):591-5.
10. Lorenz S, Elser F, Brucker PU, Obst T, Imhoff AB. Radiological evaluation of the anterolateral and posteromedial bundle insertion sites of the posterior cruciate ligament. *Knee Surg Sports Traumatol Arthrosc.* 2009;17(6):683-90.

11. Girgis FG, Marshall JL, Monajem A. The cruciate ligaments of the knee joint. Anatomical, functional and experimental analysis. *Clin Orthop Relat Res.* 1975;(106):216-31.
12. Amis AA, Gupte CM, Bull MJ, Edwards A. Anatomy of the posterior cruciate ligament and the meniscomfemoral ligaments. *Knee Surg Sports Traumatol Arthrosc.* 2006;14(3):257-63.
13. Bergfeld JA, Graham SM, Parker RD, Valdevit ADC, Kambic HE. A biomechanical comparison of posterior cruciate ligament reconstructions using single- and double-bundle tibial inlay techniques. *Am J Sports Med.* 2005;33(7):976-81.
14. Lopes OV, Ferretti M, Shen W, Ekdhahl M, Smolinski P, Fu FH. Topography of the femoral attachment of the posterior cruciate ligament. *J Bone Joint Surg Am.* 2008;90(2):249-55.
15. Takahashi M, Matsubara T, Doi M, Suzuki D, Nagano A. Anatomical study of the femoral and tibial insertions of the anterolateral and posteromedial bundles of human posterior cruciate ligament. *Knee Surg Sports Traumatol Arthrosc.* 2006;14(11):1055-9.
16. Morgan CD, Kalman VR, Grawl DM. The anatomic origin of the posterior cruciate ligament: where is it? Reference landmarks for PCL reconstruction. *Arthroscopy.* 1997;13(3):325-31.
17. Apsingi S, Bull AM, Deehan DJ, Amis AA. Review: femoral tunnel placement for PCL reconstruction in relation to the PCL fibre bundle attachments. *Knee Surg Sports Traumatol Arthrosc.* 2009;17(6):652-9.
18. Edwards A, Bull AM, Amis AA. The attachments of the fiber bundles of the posterior cruciate ligament: an anatomic study. *Arthroscopy.* 2007;23(3):284-90.