

Available online at [www.sciencedirect.com](http://www.sciencedirect.com)

ScienceDirect

journal homepage: [www.elsevier.com/locate/radcr](http://www.elsevier.com/locate/radcr)

## Case Report

# Complication detection in MRI guided cardiac ablation: Atrial wall damage and hepatic oedema <sup>☆</sup>

Armando Fusco<sup>a</sup>, Alessandra Luciano<sup>a</sup>, Matteo Cesareni<sup>a,\*</sup>, Ermenegildo De Ruvo<sup>b</sup>, Alessio Borrelli<sup>c</sup>, Giuseppe Tufaro<sup>d</sup>, Alessandro Maria Ferrazza<sup>a</sup>, Marcello Chiochi<sup>e</sup>, Leonardo Calò<sup>b</sup>, Matteo Stefanini<sup>a</sup>

<sup>a</sup> Policlinico Casilino, Department of diagnostic imaging and Interventional Radiology, Rome, Italy

<sup>b</sup> Policlinico Casilino, Department of Cardiology, Rome, Italy

<sup>c</sup> San Carlo di Nancy Hospital, Department of Cardiology, Rome, Italy

<sup>d</sup> Policlinico Casilino, Department of Anesthesiology, Rome, Italy

<sup>e</sup> University of Tor Vergata, Department of diagnostic imaging and Interventional Radiology, Rome, Italy

## ARTICLE INFO

## Article history:

Received 27 December 2023

Revised 16 May 2024

Accepted 18 May 2024

## Keywords:

MRI guided cardiac ablation  
Cavo-tricuspid isthmus ablation  
Cardiac MRI  
Procedural complications  
Atrial damage  
Atrial fibrillation treatment

## ABSTRACT

Magnetic resonance imaging is a novel imaging technique for guiding electrophysiology based ablation operations for atrial flutter and typical atrial fibrillation. When compared to standard electrophysiology ablation, this innovative method allows for better outcomes. Intra-procedural imaging is important for following the catheter in real time throughout the ablation operation while also seeing cardiac architecture and determining whether the ablation is being completed appropriately utilizing oedema sequences. At the same time, intra-procedural imaging allows immediate visualization of any complications of the procedure. We describe a case of a 67 year old male underwent an isthmus-cavo-tricuspid magnetic resonance-guided thermoablation procedure for atrial flutter episodes. During the procedure we noted an atypical focal thinning of the right atrial wall at the isthmus cavo-tricuspidal zone. The post-procedural Black Blood T2 STIR showed an area of hyperintensity at the hepatic dome and glissonian capsule, which was consistent with intraparenchymal hepatic oedema, in close proximity to the atrial finding. Given the opportunity to direct monitoring of adjacent tissues, we aim to highlight with our case the ability of magnetic resonance-guided cardiac ablation to immediately detect peri-procedural complications in the ablative treatment of atrial fibrillation.

© 2024 The Authors. Published by Elsevier Inc. on behalf of University of Washington.

This is an open access article under the CC BY-NC-ND license

(<http://creativecommons.org/licenses/by-nc-nd/4.0/>)

<sup>☆</sup> Competing Interests: The authors declare that they have no known competing financial interests or personal relationships that could have appeared to influence the work reported in this paper.

\* Corresponding author.

E-mail address: [matteo.cesareni@hotmail.com](mailto:matteo.cesareni@hotmail.com) (M. Cesareni).

<https://doi.org/10.1016/j.radcr.2024.05.046>

1930-0433/© 2024 The Authors. Published by Elsevier Inc. on behalf of University of Washington. This is an open access article under the CC BY-NC-ND license (<http://creativecommons.org/licenses/by-nc-nd/4.0/>)

## Introduction

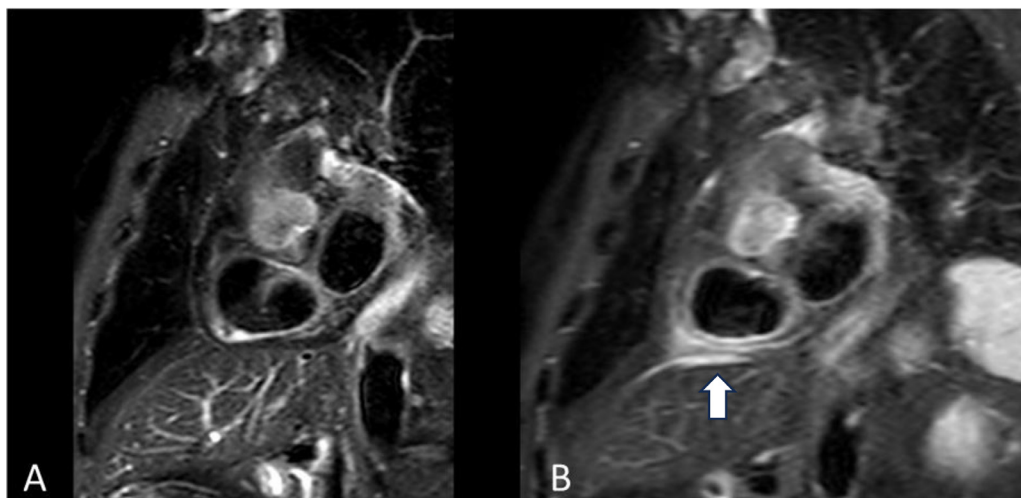
Atrial fibrillation (AF) and atrial flutter catheter ablation is a well-known technique for preventing AF recurrences [1,2]. When performed by adequately educated operators, AF catheter ablation is a safe and preferable alternative to antiarrhythmic drug for sinus rhythm maintenance and symptom relief [3]. Although electrogram characteristics along with pacing techniques are and will continue to be the foundation of electrophysiology, they have limits in terms of substrate identification. Magnetic resonance (MR) guiding of electrophysiological treatments is gaining ground in the ablative treatment of atrial fibrillation thanks to its ability to reduce radiation exposure while improving catheter navigation to anatomic areas such as the pyramidal space, left ventricular peak, and papillary muscles [4–6]. Real-time MR allows direct monitoring of adjacent tissues such the esophagus, pericardium, and coronary vasculature, providing real-time feedback to lessen the risk of complications and when they occurred to recognize them instantly [7].

## Case report

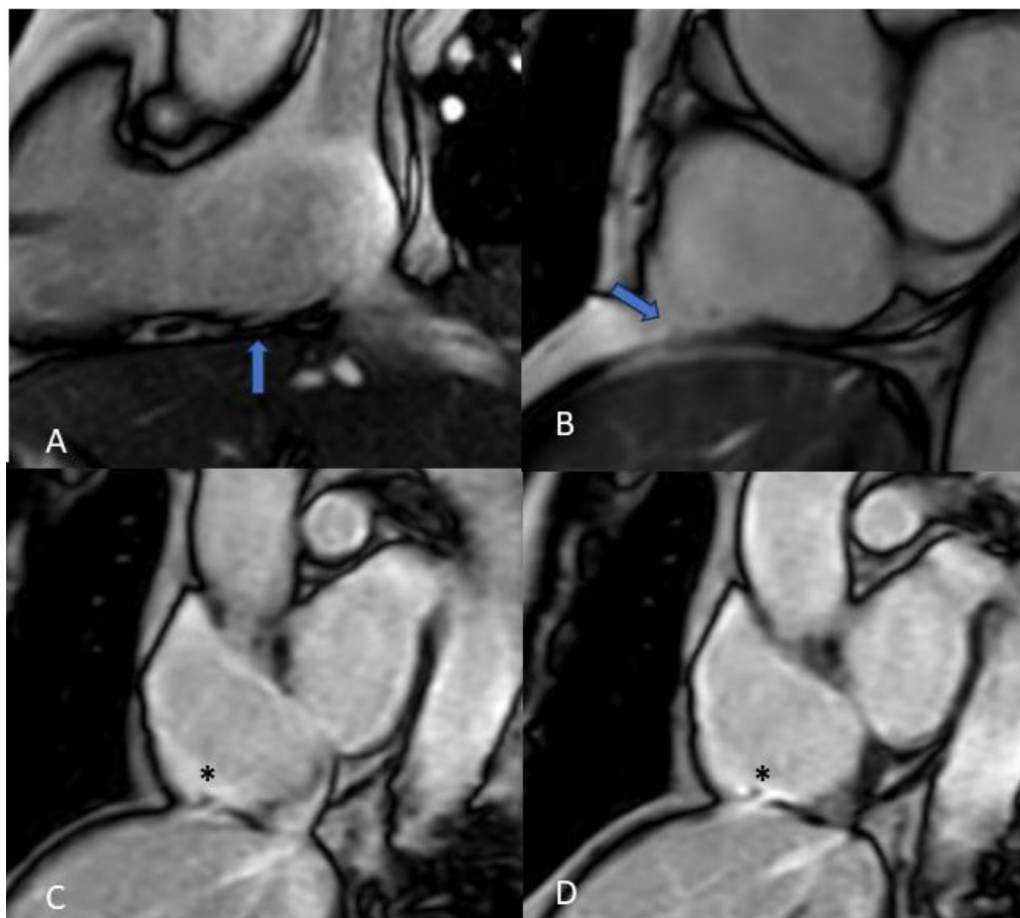
A 67-year-old man, hypertensive, hypercholesterolaemic, ex-smoker, and with a previous transient ischemic attack (2006) came to our attention for a history of persistent long-standing atrial fibrillation, first treated with Coumadin and then with Eliquis. In July 2017, the patient underwent electrical cardioversion after a transesophageal echocardiogram. Since January 2018, the patient complained of sporadic episodes of heart palpitation lasting >24 hours. Holter electrocardiogram performed in January 2018 documented absence of AF phases. In July 2018 the patient performed new emergency room access for episode of persistent AF (120bpm) cardioverted with endovenous flecainide. In relation to the onset of a further

episode of heart palpitation lasting >6 hours in the following days, flecainide therapy was increased by the treating physician to 1 cp x 2. In December 2018 the patient underwent pulmonary vein isolation; however, in July 2019 after a recurrence, he underwent an additional cavotricuspid ablation procedure. The patient reported no episode of heart palpitation, dyspnea, and angina until February 2021 when he re-entered the emergency department for an episode of electrically cardioverted atrial flutter. The attending physician replaced flecainide therapy with sotalol 8mg 1/2 cp x2. The patient reported multiple, although not rapid, recurrences of atrial flutter and was scheduled for MR-guided isthmus-cavo-tricuspid (CTI) ablation in September 2022. The following ablation settings were used: temperature limit 41°C; power limit 65 W; irrigation flow 17mL/min. At the end of the procedure Black Blood T2 short tau inversion recovery (STIR) sequence oriented along the short axis bi-atrial plane show the presence of intramural edema compatible with normal tissue reaction to ablation treatment (Fig. 1A). The post-procedural steady state free precession (SSFP) cine sequences, performed to evaluate right atrial wall motion, showed the presence of anomalous focal thinning of the right atrial wall at the isthmus cava-tricuspidal zone with suspected atrial wall discontinuity (Figs. 2A and B), in the absence of pericardial effusions. The post procedural Black Blood T2 STIR showed marked hyperintensity at the hepatic dome and glissonian capsule in contiguity with the atrial finding consistent with intraparenchymal hepatic oedema (Fig. 1B). The post-procedural late gadolinium enhancement (LGE) sequences showed at the isthmus cava-tricuspidal zone an area of signal hypointensity representing focal right atrial wall damage (Figs. 2C and D).

After the procedure, the patient complained of right hypochondrium pain radiating to the ipsilateral shoulder and arm. Hematic tests inherent to liver function showed increased transaminase values, confirming the procedure-induced liver insult. In relation to the MR finding, the patient underwent transthoracic echocardiogram in the following days, which confirmed thinning and irregular appearance



**Fig. 1 – (A)** Pre ablation Black Blood T2 STIR sequence oriented along the short axis bi-atrial plane show normal aspect right atrial wall. **(B)** Post ablation sequences show the presence of intramural edema as a sign of tissue reaction to ablation treatment extended to the diaphragm and hepatic dome (white arrow).



**Fig. 2 – (A and B) SSFB CTI LONG AXIS and SSFP BI-ATRIAL SHORT-AXIS, the post-procedural cine sequences performed to evaluate atrial wall motion and anatomical appearance, showed the presence of anomalous focal thinning of the right atrial wall at the cavo-tricuspid isthmus zone (blue arrows). (C and D) 3D IR TFE BREATH-HOLD BI-ATRIAL SHORT-AXIS the post-procedural LGE sequences showed an area of signal hypointensity representing focal right atrial wall damage with suspect of endocardial wall discontinuity (black asterisks).**

of the atrial wall, with no evidence of pericardial effusion ascribable to atrial perforation.

## Discussion

Catheter ablation procedures for the treatment of AF have become increasingly popular in recent years [8–10]. As these treatments have grown more extensively used, the number of reported problems has progressively climbed.

Actually, cardiac magnetic resonance (CMR)-guided cavotricuspid isthmus ablation for normal atrial flutter is becoming growing in popularity as an alternative to traditional X-ray methods [11]. The ability to visualize the heart in 3D, as well as the real-time interaction between the tip of the ablation catheter and the cardiac structure, allows for confidence in the region to treat and reduce the risk of complications [12].

The ablation system equipment is directly connected to MRI scanners, enabling active catheter tracking and active catheter imaging throughout the ablation procedure. During

cardiac ablation operations in the MR room, CMR offers real-time image guiding of the Vision-MR Catheters. The Vision-MR Catheter tip contains two integrated MR receiving coils (distal coil is 8 mm from catheter tip). MR fields interact with these coils to offer real-time location guidance and confirmation. The radiofrequency (RF) energy collected by the coils is displayed on-screen in real time as two brilliant circles while in the scan plane. The passive tracking approach is a consolidated imaging technique that does not require any specific software and allows visualization of susceptibility artifacts or signal voids caused by catheters and guidewires. For the identification of CTI oedema, T2-weighted STIR oriented in the 2ch right para-atrio-ventricular plane can be obtained immediately after the ablation procedure. The presence of reactive oedema indicates a phlogistic reaction to ablation therapy and serves as an intra-procedural marker for detecting ablation procedure prolongation [13,14]. Simultaneously, intra- and peri-procedural imaging allows us to detect complications associated with thermo-ablation at the onset. At the end of the procedure, SSFP cine sequences can be done to evaluate right atrial wall motion, the presence of intracavitary thrombi,

and ventricular function. Whether the tissue is heated by RF current, ultrasound, or laser photocoagulation, or frozen by cryoablation, the transfer of ablative energy to the left atrium (LA) is linked with a wide range of possible dangers. These destructive energies have the potential to cause unintentional disruption of the atrial wall, myocardial perforation, and collateral injury to the tissues around the LA [13,14]. The esophagus, intrathoracic nerves, bronchi, pulmonary veins (PVs), lung parenchyma, coronary arteries, and the cardiac conduction system are all prone to ablation harm [15–18].

With our case we want to emphasize the ability of AMR to recognize procedural complications instantaneously giving the physician the possibility to well understand the correct energy to use for the ablation procedure and to permit a rapid treatment if it is needed with the goal to achieve the best patient's clinical outcome. In our case the complication, due to excessive tissue heating by radiofrequency, was mild and self-limiting. In other cases the possibility of identifying during the procedure itself a possible inadvertent disruption of the atrial wall, a myocardial perforation or an ablation injury of the esophagus, intrathoracic nerves, bronchi, PVs, lung parenchyma or coronary arteries, could be lifesaving.

## Conclusion

Challenges are unavoidable in any invasive surgery, and while the effectiveness of AF ablation has only steadily improved, significant progress has been made in recognizing and preventing issues. Physicians doing these treatments must be alert for problems and proficient at treating them quickly. CMR guiding of cardiac catheterization operations has become a reality due to the requirement for an imaging modality that provides improved structural delineation of complicated cardiac anatomy, multiplanar imaging, extra physiologic information without the risk of ionizing radiation and with the great advantage of immediately detecting peri-procedural complications.

## Patient consent

The authors declare that this report does not contain any personal information that could lead to the identification of the patient. Informed consent was obtained from the patient.

## REFERENCES

- [1] Ganesan AN, Shipp NJ, Brooks AG, Kuklik P, Lau DH, Lim HS, et al. Long-term outcomes of catheter ablation of atrial fibrillation: a systematic review and meta-analysis. *J Am Heart Assoc* 2013;2:e004549.
- [2] Di Biase L, Mohanty P, Mohanty S, Santangeli P, Trivedi C, Lakkireddy D, et al. Ablation versus amiodarone for treatment of persistent atrial fibrillation in patients with congestive heart failure and an implanted device: results from the AATAC multicenter randomized trial. *Circulation* 2016;133:1637–44.
- [3] Jais P, Cauchemez B, Macle L, Daoud E, Khairy P, Subbiah R, et al. Catheter ablation versus antiarrhythmic drugs for atrial fibrillation: the A4 study. *Circulation* 2008;118:2498–505.
- [4] Nazarian S, Bluemke DA, Lardo AC, Zviman MM, Watkins SP, Dickfeld TL, et al. Magnetic resonance assessment of the substrate for inducible ventricular tachycardia in nonischemic cardiomyopathy. *Circulation* 2005;112(18):2821–5. doi:10.1161/CIRCULATIONAHA.105.549659.
- [5] Stefanini M, Simonetti G. Interventional Magnetic Resonance Imaging Suite (IMRIS): how to build and how to use. *Radiol Med* 2022;127(10):1063–7 Epub August 26, 2022. doi:10.1007/s11547-022-01537.
- [6] Chubb H, Harrison JL, Weiss S, Krueger S, Koken P, Bloch LØ, et al. Development, preclinical validation, and clinical translation of a cardiac magnetic resonance - electrophysiology system with active catheter tracking for ablation of cardiac arrhythmia. *JACC Clin Electrophys* 2017;3(2):89–103. doi:10.1016/j.jacep.2016.07.005.
- [7] Bakker CJ, Hoogeveen RM, Weber J, van Vaals JJ, Viergever MA, Mali WP. Visualization of dedicated catheters using fast scanning techniques with potential for MR-guided vascular interventions. *Magn Reson Med* 1996;36:816–20.
- [8] Priori SG, Blomström-Lundqvist C, Mazzanti A, Blom N, Borggrefe M, Camm J, et al. 2015 ESC guidelines for the management of patients with ventricular arrhythmias and the prevention of sudden cardiac death: the task force for the management of patients with ventricular arrhythmias and the prevention of sudden cardiac death of the European Society of Cardiology (ESC). endorsed by: Association for European Paediatric and Congenital Cardiology (AEPC). *Eur Heart J* 2015;36:2793–867.
- [9] Brugada J, Katritsis DG, Arbelo E, Arribas F, Bax JJ, Blomström-Lundqvist C, et al. 2019 ESC guidelines for the management of patients with supraventricular tachycardia. *Eur Heart J* 2020;41:655–720.
- [10] Hindricks G, Potpara T, Dagres N, Arbelo E, Bax JJ, Blomström-Lundqvist C, et al. 2020 ESC guidelines for the diagnosis and management of atrial fibrillation developed in collaboration with the European Association of Cardio-Thoracic Surgery (EACTS): the task force for the diagnosis and management of atrial fibrillation of the European Society of Cardiology (ESC). *Eur Heart J* 2021;42:373–498.
- [11] Rogers T, Lederman RJ. Interventional CMR: clinical applications and future directions. *Curr Cardiol Rep* 2015;17:31.
- [12] Rogers T, Ratnayaka K, Karmarkar P, Campbell-Washburn AE, Schenke WH, Mazal JR, et al. Real-time magnetic resonance imaging guidance improves the diagnostic yield of endomyocardial biopsy. *JACC Basic Transl Sci* 2016;1:376–83.
- [13] Nazarian S, Bluemke DA, Lardo AC, Zviman MM, Watkins SP, Dickfeld TL, et al. Magnetic resonance assessment of the substrate for inducible ventricular tachycardia in nonischemic cardiomyopathy. *Circulation* 2005;112:2821–5.
- [14] Ashikaga H, Arevalo H, Vadakkumpadan F, Blake RC 3rd, Bayer JD, Nazarian S, et al. Feasibility of image-based simulation to estimate ablation target in human ventricular arrhythmia. *Heart Rhythm* 2013;10:1109–16.
- [15] Redfeam DP, Trim GM, Skanes AC, Petrellis B, Krahn AD, Yee R, et al. Esophageal temperature monitoring during radiofrequency ablation of atrial fibrillation. *J Cardiovasc Electrophysiol* 2005;16:589–93.
- [16] Kenigsberg DN, Wood MA, Alaeddini J, Ellenbogen KA. Cryoablation inside the pulmonary vein after failure of radiofrequency antral isolation. *Heart Rhythm* 2007;4:992–6.

- 
- [17] Shah D, Dumonceau JM, Burri H, Sunthorn H, Schroft A, Gentil-Baron P, et al. Acute pyloric spasm and gastric hypomotility: an extracardiac adverse effect of percutaneous radiofrequency ablation for atrial fibrillation. *J Am Coll Cardiol* 2005;46:327–30.
- [18] De Zan G, Calò L, Borrelli A, Guglielmo M, De Ruvo E, Rier S, et al. Cardiac magnetic resonance-guided cardiac ablation: a case series of an early experience. *Eur Heart J Supplements* 2023;25(Suppl C):C265–70. doi:[10.1093/eurheartjsupp/suad051](https://doi.org/10.1093/eurheartjsupp/suad051).