


Thymoangioliopoma: A rare histologic variant of thymolipoma in a patient with myasthenia gravis

Rare Tumors
Volume 12: 1–4
© The Author(s) 2020
Article reuse guidelines:
sagepub.com/journals-permissions
DOI: 10.1177/2036361320979215
journals.sagepub.com/home/rtu


Mohammad Hossein Anbardar¹ , Fatemeh Amirmoezi²
and Armin Amirian³

Abstract

Thymoangioliopoma is a rare, slow-growing, benign thymic neoplasm that arises from the anterior mediastinum. A 61-year-old man with the chief complaint of right eye ptosis and high serum acetylcholine receptor antibody level is presented here. The spiral computed tomography of the chest revealed a hypodense mass in the anterior mediastinum. Microscopic examination showed admixture of adipose tissue, thymic tissue and blood vessels with the diagnosis of thymoangioliopoma. Thymoangioliopoma is a rare histologic variant of thymolipoma which can be associated with myasthenia gravis and must be considered as a differential diagnosis in anterior mediastinal mass with fat density in radiologic evaluation.

Keywords

Thymus, thymolipoma, thymoangioliopoma, mediastinum, histopathology

Date received: 27 August 2020; accepted: 17 November 2020

Introduction

Thymolipoma is a rare benign tumor that originates from the anterior mediastinum and corresponds to 2% to 9% of all thymic neoplasms. Histologically, they are comprised of mature adipose tissue and thymic tissue in variable proportions. The term thymolipoma was introduced in 1948 by Hall to characterize this tumor.^{1–4} Thymoangioliopoma is a histologic variant of thymolipoma. Previously, only one case of thymohemangioliopoma was reported in English articles by Ogino et al.⁵

To the best of our knowledge, this is the second one. Our case is the first report in patients with myasthenia gravis. In this paper, we present a case of thymoangioliopoma presented in a patient with myasthenia gravis and review the literature.

Case report

A 61-year-old man was admitted to our hospital with the chief complaint of right eye ptosis presenting about 3 weeks

prior to admission. The ptosis was fluctuated during day and worsened in the afternoon. He did not experience dysphagia, muscle weakness or other symptoms. The patient had no significant past medical history or any drug consumption. Moreover, his family history was negative for any neurologic or rheumatologic diseases. On admission, vital signs were stable. On physical examination, there was no other neurologic problem. No ophthalmologic and vision problem was detected. The differential diagnoses of

¹Department of Pathology, Shiraz Medical School, Shiraz University of Medical Sciences, Shiraz, Iran

²Student Research Committee, Department of Pathology, Shiraz Medical School, Shiraz University of Medical Sciences, Shiraz, Iran

³Department of Surgery, Shiraz Medical School, Shiraz University of Medical Sciences, Shiraz, Iran

Corresponding author:

Mohammad Hossein Anbardar, Department of Pathology, Shiraz Medical School, Shiraz University of Medical Sciences, Shiraz 7134845794, Iran.
Email: anbardarm@sums.ac.ir



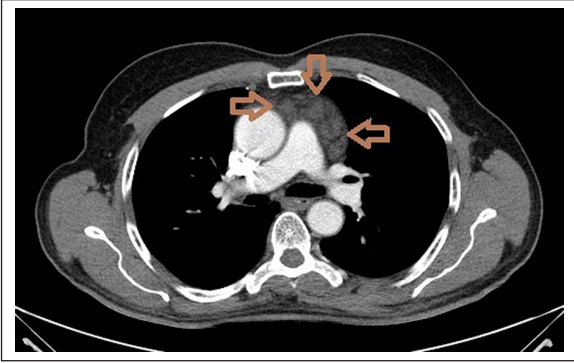


Figure 1. Computed tomography scan showing a hypodense tumor (arrow) in the anterior mediastinum.

ptosis, including mechanical, aponeurotic, myogenic, neurogenic, and neuromuscular disorders, were evaluated with clinical and para-clinical work ups. All routine laboratory tests were in normal ranges. The serum acetylcholine receptor antibody level was >16 nmol/L (normal <0.40); thus, myasthenia gravis was diagnosed. Ptosis was improved after treatment with prednisolone 10 mg/day, pyridostigmine bromide 120 mg/day and azathioprine 50 mg/day. The spiral computed tomography of the chest and mediastinum revealed a hypodense lesion measuring about 6×3 cm in the anterior mediastinum without invasion to adjacent structures (Figure 1). Because of anatomical location and fat density of the lesion, radiologically the mass was diagnosed as thymoma. The patient was admitted in hospital for plasmapheresis and thymectomy. After two sessions of plasmapheresis, sternotomy and thymectomy were performed. Gross examination of the mass showed well defined soft mass measuring $8 \times 7 \times 3$ cm and weighing 150 g; the cut sections revealed lobulated yellow-red soft surface with hemorrhagic foci (Figure 2). Microscopic examination showed admixture of adipose tissue, thymic tissue and blood vessels with the diagnosis of thymoangiolipoma (Figure 3(a) and (b)). After the operation, ptosis was relieved and the need to medication was reduced. The dose of prednisolone and azathioprine was decreased to 5 mg and 25 mg per day, respectively. Two years follow up showed no recurrence. A written informed consent was signed by the patient for publishing the case report and the publication of the accompanying images.

Discussion

Thymic neoplasms are rare tumors that account for less than 1% of all adult malignancies. Thymolipoma is a rare, slow-growing, benign thymic neoplasm that originates from the anterior mediastinum. It may happen at any age with no sex predilection. It can be very large in diameter. Most of the cases are asymptomatic, but symptoms such as cough, dyspnea, and chest pain related to tumor mass can

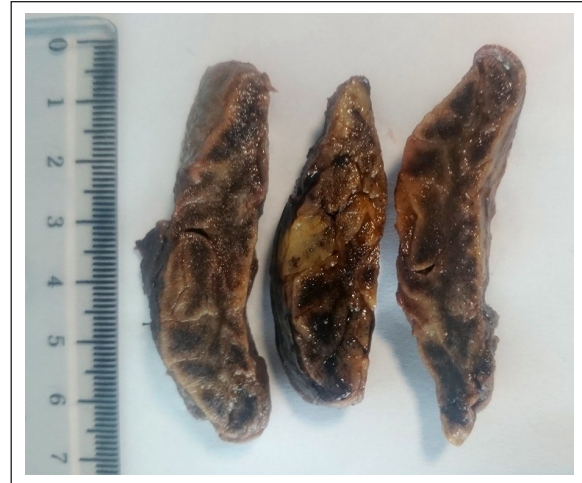

Figure 2. Cut sections of thymic mass with lobulated fatty and hemorrhagic surface in gross examination.

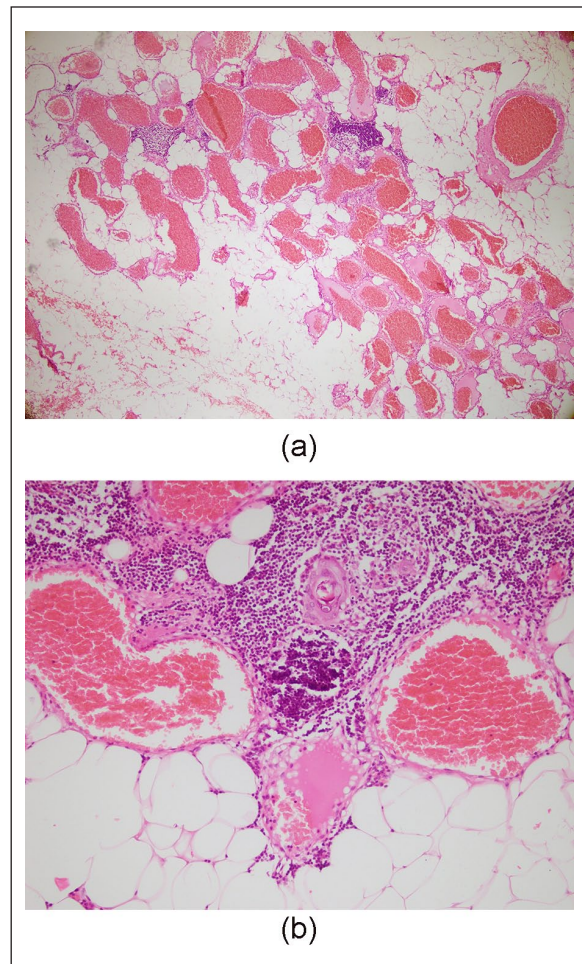


Figure 3. (a) Microscopic section in low power showing a mixture of thymic tissue, fat and large blood vessels. (Hematoxylin and Eosin, $\times 40$), (b) high power view of mass showing Hassall's corpuscles, mature T lymphocytes, adipose tissue and large blood vessels. (Hematoxylin and Eosin, $\times 200$).

be seen.¹⁻⁴ On chest X ray, thymolipomas may appear as a well-defined round or oval anterior mediastinal density resembling pericardial effusion, atelectasis, sequestration, lipoma or cardiomegaly. Computed tomography and magnetic resonance imaging are usually diagnostic.^{6,7}

Histopathologically, thymolipomas are composed of mature fatty tissue admixed with thymic tissue including epithelial islands and aggregates of mature lymphocytes.¹ In addition to classic morphology of thymolipoma, there are rare histologic variants in the literature. Thymofibrolipoma and thymoangioliipoma are the most important ones. There have been three reported cases of thymofibrolipoma and two thymoangioliipomas including our case in the literature.^{5,8,9} Thymofibrolipomas have thick collagen fibers.⁹ Thymoangioliipomas are composed of mature fat, thymic tissue, and blood vessels in different proportions. Most of the vessels are large with thick wall. The endothelial cells are bland looking without atypia.⁵

Histologic differential diagnosis of thymolipoma includes mediastinal lipoma, mediastinal liposarcoma, thymic hyperplasia, teratoma, and regressed thymoma.^{2,7,10} Differentiation between lipoma and thymolipoma can sometimes be difficult. Identification of epithelial thymic cells with thorough sectioning and immunohistochemical markers is helpful for differentiation.¹⁰ Mediastinal lipomas are often very large and located just above the diaphragm. Liposarcoma is a rare pathology in the anterior mediastinum; however, it is reported in this area; the size of the mass, detection of lipoblasts and atypical spindled cells, myxoid degeneration, and amplification of MDM-2 are useful findings to differentiate them from thymolipoma.^{10,11} Thymic hyperplasia is defined as thymic enlargement beyond the upper limits of normal for the age. Presence of abundant adipose tissue, encapsulated mass and peripheral rimming of normal thymus are the findings in favor of thymolipoma against thymic hyperplasia.¹⁰ Mature cystic teratoma is the most common type of mediastinal germ cell tumor. Discrimination of thymolipomas with presence of sebaceous gland and myoid cell from teratomas are challenging, especially in trucut biopsies. Finding other teratomatous components such as cartilage, gastrointestinal, and respiratory epithelium is helpful. Thymomas are the neoplasm of thymic epithelial cells which can become involuted or regressed occasionally. Extensive sclerosis and replacement by adipose tissue are common in regressed thymomas, so differentiation from thymolipomas may be difficult. Thorough sectioning to find neoplastic epithelial cells is important.

Histologic differential diagnosis of thymoangioliipoma includes mediastinal hemangioma, angioliipoma and angio-myoliipoma. Therefore, attention to presence of thymic tissue by thorough sectioning or immunohistochemical markers such as cytokeratin and p63 is advised.^{11,12}

The pathogenesis of thymolipoma is unclear; however, review of the literature reveals three main theories based on

histopathology and clinical findings: (1) Hamartomatous lesion: the haphazard admixture of two different normal components of the thymus in most cases suggests this theory; (2) Neoplastic lesion: thymolipoma is a neoplasm of thymic fat with engulfment of thymic tissue; and (3) Regressed lesion: there are two theories of thymic involution, involuted thymic hyperplasia and involuted thymoma.^{2,4,6,9}

Thymolipoma like other thymic lesions are occasionally associated with paraneoplastic syndromes such as myasthenia gravis, aplastic anemia, Grave's disease and hypogammaglobulinemia. The frequency of myasthenia gravis associated with thymolipoma is between 2.8% and 50%. Several studies showed that thymolipoma in association with myasthenia gravis had a low weight and appeared in older patients. In our case, also the patient was 61 years old and the weight of the mass was low.^{3,4} Our case is the only thymoangioliipoma which is reported in association with myasthenia gravis.

Treatment of thymolipoma is surgical resection. It does not recur after thymectomy and long term follow up is not required. In patients with myasthenia gravis, resection of the thymus can result in gradual improvement of the symptoms.^{3,4} Damadoglu et al. reported significant improvement of myasthenia gravis symptoms in all of their ten patients.⁴ However, Reiker et al. reported improvement in only one of nine cases.³ Overall, in patients with myasthenia gravis, thymectomy is advised to increase the possibility of remission or improvement. In our case, thymectomy also resulted in the relief of symptom and decreased dosage of medication.

Thymoangioliipoma is a rare histologic variant of thymolipoma which can be associated with myasthenia gravis and must be considered as a differential diagnosis in the anterior mediastinal mass with fat density in radiologic evaluation. In patients with myasthenia gravis, thymectomy can result in symptom improvement.

Acknowledgements

The authors would like to thank Shiraz University of Medical Sciences, Shiraz, Iran and also Center for Development of Clinical Research of Nemazee Hospital and Dr. Nasrin Shokrpour for editorial assistance.

Contributorship

Mohammad Hossein Anbardar: conception, acquisition of data, drafting the article; Fatemeh Amirmoezi: acquisition of data, drafting the article; Armin Amirian: acquisition of data

Declaration of conflicting interests

The author(s) declared no potential conflicts of interest with respect to the research, authorship, and/or publication of this article.

Ethical approval

Ethical approval for case reports is not need in our institution.

Funding

The author(s) received no financial support for the research, authorship, and/or publication of this article.

Informed consent

Written informed consent was obtained from the patient for their anonymized information to be published in this article.

ORCID iD

Mohammad Hossein Anbardar  <https://orcid.org/0000-0002-2317-0737>

References

1. Pai RK and Irvine R. Pathologic quiz case: giant mediastinal mass in a 69-year-old man. *Arch Pathol Lab Med* 2004; 128: e159–e160.
2. Hudacko R, Aviv H, Langenfeld J, et al. Thymolipoma: clues to pathogenesis revealed by cytogenetics. *Ann Diagn Pathol* 2009; 13: 185–188.
3. Rieker RJ, Schirmacher P, Schnabel PA, et al. Thymolipoma. A report of nine cases, with emphasis on its association with myasthenia gravis. *Surg Today* 2010; 40: 132–136.
4. Damadoglu E, Salturk C, Takir HB, et al. Mediastinal thymolipoma: an analysis of 10 cases. *Respirology* 2007; 12: 924–927.
5. Ogino S, Franks TJ, Deubner H, et al. Thymohemangioliipoma, a rare histologic variant of thymolipoma: a case report and review of the literature. *Ann of Diagn Pathol* 2000; 4: 236–239.
6. Ajaz B, Tran TA, Truong T, et al. Thymolipoma with sebaceous differentiation: a hitherto unreported variant of thymolipoma. *Int J Surg Pathol* 2013; 21: 526–530.
7. Vaziri M and Rad K. Progressive dyspnea in a 40-year-old man caused by giant mediastinal thymolipoma. *Case Rep Surg* 2016; 2016: 3469395.
8. Moran CA, Zeren H and Koss MN. Thymofibroliipoma. A histologic variant of thymolipoma. *Arch Pathol Lab Med* 1994; 118: 281–282.
9. Kang GH, Han J, Kim TS, et al. Thymofibroliipoma: a brief case report. *Korean J Pathol* 2010; 44: 338–340.
10. Kim YK, Shin N, Park WY, et al. Mediastinal thymolipoma with striated myoid cells: report of a peculiar case. *Korean J Pathol* 2013; 47: 596–598.
11. den Bakker MA, Marx A, Mukai K, et al. Mesenchymal tumours of the mediastinum—part I. *Virchows Arch* 2015; 467: 487–500.
12. Knight CS, Cerfolio RJ and Winokur TS. Angiomyolipoma of the anterior mediastinum. *Ann Diagn Pathol* 2008; 12: 293–295.