

Single Case

# Necrobiotic Xanthogranuloma in a Patient with Multiple Myeloma

Marlies Wruhs Robert Feldmann Isabelle Sawetz Friedrich Breier  
Andreas Steiner

Department of Dermatology, Municipal Hospital Hietzing, Vienna, Austria

## Keywords

Myeloma · Therapy · Xanthogranuloma

## Abstract

An 82-year-old woman presented with a 9-month history of multiple, well-defined skin lesions on her neck and upper chest, progressively increasing in size. Histological examination of a skin biopsy showed a regular epidermis. In the dermis, granulomatous changes with central necrobiosis were found which extended focally into the subcutaneous fat. The necrobiotic areas were surrounded by Touton cells and foreign-body giant cells. Laboratory analysis revealed leucopenia. Serum electrophoresis and immunofixation disclosed the presence of an IgG- $\lambda$  paraprotein. Bone marrow aspiration cytology showed 20% plasmatic cells. The skeletal X-ray revealed frontal and occipital osteolytic skull lesions as well as pubic osteolysis. Urinalysis was unremarkable without proteinuria. Based on the clinical, laboratory, and histological findings, necrobiotic xanthogranuloma in association with multiple myeloma was diagnosed. The patient was treated with bortezomib combined with oral dexamethasone. Follow-up at week 13 revealed the complete disappearance of the IgG paraproteinemia. However, the skin lesions remained unchanged. Therefore, bortezomib treatment was discontinued, and systemic corticosteroids were continued at a higher dosage. After the steroid treatment, the lesions markedly flattened.

© 2016 The Author(s)  
Published by S. Karger AG, Basel

## Case Report

An 82-year-old woman presented with a 9-month history of multiple, well-defined skin lesions on her neck and upper chest, progressively increasing in size. They presented as asymptomatic, reddish-yellowish, indurated nonscaly plaques measuring up to 10 cm in diameter (Fig. 1a). In the center of some lesions, atrophic areas were observed. The patient had no remarkable illness and did not regularly take medication.

Histological examination of a skin biopsy taken from an indurated plaque on the right chest showed a regular epidermis. In the dermis, granulomatous changes with central necrobiosis were found which extended focally into the subcutaneous fat. The necrobiotic areas were surrounded by Touton cells and foreign-body giant cells (Fig. 1b). Immunocytochemistry showed the infiltrate to be largely composed of CD-68-positive macrophages and monocytes (Fig. 1c). Laboratory analysis revealed leucopenia (2.92 g/L) as well as an elevated erythrocyte sedimentation rate (88 mm after 1 h, 100 mm after 2 h). Serum electrophoresis and immunofixation disclosed the presence of an IgG- $\lambda$  paraprotein (IgG 25.31 g/L; normal range 5.52–16.31 g/L). Lyme disease serology was negative. Bone marrow aspiration cytology showed 20% plasma cells. The skeletal X-ray disclosed frontal and occipital osteolytic skull lesions as well as pubic osteolysis. Urinalysis was unremarkable without proteinuria.

Based on the clinical, laboratory, and histological findings, necrobiotic xanthogranuloma (NXG) in association with multiple myeloma was diagnosed. The patient was treated with bortezomib (1.3 mg/m<sup>2</sup> body surface s.c. once a week) for 12 weeks combined with oral dexamethasone (initially 20 mg/day). The dosage of the corticosteroid was progressively reduced during the following weeks.

Follow-up at week 13 revealed the complete disappearance of the IgG paraproteinemia. However, the skin lesions remained unchanged. Therefore, bortezomib treatment was discontinued, and systemic corticosteroids were continued at a higher dosage. The patient received oral dexamethasone (40 mg/day) for 2 weeks, followed by maintenance therapy (4 mg/every other day) during 2 months. After the steroid treatment, the lesions markedly flattened.

## Discussion

We report here a patient whose primarily dermatological concern led us to the diagnosis of multiple myeloma. NXG is very rare and was first described by Kossard and Winkelmann in 1980 [1]. NXG is a disease of adults; the average age of onset is in the sixth decade. In 85% of cases, NXG is located in the periorbital area, and the lesions tend to progress towards the face. The trunk and proximal extremities are other affected sites. Lesions have a red-orange or yellow color and may present telangiectasia, atrophy, and ulceration. Ocular involvement occurs in approximately 50% of cases, including orbital masses, conjunctivitis, keratitis, scleritis, and uveitis. Extracutaneous involvement includes the heart, lungs, kidneys, liver, spleen, intestine, skeletal muscles, and central nervous system. NXG is categorized as non-Langerhans cell histiocytosis, often associated with monoclonal gammopathy (up to 90%). Some patients were reported to have multiple myeloma (10%), lymphoproliferative disorders, and/or atypical plasma cells in bone marrow examination [2, 3].

The link between NXG and paraproteinemia remains unclear. A deposition of immunoglobulins and lipid complexes with monocyte activation and foreign-body giant-cell reaction is suspected [4]. Recently, no treatment modality has been shown consistently effect-

tive. Treatment includes systemic or intralesional corticosteroids, chlorambucil, melphalan, topical mechlorethamine, dapson, intravenous immunoglobulins, and lenalidomide [5–7]. Extracorporeal photopheresis has been used as well as autologous stem cell transplantation [8].

Bortezomib is a proteasome inhibitor and is considered as a major milestone in the treatment of multiple myeloma. In 2008, the US FDA approved bortezomib as a first-line therapy of multiple myeloma [9]. To the best of our knowledge, this is one of the first treatment trials of NXG and multiple myeloma with bortezomib reported in the literature [9]. In our patient, bortezomib combined with low-dose systemic corticosteroids normalized the paraproteinemia but had no effect on the skin lesions. The latter improved after high-dose dexamethasone therapy, as previously reported in the literature [10–12]. This may underline that NXG is a reactive rather than a neoplastic skin disease.

### Statement of Ethics

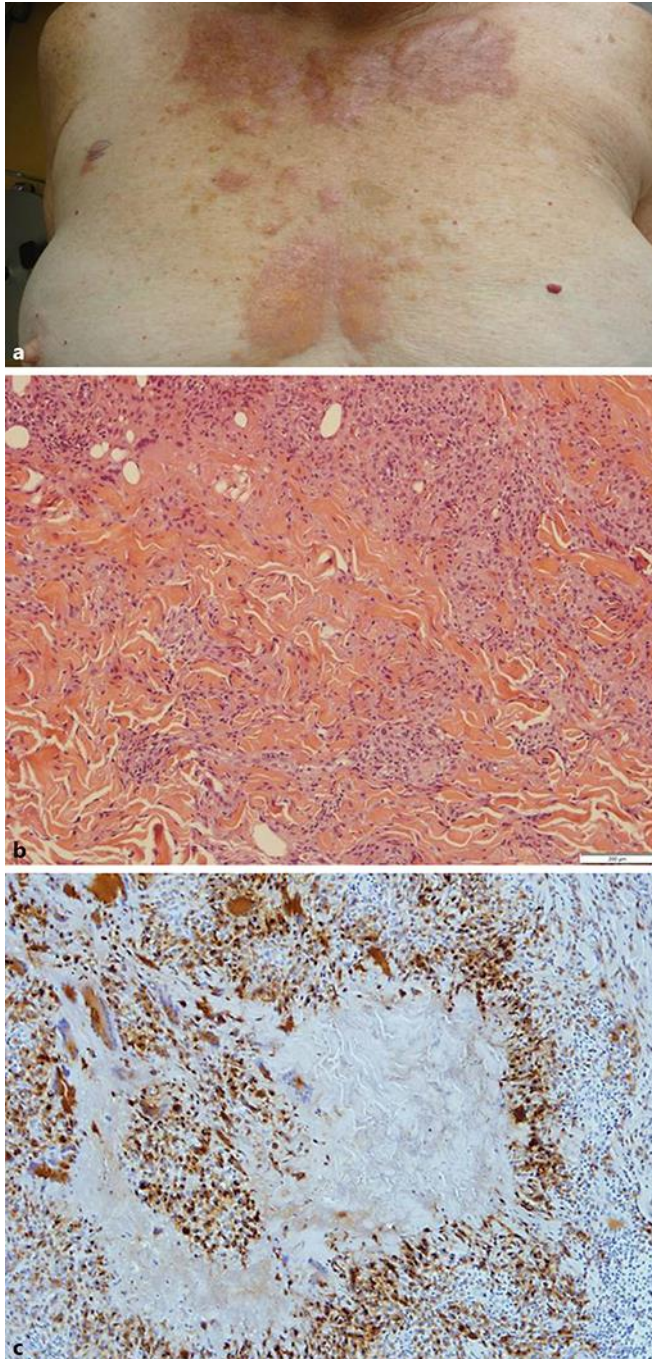
The patient has signed an informed consent for the publication of this case report.

### Disclosure Statement

The authors have no conflicts of interest to declare.

### References

- 1 Kossard S, Winkelmann RK: Necrobiotic xanthogranuloma. *Australas J Dermatol* 1980;21:85–88.
- 2 Hashemi P, Rashidi A, Chapas AM, et al: Necrobiotic xanthogranuloma of the extremities with paraproteinemia and without periorbital involvement at presentation. *Cutis* 2012;89:41–44.
- 3 Bhari N, Chiramel MJ, Vedi KK, et al: Necrobiotic xanthogranuloma with multiple myeloma. *Clin Exp Dermatol* 2015;40:811–814.
- 4 Matura F, et al: Activation of monocytes in vivo causes intracellular accumulation of lipoprotein-derived lipids and marked hypocholesterolaemia: a possible pathogenesis of necrobiotic xanthogranuloma. *Atherosclerosis* 1999;142:355.
- 5 Szalat R, Arnulf B, Karlin L, et al: Pathogenesis and treatment of xanthomatosis associated with monoclonal gammopathy. *Blood* 2011;118:3777–3784.
- 6 Ryan E, Warren LJ, Szabo F: Necrobiotic xanthogranuloma: response to chlorambucil. *Australas J Dermatol* 2012;53:3–5.
- 7 Rodriguez O, Meyers C, Weiss BM, et al: Necrobiotic Xanthogranuloma treated with topical nitrogen mustard (mechlorethamine). *JAMA Dermatol* 2016;13:1–2.
- 8 Liszewski W, Wisniewski JD, Safah H, et al: Treatment of refractory necrobiotic xanthogranulomas with extracorporeal photopheresis and intravenous immunoglobulin. *Dermatol Ther* 2014;27:268–271.
- 9 Xu G, Yang M, Qian W: Long-term disease control in a refractory multiple myeloma patient treated with bortezomib mono-therapy: a case report and review of literature. *Int J Clin Exp Med* 2015;8:19629–19631.
- 10 Flann S, Wain EM, Halpern S, et al: Necrobiotic xanthogranuloma with paraproteinaemia. *Clin Exp Dermatol* 2006;31:248–251.
- 11 Meyer S, Szeimies RM, Landthaler M, et al: Cyclophosphamide-dexamethasone pulsed therapy for treatment of recalcitrant necrobiotic xanthogranuloma with paraproteinemia and ocular involvement. *Br J Dermatol* 2005;153:443–445.
- 12 Chave TA, Chowdhury MM, Holt PJ: Recalcitrant necrobiotic xanthogranuloma responding to pulsed high-dose oral dexamethasone plus maintenance therapy with oral prednisolone. *Br J Dermatol* 2001;144:158–161.



**Fig. 1.** **a** Extensive indurated plaques with central atrophy and yellowish discoloration. **b** Granulomatous infiltrate with necrobiotic areas in the dermis (hematoxylin and eosin, original magnification  $\times 40$ ). **c** Immunocytochemistry: staining positive for CD68.