

## Case Reports

## Pallidal stimulation-induced psychosis and suicidality in Parkinson's disease

Sebastian Hanna<sup>a</sup>, Vala Palmadottir<sup>b</sup>, Paul L. Penar<sup>a,d</sup>, James T. Boyd<sup>a,c</sup>

<sup>a</sup> University of Vermont Larner College of Medicine, United States

<sup>b</sup> Landspítali University Hospital, Iceland

<sup>c</sup> Department of Neurological Sciences, United States

<sup>d</sup> Department of Surgery, Division of Neurosurgery, United States

## A B S T R A C T

Neuropsychiatric adverse events have been previously reported following deep brain stimulation (DBS) for Parkinson's disease (PD). Most cases described have involved DBS of the subthalamic nucleus (STN). We report a unique case of acute-onset and reversible psychosis, suicidality, and depressive symptoms following DBS of the globus pallidus internus (GPi) and review the relevant literature.

### 1. Background

Parkinson's disease (PD) is a neurodegenerative disease characterized by motor-related symptoms that primarily affects older adults [1]. While there is no cure for PD, pharmacologic therapy may treat certain symptoms of the disease. The surgical treatment options for medication-resistant tremor, motor fluctuations, and levodopa-induced dyskinesias include deep brain stimulation (DBS), a care-standard in appropriately selected individuals. DBS modifies the irregular neuronal activity of a region of the brain via chronic delivery of electrical stimulation, with the most common targets for DBS in PD being the subthalamic nucleus (STN) and globus pallidus internus (GPi) [2]. High-frequency stimulation has been associated with a variety of neuropsychiatric adverse effects [3]. Transient and reversible development of STN stimulation-induced psychosis has been previously reported [4]. Psychosis from STN DBS lead placement associated micro-lesioning effect has also been seen prior to initiation of stimulation [5]. We report a case of acute-onset stimulation-related psychosis with suicidality induced by GPi DBS.

### 2. Case report

The patient was a 61-year-old man with a 16-year history of PD (Hoehn and Yahr stage 3). His PD course was notable for disabling medication-resistant motor fluctuations and dyskinesias. Additionally, he had a remote history of impulse control disorder symptoms related to higher-dose dopamine agonist therapy, but no other prior or current psychiatric symptomatology. Formal neuropsychological evaluation showed that cognitive functioning was within normal limits in all domains and generally strong. On self-report mood questionnaires, he did not report any current symptoms of mood disturbance (BDI-II = 0) and

denied experiencing any anxiety during the evaluation or in general (STAI-State = 20; STAI-Trait = 20).

An uncomplicated awake stereotactic micro-electrode recording guided implantation of bilateral GPi DBS quadripolar 3387 leads (Medtronic, MN, USA) was performed. The lead contacts were numerically designated 0–3 on the right side and 7–10 on the left. Postoperative micro-lesioning effects were not observed and stimulation was initiated 3 weeks after surgery. Additionally, postoperative MRI confirmed that the electrodes were well-placed bilaterally (Figs. 1, 2). PD medications were carbidopa/levodopa IR 25/100 mg TID, pramipexole 0.5 mg BID, amantadine 100 mg BID, and rasagiline 1 mg daily. No reductions or other changes were made in symptomatic PD medications post-operatively or at initiation of stimulation therapy.

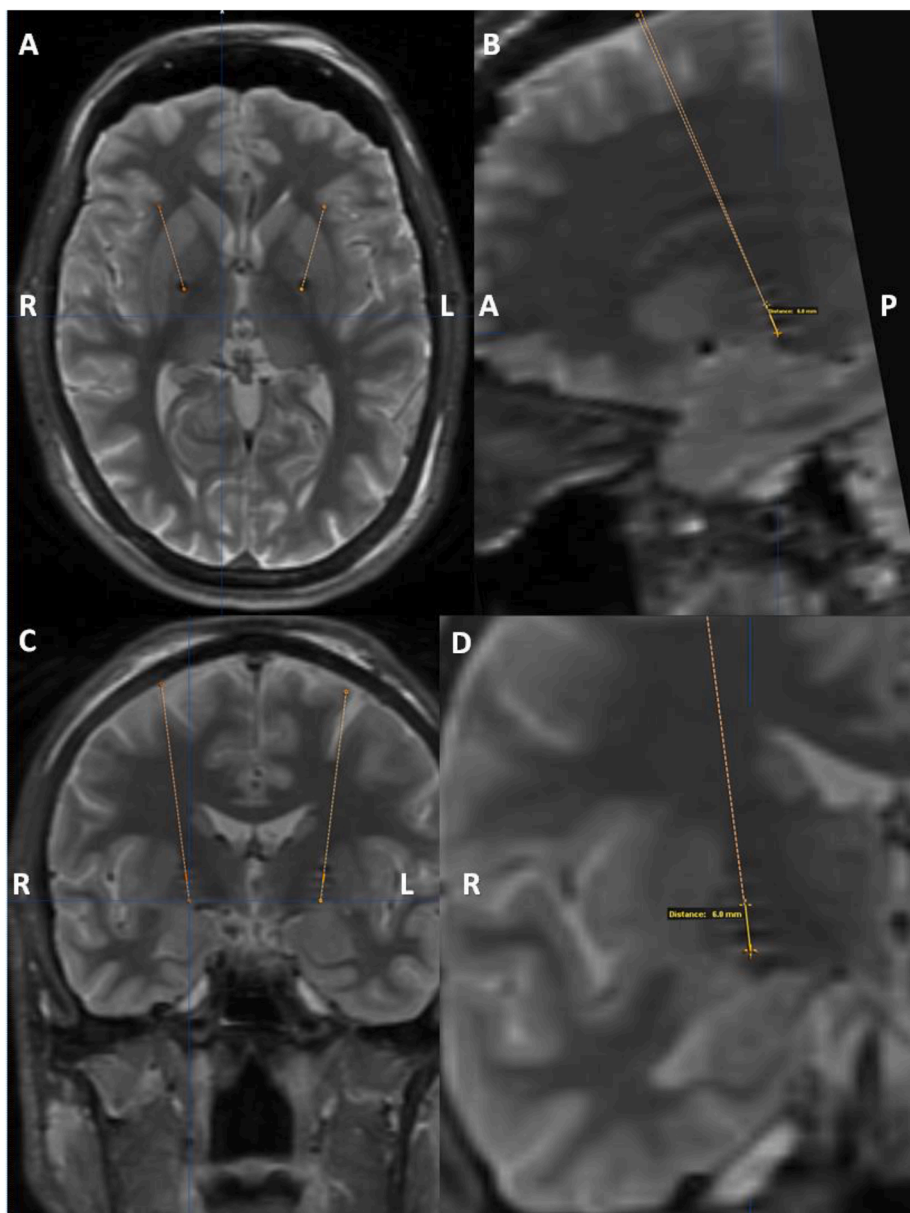
During the initial in-clinic stimulation survey, testing was performed at all contacts with a pulse duration of 60 us and frequency of 130 Hz. The patient experienced ill-defined emotional changes described as 'unwell' and 'down' at amplitudes above 3.0 V at the right 2 contact and at 2.5–3.0 V at the 3 contact in monopolar stimulation settings. Robust anti-parkinsonian clinical benefits were achieved at <2.5 V and with escalated pulse duration to 90 us at the 2 contact, without acute adverse effects. Final monopolar stimulation was programmed at right 2 contact with the following settings: amplitude 2.2 V/pulse duration 90us/frequency 130 Hz. Two hours later, the patient reported acute onset severe paranoia and depressive symptoms, with persistent thoughts that his spouse would violently cause his demise and wished him harm, thoughts of fatal self-harm, and continuous 'morbid thoughts' with associated feelings of intense sadness. All psychiatric symptoms ceased abruptly with stimulation discontinuation specifically to the right lead, and they returned immediately with supervised re-initiation in the clinic. With avoidance of stimulation at the right 2 and 3 contacts, these symptoms

<https://doi.org/10.1016/j.prdoa.2022.100175>

Received 19 September 2022; Received in revised form 15 November 2022; Accepted 28 November 2022

Available online 17 December 2022

2590-1125/© 2022 The Authors. Published by Elsevier Ltd. This is an open access article under the CC BY-NC-ND license (<http://creativecommons.org/licenses/by-nc-nd/4.0/>).



**Fig. 1.** Post-operative 1.5 T T2-weighted MRI in the axial (A), reconstructed sagittal (B), coronal planes (C) and magnified coronal (D) visualize the right lead well-placed in GPi. The ventral edge of the right 2 contact is visually estimated to be 6 mm dorsal to the ventral edge of the 0 contact (approximating the ventral border of GPi superior to the optic tract). The orange dashed line represents pre-operative optimized planned targeting well-aligned with the post-operative visualized lead in all planes. (For interpretation of the references to color in this figure legend, the reader is referred to the web version of this article.)

have remained absent for 11 years. The distal edge of the zero contact was placed at the placement target of the ventral border of the GPi. Measuring from the MRI-visualized distal edge of the 0 contact, the distal (ventral) edge of the 2 contact was measured at 6 mm above the stereotactic target and ventral border of GPi (Fig. 1b, d).

### 3. Discussion

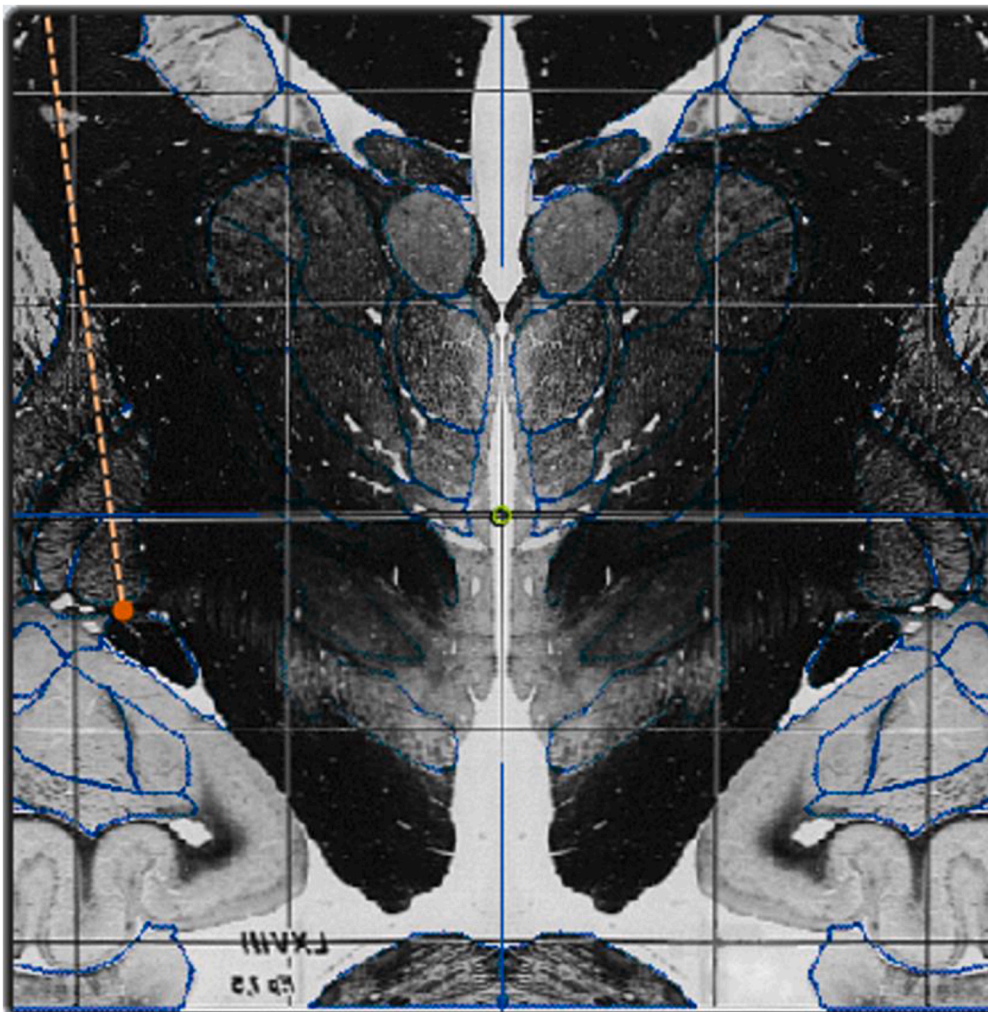
DBS is a highly effective intervention in treating the symptoms of advanced PD, with the most common targets being the STN and the GPi. Unfortunately, unwanted psychiatric symptoms have been described following stimulation of both these regions. We report the first case of acute-onset psychosis with suicidality induced by GPi stimulation. Although devastating, this appears to be a rare adverse effect.

Postoperative suicide is one of the most important and potentially preventable risks for mortality following STN DBS for PD, with the risk being significantly elevated in the first postoperative year and remaining elevated as far out as the fourth year [6]. Furthermore, a recent meta-analysis that examined data from 18 unique studies on suicidality in PD patients who underwent STN DBS showed a high pooled rate of suicidal

ideation in these patients (4%), while the pooled rates of attempted and completed suicide were both 1% [7].

Of note, two isolated cases, one of suicide and one of suicidal ideation following GPi stimulation have been reported. However, in contrast to the case of our patient in which the psychosis and suicidality developed immediately following DBS, both of these scenarios occurred one to three years following GPi DBS [3,8]. It remains unclear why the risk of suicidality is increased following stimulation of the STN in PD patients, but has rarely been documented with GPi DBS. While controlled trials of STN vs GPi DBS, such as Weaver et al., have shown similar motor outcomes, STN remains the more favored target in clinical practice providing comparatively less investigation and practice-based reported outcomes using GPi DBS [9,10].

There is also a neuroanatomical basis that could account for the differential reporting of suicidality. In general, it is thought that changes in mood and cognition that happen during stimulation of these nuclei may be caused by spread of current to non-motor, namely associative and limbic, portions of the GPi and STN as well as to adjacent pathways mediating non-motor functions [11]. Indeed, both nuclei have motor and non-motor regions that project to cortical areas associated with



**Fig. 2.** Aligned pre-operative targeting and post-operative lead location are superimposed on the Schaltenbrand-Wahren Atlas, supporting accurate placement of the right lead (including contact 2) within GPi.

mood and cognitive function. One important difference between targets is that, unlike GPi, STN carries an anticipated dose lowering in dopamine replacement therapies that may unmask symptoms such as depression, or apathy. Another major difference between the two nuclei is their size, with the STN ( $158 \text{ mm}^3$ ) being smaller than the GPi ( $478 \text{ mm}^3$ ) [11]. This may partially explain the higher incidence of cognitive and behavioral adverse effects as stimulation of the smaller STN may lead to more spreading of current from the intended sensorimotor area to unwanted associative and limbic regions of the nucleus. In a similar manner, it is possible that an undesired part of the GPi was stimulated in our patient, as the right DBS was placed several millimeters dorsal to the optimal target [12]. Immediately adjacent to the GPi is the globus pallidus externus (GPe) and it is possible that current overflow may have led to an off-target effect. It has been proposed that increased ventral GPe inhibition on GPi neurons projecting to the magnocellular portion of the mediodorsal thalamus may lead to enhanced ventral frontal inhibition of the dorsolateral prefrontal cortex, resulting in depression [13]. This could in part explain our patient's suicidality following GPi DBS. Finally, our patient had a history of impulse control disorder with higher doses of dopamine agonists pre-operatively, leading to the possibility of an underlying vulnerability of their mesolimbic pathways, although he had no current or ongoing psychiatric issues at the time of surgery.

#### 4. Conclusion

Though previously reported with STN DBS, this is the first report of GPi stimulation producing acute-onset psychosis, suicidality, and depressive symptoms in a PD patient. A review of the lead placement and MRI localization, relevant anatomy, and pertinent literature are reported. The information on stimulation-related effects of GPi is scarce in the literature, and further research is needed to clarify this phenomenon, as it is important to understand the widespread influences of deep brain stimulation. It is also clinically important to be aware of this potential severe and reversible side effect to facilitate discussion with patients and allow for appropriate adjustments to location and DBS settings.

#### Declaration of Competing Interest

The authors declare that they have no known competing financial interests or personal relationships that could have appeared to influence the work reported in this paper.

#### References

- [1] S.L. Wong, H. Gilmour, P.L. Ramage-Morin, Parkinson's disease: Prevalence, diagnosis and impact, *Health Rep.* 25 (11) (2014) 10–14.
- [2] C. Lachance, C. Spry, D. MacDougall, CADTH Rapid Response Reports, Deep Brain Stimulation for Parkinson's Disease: A Review of Clinical Effectiveness, Cost-Effectiveness, and Guidelines, Canadian Agency for Drugs and Technologies in

- Health. Copyright © 2018 Canadian Agency for Drugs and Technologies in Health, Ottawa (ON), 2018.
- [3] C. Buhmann, T. Huckhagel, K. Engel, A. Gulberti, U. Hidding, M. Poetter-Nerger, I. Goerendt, P. Ludewig, H. Braass, C.-U. Choe, K. Krajewski, C. Oehlwein, K. Mittmann, A.K. Engel, C. Gerloff, M. Westphal, J.A. Köppen, C.K.E. Moll, W. Hamel, Adverse events in deep brain stimulation: A retrospective long-term analysis of neurological, psychiatric and other occurrences, *PLoS One* 12 (7) (2017) e0178984.
- [4] A. Umemura, Y. Oka, K. Yamamoto, K. Okita, N. Matsukawa, K. Yamada, Complications of Subthalamic Nucleus Stimulation in Parkinson's Disease, *Neurol. Med. Chir.* 51 (11) (2011) 749–755.
- [5] A.S. Widge, P. Agarwal, M. Giroux, S. Farris, R.J. Kimmel, A.O. Hebb, Psychosis from subthalamic nucleus deep brain stimulator lesion effect, *Surg. Neurol. Int.* 4 (2013) 7.
- [6] V. Voon, P. Krack, A.E. Lang, A.M. Lozano, K. Dujardin, M. Schüpbach, J. D'Ambrosia, S. Thobois, F. Tamma, J. Herzog, J.D. Speelman, J. Samanta, C. Kubu, H. Rossignol, Y.Y. Poon, J.A. Saint-Cyr, C. Ardouin, E. Moro, A multicentre study on suicide outcomes following subthalamic stimulation for Parkinson's disease, *Brain* 131 (Pt 10) (2008) 2720–2728.
- [7] Y. Xu, B. Yang, C. Zhou, M. Gu, J. Long, F. Wang, Y. Zhu, B. Liu, H. Ren, X. Yang, Suicide and suicide attempts after subthalamic nucleus stimulation in Parkinson's disease: a systematic review and meta-analysis, *Neurol. Sci.* 42 (1) (2021) 267–274.
- [8] J.A. Boel, V.J.J. Odekerken, B.A. Schmand, G.J. Geurtsen, D.C. Cath, M. Figeet, P. van den Munckhof, R.J. de Haan, P.R. Schuurman, R.M.A. de Bie, V.J. J. Odekerken, J.A. Boel, T. van Laar, J.M.C. van Dijk, A. Mosch, C.F.E. Hoffmann, P.C.G. Nijssen, T. van Asseldonk, G.N. Beute, J.P.P. van Vugt, M.W.P.M. Lenders, M. Fiorella Contarino, L.J. Bour, G.J. Geurtsen, P. van den Munckhof, B. A. Schmand, R.J. de Haan, P.R. Schuurman, R.M.A. de Bie, Cognitive and psychiatric outcome 3 years after globus pallidus pars interna or subthalamic nucleus deep brain stimulation for Parkinson's disease, *Parkinsonism Relat. Disord.* 33 (2016) 90–95.
- [9] K.A. Follett, F.M. Weaver, M. Stern, K. Hur, C.L. Harris, P. Luo, W.J. Marks Jr., J. Rothlind, O. Sagher, C. Moy, R. Pahwa, K. Burchiel, P. Hogarth, E.C. Lai, J. E. Duda, K. Holloway, A. Samii, S. Horn, J.M. Bronstein, G. Stoner, P.A. Starr, R. Simpson, G. Baltuch, A. De Salles, G.D. Huang, D.J. Reda, Pallidal versus subthalamic deep-brain stimulation for Parkinson's disease, *N. Engl. J. Med.* 362 (22) (2010) 2077–2091.
- [10] E.A. Accolla, C. Pollo, Mood Effects After Deep Brain Stimulation for Parkinson's Disease: An Update, *Front. Neurol.* 10 (2019) 617.
- [11] M.S. Okun, J. Green, R. Saben, R. Gross, K.D. Foote, J.L. Vitek, Mood changes with deep brain stimulation of STN and GPi: results of a pilot study, *J. Neurol. Neurosurg. Psychiatry* 74 (11) (2003) 1584–1586.
- [12] L.V. Laitinen, Pallidotomy for Parkinson's disease, *Neurosurg. Clin. N. Am.* 6 (1) (1995) 105–112.
- [13] E.C. Lauterbach, J.G. Jackson, A.N. Wilson, G.E. Dever, A.D. Kirsh, Major depression after left posterior globus pallidus lesions, *Neuropsychiatry Neuropsychol. Behav. Neurol.* 10 (1) (1997) 9–16.