



OPEN ACCESS

## CASE REPORT

# Primary aortoduodenal fistula: a rare entity with lethal effects

Carly Rachel Noel Richards,<sup>1</sup> Robert McMurray,<sup>1</sup> Erik Criman,<sup>2</sup> Shane Rinehart<sup>1</sup>

<sup>1</sup>Department of General Surgery, Tripler Army Medical Center, Honolulu, Hawaii, USA  
<sup>2</sup>Tripler Army Medical Center, Tripler, Hawaii, USA

**Correspondence to**

Dr Carly Rachel Noel Richards,  
 carly.noel.richards@gmail.com

Accepted 7 October 2016

**SUMMARY**

Primary aortoduodenal fistula (ADF) is a rare but morbid diagnosis. Here, we present the case of a patient with a primary ADF that resulted in mortality. Despite multiple attempts at radiographic and endoscopic diagnosis, the fistula did not declare itself until the patient exsanguinated. Given the morbidity associated with ADF and the imperfection of associated diagnostic studies, a high index of suspicion is required to make a timely diagnosis.

**BACKGROUND**

Primary aortoduodenal fistulae (ADF) are very uncommon. Data from autopsy series show a prevalence of 0.07%. These cause an estimated 3% of massive gastrointestinal (GI) haemorrhages but comprise 6% of all deaths.<sup>1</sup> Secondary ADF (fistulae occurring after abdominal aneurysm repair) occur over 10 times more frequently than primary at a rate of 0.5–1.1%. This accounts for over 80% of all aortoenteric fistulae (AEF), and occur following an estimated 4% of open aortic repairs.<sup>2–4</sup> The rarity of primary AEF or ADF make it difficult to ascertain aetiology. While the treatment for massive GI bleeding follows an established algorithm, diagnosis of a primary ADF can be more difficult due to its infrequency as well as its occasionally insidious presentation. Early diagnosis of ADF is critical due to their significant lethality, with an estimated 5% of patients dying prior to surgical intervention. No one study has been able to quantify what the exact mortality is, but based on our literature review, it appears to be anywhere from 30% to 70%.<sup>2 5 6</sup> ADF is three times more common in men than women and features an average age at presentation of 64 years. As mentioned above, it is significantly more likely in patients who previously had an aortic intervention (eg, open aortic aneurysm repair). Unfortunately, elderly patients frequently present to emergency departments with upper GI bleeding and even with a high index of suspicion, ADF is rarely thought to be likely in a standard differential diagnosis.

**CASE PRESENTATION**

A man aged 78 years presented to the emergency room at an outside hospital with symptoms of new-onset left lower extremity numbness, tingling and a presyncopal episode. While in the emergency department, he began to have severe intermittent abdominal pain with multiple reported episodes of haematochezia. A nasogastric (NG) tube was placed with interval removal of an unknown quantity of

sanguineous output. CT angiogram (CTA) of his chest, abdomen and pelvis was performed along with a lower extremity arterial duplex. These showed a 4.6 cm abdominal aortic aneurysm (AAA) without evidence of rupture and a 1.6 cm left iliac aneurysm (figures 1 and 2). It also revealed non-visualisation of two of three mesenteric vessels with severe atherosclerosis of both external iliac arteries with near occlusion on the left. He was started on a proton-pump inhibitor infusion, transfused 2 units of packed red blood cells (PRBCs) and was transferred to our hospital for further care.

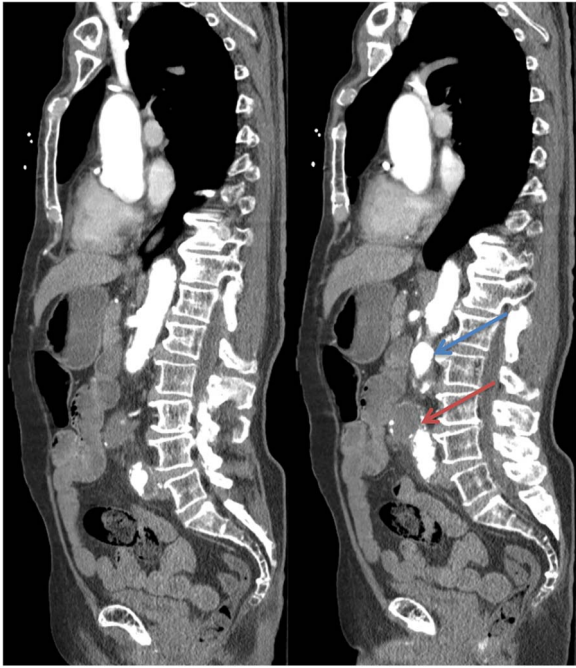On arrival, the gastroenterology service was consulted by the intensive care unit (ICU), but endoscopy was initially deferred because the patient had two bowel movements in the ICU without evidence of melena, he had no recurrence of haematochezia and NG tube output was non-bloody. Furthermore, he had a stable haemoglobin, his vital signs were within normal limits and his other symptoms seemed imperative at the time. Review of his medical history was notable for peripheral arterial disease, an AAA previously measuring 4.4 cm in size, a left iliac aneurysm measuring 1.6 cm and a splenectomy for lymphoma (unknown type). Several hours following admission, the patient became increasingly tachycardic, tachypnoeic, febrile, with worsening abdominal pain and a worsening leucocytosis. General surgery was consulted and his abdominal examination demonstrated peritonitis. Further, he was found to have a cold, pulseless left lower extremity with decreased sensation but preserved motor function. A lower extremity arterial duplex showed sluggish, monophasic flow to the left foot with occlusion of the femoral vessels and reconstitution at the popliteal artery. A presumptive diagnosis of mesenteric ischaemia and acute on chronic critical limb ischaemia was made, and the patient was prepared for an emergent exploratory laparotomy. A vascular surgery consult was placed and they recommended initiation of a heparin infusion postoperatively and aspirin for his threatened limb, with possible further interventions after stabilisation of his general surgical issues. The patient was given broad-spectrum antibiotics, full anticoagulation with heparin though a bolus dose was withheld due to his reported prior GI bleeding and he was taken to the operating theatre for exploration.

In the operating theatre, he was found to have a necrotic descending and sigmoid colon. An intraoperative oesophagogastroduodenoscopy (EGD) demonstrated clotted blood in the stomach and in the duodenum to the ampulla, with no evidence of



CrossMark

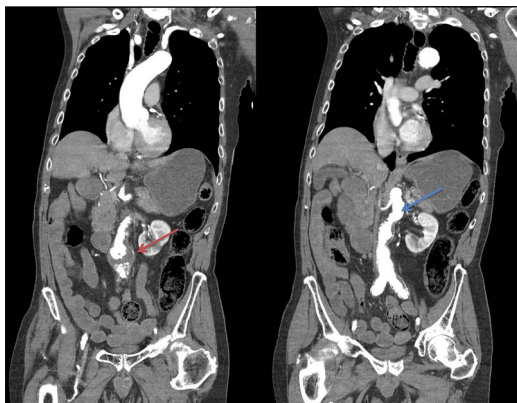
**To cite:** Richards CRN, McMurray R, Criman E, et al. *BMJ Case Rep* Published online: [please include Day Month Year] doi:10.1136/bcr-2016-217001



**Figure 1** Saggital CT angiography demonstrating separation between the patient's known 4.6 cm saccular (red arrow), infrarenal abdominal aortic aneurysm and the eventual site of exsanguinating haemorrhage (blue arrow). Note: there is no extravasation of contrast to suggest the presence of an aortoduodenal fistula.

active bleeding. A left colectomy was performed and the patient was left in discontinuity with temporary abdominal closure due to the patient's extremis and expectation of a 'second-look' operation. The possibility of an ADF was discussed initially but in the light of the ischaemic left colon and unimpressive EGD, this diagnosis was thought to be unlikely.

The patient was taken back to the ICU for further resuscitation. After receiving 4 units of PRBCs perioperatively, his haemoglobin had increased appropriately to 14.7 g/dL. His vital signs and base deficit normalised. He was kept on antibiotics for ischaemic colitis and low-dose heparin for suspected acute on chronic critical ischaemia of the left lower extremity. The second-look operation was planned for 24–36 hours after his



**Figure 2** Coronal CT angiography demonstrating separation between the patient's known 4.6 cm saccular (red arrow), infrarenal abdominal aortic aneurysm and the eventual site of exsanguinating haemorrhage (blue arrow). Note: there is no extravasation of contrast to suggest the presence of an aortoduodenal fistula.

initial surgery in order to further investigate the source of his GI bleeding, reassess the viability of his bowel, mature a stoma and possibly close his abdomen. The patient remained stable for 20 hours until the night of postoperative day 1 when he experienced sudden-onset tachycardia and hypotension requiring vasopressor support, dropping haemoglobin and worsening abdominal distension. Shortly thereafter, he began to have grossly sanguineous output from his NG tube. A massive transfusion protocol was initiated and the patient was emergently taken to the operating theatre for haemorrhagic shock due to an upper GI bleed from an unclear source.

In the operating theatre, no extraluminal bleeding was appreciated. The small bowel and remaining colon appeared healthy. Given continued sanguineous drainage from the patient's NG tube, an anterior gastrotomy was made. This revealed a large volume of clot that was subsequently evacuated. The mucosal surface was otherwise intact and healthy appearing. During inspection of the stomach, a large volume of arterial blood was appreciated to be coming retrograde via the pylorus. A proximal, longitudinal duodenotomy was made, but there was no bleeding appreciated to be coming from the first or second part of the duodenum. Profuse bleeding continued from the distal small bowel and the patient went into cardiac arrest. His aorta was cross-clamped at the diaphragmatic hiatus and advanced cardiovascular life support was initiated. Despite maximal resuscitative efforts, the patient was pronounced dead 20 min later.

#### DIFFERENTIAL DIAGNOSIS

Gastric or duodenal ulcer, gastric or duodenal perforation, AAA, mesenteric ischaemia, Mallory Weiss tear, gastric or duodenal mass, aortoenteric fistula.

#### TREATMENT

Treatment of AEF includes repair of the aorta via either in situ graft placement or extra-anatomic bypass along with possible placement of in situ grafts. Omentum should then be placed over the repair.

The repair of the small bowel is generally performed primarily but at times may require resection and anastomosis.

#### OUTCOME AND FOLLOW-UP

Postmortem, further exploration and medial visceral rotation of the duodenum revealed a 4 mm ulcer in the third portion. Blood was expressed via this penetrating ulcer with manual compression of the underlying aorta, consistent with a primary ADF.

#### DISCUSSION

Diagnosis of an ADF or AEF can be challenging as a frequent presentation is that of a minor upper GI bleed. In primary and secondary ADF, the most common symptoms of an actively bleeding fistula are haematemesis, melena, the sequelae of hypotension (such as fatigue or syncope) and abdominal pain. Non-bleeding fistulae may simply present as abdominal pain.<sup>7–9</sup> The aetiology of secondary ADF or AEF appears to involve either sepsis, mechanical trauma between the graft and adherent intestine or a combination of both.<sup>3</sup> Secondary AEF most frequently occur 36 months postoperatively but can vary in time to presentation from a few months to several years. Most AEF involve the duodenum (60%), but fistulae between the aorta and the GI tract can occur from the oesophagus to the colon.<sup>5</sup> The declining incidence of oesophageal aortic fistulae is primarily due to the declining prevalence of syphilis, but the remainder of the distribution appears to have stayed the same since its first

discovery in the midnineteenth century.<sup>10</sup> The aetiology of primary ADF is more controversial and likely more idiosyncratic. In the patient described above, there was a stable AAA, which was significantly more inferior than the level of the fistula. It is possible that this was involved in the aetiology of this particular patient's ADF, but seems highly unlikely to be a direct cause in the light of the physical separation of the AAA from the ADF. It is more likely that the advanced atherosclerotic disease that contributed to the development of an AAA also caused the primary ADF.

CT has an estimated sensitivity of 60%. While this is the most sensitive of available imaging modalities, the false-negative rate is quite high. As no one imaging modality is highly sensitive, CT scan, barium swallow and angiography can all be complementary to elicit the correct diagnosis.<sup>6–11</sup> Endoscopy, as was performed in this case, may not visualise the bleed and may disrupt a clot. Conversely, it may also provide essential diagnostic information. We suggest that endoscopy be performed in the operating theatre by a highly experienced endoscopist if there is high clinical suspicion for an ADF due to the potential for sudden, life-threatening bleeding. Had the endoscopist in this scenario reached the third portion of the duodenum, it is possible that the ADF would have been discovered prior to exsanguination. Classically, a 'herald bleed' is described as a form of self-limited period of bleeding, providing warning for a subsequent massive haemorrhage. The frequency of this poorly understood phenomenon is unknown, and by definition, it may be subclinical. There can also be a significant variance in the time course between the 'herald bleed' and a massive haemorrhage, anywhere from 6 hours to 3 weeks. While resuscitation is the first step in the treatment of ADF, preventing hypertension and even permissive hypotension may just as critical to avoid disruption of a formed thrombus.<sup>4 12–14</sup>

An estimated 50% of all AEF repairs (to include primary and secondary ADF or AEF) involve an extra-anatomic bypass with in situ grafts placed nearly 40% of the time. The placement of omentum over the repair and in situ (versus extra-anatomic) graft placement are two factors that appear to reduce the overall mortality. The most frequent cause of death in patients who survived the initial repair is recurrent ADF (49%), multiorgan system failure (16%) and sepsis (16%). The repair infrequently involves resection of small bowel with most enteric repairs being performed primarily. In patients requiring resection, resection and anastomosis are performed significantly more frequently than other procedures such as gastrojejunostomy or Roux en Y.<sup>6</sup>

This patient's herald bleed likely led to acute on chronic ischaemia in his left lower extremity as well as colonic ischaemia. The CTA was negative and the patient had no history of prior intervention on his known AAA. During the first operation, a plausible explanation for this patient's upper GI bleed was not discovered and would not be discovered until too late. While primary AEF is a rare clinical entity, nearly every other possible source of bleeding had been excluded by the time the patient exsanguinated. This speaks to the need for heightened clinical suspicion that must exist even for such unusual sources of life-threatening GI bleeding. In the immortal words of Sir Arthur Conan Doyle, 'When you have excluded the impossible, whatever remains, however improbable, must be the truth'.<sup>15</sup> Hence with the known poor sensitivity and specificity of all forms of imaging, negative test results rule out little. In the current era with highly sophisticated imaging, it can be easy to

forget that direct visualisation is sometimes the only form of direct evidence possible. Additionally, it seems that there is a trend towards limiting the invasiveness of large open surgeries as minimally invasive techniques are now the norm. It is better to have a negative exploratory laparotomy, or even a negative duodenotomy, than a dead patient.

### Learning points

- ▶ Owing to the difficulty in diagnosis of aortoenteric fistulae (AEF), a high index of suspicion is necessary to make a timely diagnosis.
- ▶ While CT angiography is the best studied imaging modality available, its sensitivity is poor for AEF.
- ▶ The standard presentation of this diagnosis may be confounded by patient-specific comorbidities.
- ▶ When exploring the abdomen for massive upper gastrointestinal bleeding, it is imperative to examine the third portion of the duodenum.

**Contributors** CRNR provided manuscript editing as well as literature review. EC and RM provided manuscript writing and review. SR provided intellectual content and manuscript editing.

**Competing interests** None declared.

**Patient consent** Obtained.

**Provenance and peer review** Not commissioned; externally peer reviewed.

**Open Access** This is an Open Access article distributed in accordance with the Creative Commons Attribution Non Commercial (CC BY-NC 4.0) license, which permits others to distribute, remix, adapt, build upon this work non-commercially, and license their derivative works on different terms, provided the original work is properly cited and the use is non-commercial. See: <http://creativecommons.org/licenses/by-nc/4.0/>

### REFERENCES

- 1 Kane JM, Meyer KA, Kozoll DD. An anatomical approach to the problem of massive gastrointestinal hemorrhage. *AMA Arch Surg* 1955;70:570–82.
- 2 Ohki T, Veith FJ, Shaw P, et al. Increasing incidence of midterm and long-term complications after endovascular graft repair of abdominal aortic aneurysms: a note of caution based on a 9-year experience. *Ann Surg* 2001;234:323–34; discussion 334–5.
- 3 Bergqvist D, Alm A, Claes G, et al. Secondary aortoenteric fistulas—an analysis of 42 cases. *Eur J Vasc Surg* 1987;1:11–18.
- 4 Saers SJ, Scheltinga MR. Primary aortoenteric fistula. *Br J Surg* 2005;92:143–52.
- 5 Champion MC, Sullivan SN, Coles JC, et al. Aortoenteric fistula. Incidence, presentation recognition, and management. *Ann Surg* 1982;195:314–7.
- 6 Rodrigues dos Santos C, Casaca R, Mendes de Almeida JC, et al. Enteric repair in aortoduodenal fistulas: a forgotten but often lethal player. *Ann Vasc Surg* 2014;28:756–62.
- 7 Wong JC, Taylor DC, Byrne MF. Aortoduodenal fistula: not always bleeding. *Can J Gastroenterol* 2013;27:444.
- 8 Saratzis N, Saratzis A, Melas N, et al. Aortoduodenal fistulas after endovascular stent-graft repair of abdominal aortic aneurysms: single-center experience and review of the literature. *J Endovasc Ther* 2008;15:441–8.
- 9 Glazier D, Graham A. Aortoduodenal fistula. *Can J Surg* 1998;41:99.
- 10 Gresham GA, Johnson HR. Rupture of aortic aneurysms into the gut. *Br Heart J* 1959;21:518–22.
- 11 Gregson R, Craig O. Aorto-enteric fistulae: the role of radiology. *Clin Radiol* 1983;34:65–72.
- 12 Ranasinghe W, Loa J, Allaf N, et al. Primary aortoenteric fistulae: the challenges in diagnosis and review of treatment. *Ann Vasc Surg* 2011;25:386.e1–5.
- 13 Donovan TJ, Bucknam CA. Aorto-enteric fistula. *Arch Surg* 1967;95:810–20.
- 14 Bala M, Sosna J, Appelbaum L, et al. Enigma of primary aortoduodenal fistula. *World J Gastroenterol* 2009;15:3191–3.
- 15 Doyle AC. *The sign of four*. Philadelphia: J & B Lippincott, 1890.

Copyright 2016 BMJ Publishing Group. All rights reserved. For permission to reuse any of this content visit <http://group.bmj.com/group/rights-licensing/permissions>.  
BMJ Case Report Fellows may re-use this article for personal use and teaching without any further permission.

Become a Fellow of BMJ Case Reports today and you can:

- ▶ Submit as many cases as you like
- ▶ Enjoy fast sympathetic peer review and rapid publication of accepted articles
- ▶ Access all the published articles
- ▶ Re-use any of the published material for personal use and teaching without further permission

For information on Institutional Fellowships contact [consortiasales@bmjgroup.com](mailto:consortiasales@bmjgroup.com)

Visit [casereports.bmj.com](http://casereports.bmj.com) for more articles like this and to become a Fellow