



The fourth supernumerary ovary in hepatorenal space mimicking an adrenal pheochromocytoma demonstrated with magnetic resonance imaging

Ying Wang¹, Zhijun Lin¹, Linghui Zhou¹, Kexu Song², Yu Lu², Jian Guan³

¹Department of Radiology, Sanmenxia Central Hospital, Sanmenxia, China; ²College of Medical Sciences, Zhengzhou University, Zhengzhou, China; ³Department of Radiology, The First Affiliated Hospital, Sun Yat-sen University, Guangzhou, China

Correspondence to: Jian Guan, MD, PhD. Department of Radiology, The First Affiliated Hospital, Sun Yat-sen University, No. 58 Zhongshan Er Road, Guangzhou 510080, China. Email: guanj6@mail.sysu.edu.cn.

Submitted Dec 16, 2022. Accepted for publication May 12, 2023. Published online Jun 06, 2023.

doi: 10.21037/qims-22-1393

View this article at: <https://dx.doi.org/10.21037/qims-22-1393>

Introduction

Supernumerary ovary, which frequently occurs in the pelvis, is defined as a third ovary having no connection with the utero-ovarian ligament, broad ligament, or infundibulopelvic ligament (1). Most patients with supernumerary ovary are asymptomatic but may occasionally have chronic abdominal and pelvic pain (1). Up to 36% of cases reported were associated with congenital urogenital anomalies, such as bicornuate and unicornuate uterus, bifid fallopian tubes, accessory tubal ostia, agenesis of the kidney or ureter, duplicated ureter, bladder diverticulum, accessory adrenal glands, and a lobulated liver (1-3). Notably, Wharton (2) reported a patient with 4 ovaries, representing, to our knowledge, the only case of a fourth supernumerary ovary in the literature, but imaging data for this case is lacking. Therefore, we here present the first case of a fourth supernumerary ovary in the hepatorenal space associated with right upper quadrant abdominal pain and demonstrated using magnetic resonance imaging (MRI).

Case presentation

A 30-year-old woman was admitted to our hospital because a mixed mass in liver segment VI was discovered with ultrasound in another hospital, and it was accompanied by right upper quadrant abdominal discomfort and fever for 3 days. The abdominal discomfort was not related to her menstrual cycle. Twenty-four-hour ambulatory blood

pressure monitoring and biochemistry examination including urinary vanillylmandelic acid (VMA; 39.6 $\mu\text{mol}/24\text{ h}$), plasma renin activity (0.6 ng/mL/h), angiotensin II (29.2 pg/mL), aldosterone (7.0 ng/dL), estradiol (E2; 54 pg/mL), follicle-stimulating hormone (FSH; 6.26 IU/L), and luteinizing hormone (LH; 2.26 IU/L) showed no abnormality. The patient underwent upper abdominal MRI with a 3.0 T MR system (Skyra, Siemens Healthineers, Erlangen, Germany). Contrast agent used was gadopentetate dimeglumine (0.2 mL/kg, Guangzhou Consun Pharmaceutical Co., LTD. Guangzhou, China). The MR scanning series included the following contents: axial, coronal T2-weighted imaging (T2WI), axial T1-weighted imaging (T1WI), diffusion-weighted imaging (DWI), apparent diffusion coefficient (ADC), and contrast-enhanced MRI. The upper abdominal MR images (*Figure 1A-1C*) showed a solid cystic mass (3.0 cm \times 4.2 cm \times 1.5 cm) in the hepatorenal space with hypointensity on T1WI, heterogeneous hyperintensity on T2WI, hyperintensity on DWI, and ADC with obvious enhancement. The mass appeared with unclear margins adjacent to the liver with multiple septations and a small capsular structure inside, and it was initially diagnosed as adrenal pheochromocytoma.

Due to the suspicion of pheochromocytoma, the patient was given α -adrenergic receptor antagonists to prevent unpredictable intraoperative hemodynamic instability before the operation. During the laparoscopic operation, we found a solid cystic mass adhering to the capsule of liver

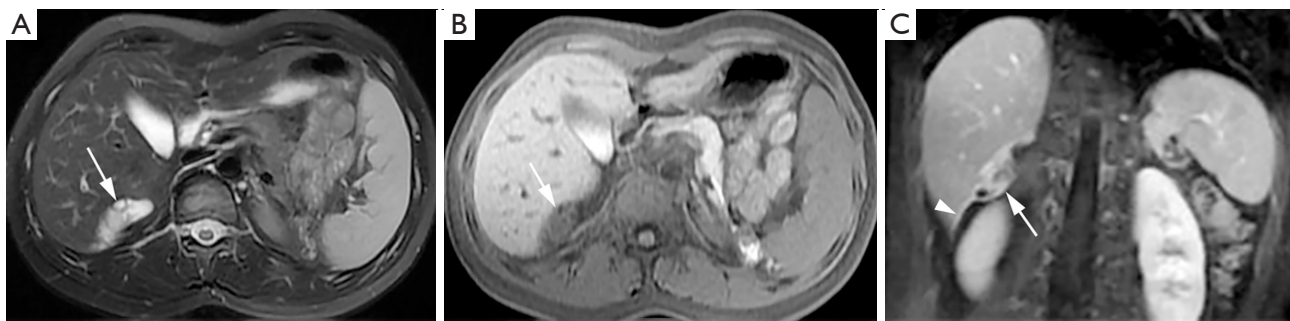


Figure 1 Preoperative upper abdominal MR imaging. (A) Axial fat-suppressed T2-weighted imaging revealed multiple cysts in the oval mass of the hepatorenal space with heterogeneous hyperintensity (arrow). (B) Axial T1-weighted imaging revealed an oval mass with unclear margins adjacent to the liver with mild hypointensity (arrow). (C) Coronal postcontrast fat-suppressed T1-weighted image showed a solid content of the mass with obvious enhancement (arrow) and a cord-like structure connected to the mass (arrowhead). MR, magnetic resonance.

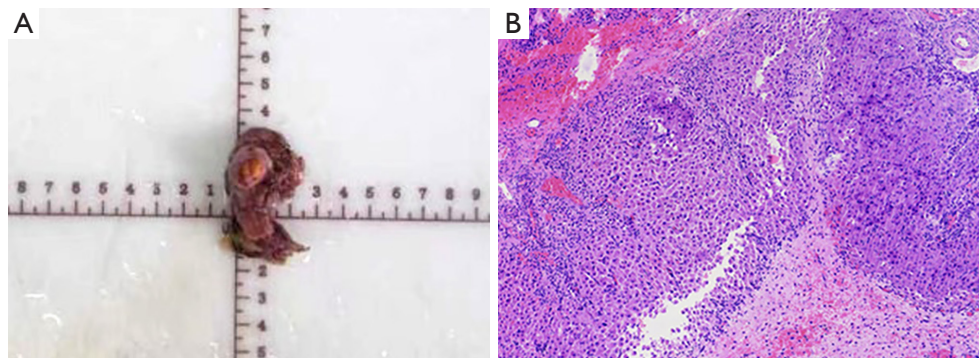


Figure 2 Photo of the removed organ and pathologic findings. (A) Photo of the removed organ. (B) Hematoxylin and eosin images (magnification, 400 \times) showed the ovarian tissue with corpus luteum and primitive follicles in the mass.

and kidney in the hepatorenal space. A cord-like structure was connected with the mass and extended caudally to the right uterine horn. The mass had communicating branched vessels connecting with the liver and the cord-like structure. In addition to 2 normally placed ovaries, ovarian tissue anterior to the right psoas major was found. The urologist and gynecologist's intraoperative diagnosis of the mass in the hepatorenal space was supernumerary ovary. A resection of the mass and the cord-like structure was performed (*Figure 2A*). Pathology (*Figure 2B*) showed ovarian tissue with the corpus luteum and primitive follicles in the mass, and the cord-like structure was confirmed to be the fallopian tube.

The woman was doing well postoperatively, and her abdominal pain was improved without recurrence after half a year of follow-up. At the 6-month follow-up, the total abdomen and pelvic MR images (*Figure 3*) revealed

3 ovaries, including a supernumerary ovary (1.4 cm \times 3.0 cm \times 1.3 cm) presenting as an oval mass with multiple follicular cysts anterior to the right psoas major and 2 normal ovaries with a septate uterus.

All procedures performed in this study were in accordance with the ethical standards of the relevant institutional and/or national research committee(s) and with the Declaration of Helsinki (as revised in 2013). Written informed consent was obtained from the patient for publication of this case report and accompanying images. A copy of the written consent is available for review by the editorial office of this journal.

Discussion

In 1890, Winkel (4) first described a case of supernumerary ovary in a 77-year-old woman who had never been

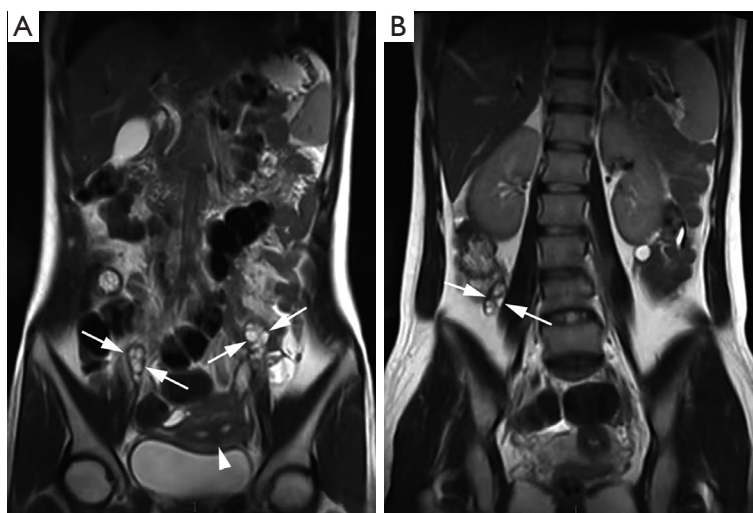


Figure 3 Postoperative total abdominal and pelvic MR imaging. (A,B) Coronal T2-weighted MR images revealed a septate uterus (A, arrowhead), 2 normally placed ovaries (A, arrows), and a supernumerary ovary (B, arrows) near the right psoas major. MR, magnetic resonance.

pregnant. The ovary was located at a concavity of the posterior wall of the bladder and was associated with a third fallopian tube. In 1959, Wharton (2) defined supernumerary ovary and accessory ovary. A supernumerary ovary is usually distant and distinct from the normally placed ovary and apparently arises from a separate primordium or anlage. An accessory ovary is situated near the normally placed ovary and may be connected with it (2). According to the criteria stated by Wharton (2), the ovaries in our case were supernumerary ovaries, with 1 located at the hepatorenal space and 1 near the right psoas major, with no connection to the normal ovaries.

Two theories have been proposed for this phenomenon, including an embryological or acquired origin (1). Normal ovarian development begins as primordial germ cells migrate from the yolk sac endoderm to the germinal ridge via the dorsal mesentery (3). Embryonic origin refers to aberrant migration or migratory arrest of germ cells following germ cell incorporation leading to the proliferation of the hindgut mesothelium. An acquired ectopic ovary can arise from the implantation of ovarian tissue resulting from surgery or chronic inflammation.

El-Gohary *et al.* (5) reviewed 46 cases reported from 1890 to 2015, and we found a further 3 cases via a literature search of cases up to the present (1,6,7). Among the 49 previously reported cases, the highest location of supernumerary ovary was the left of aorta while the lowest was the mesentery of the rectum. The supernumerary ovary

of our case was present in the second highest location. Of these cases, 48 involved a third ovary, but few cases had imaging data. A fourth ovary was recorded only in 1 case, a 30-year-old woman, who had a third ovary on the right pelvic wall and a fourth ovary at the base of the mesentery of the sigmoid at 15th month after the removal of the third ovary (2); unfortunately, the report of the case lacked imaging data. Here, we present a case involving 4 fully formed ovaries. In addition to 2 normally placed ovaries, there were 2 supernumerary ovaries, with 1 located at the hepatorenal space and 1 at the right psoas major, which were accompanied by a septate uterus. Complete imaging and pathological data are available for this case.

The preoperative diagnosis of the supernumerary ovary is relatively difficult, and thus this condition is usually discovered incidentally during surgery or autopsy. The symptoms of the supernumerary ovary are nonspecific. We believe the reason why the patient in our case had right upper quadrant pain may be that the mass in the hepatorenal space stimulated the liver capsule. The fact that the patient's abdominal pain was relieved after surgery indirectly supports this presumption. A review of her medical history indicated that the fever may be not related to the supernumerary ovary. MR images demonstrated a cystic solid mass in the hepatorenal space with obvious enhancement, and thus supernumerary ovary needed to be differentiated from hemangioma, metastasis, and pheochromocytoma, all of which also exhibit hypointensity

on T1WI and heterogeneous hyperintensity on T2WI. The specific sign of hemangioma is progressive enhancement, while metastases often show mild enhancement and are associated with a history of primary tumor (8). The mass in this case was especially difficult to distinguish from pheochromocytoma in terms of the MRI features. Thus, it was initially diagnosed as adrenal pheochromocytoma. However, patients with pheochromocytoma usually have typical symptoms, such as paroxysmal hypertension with the triad of headache, palpitations, and sweating, with elevated urinary catecholamine and VMA levels (9). In addition, by reviewing the images later, we found a follicle-like structure in the mass and a cord-like structure which was confirmed by pathology to be the fallopian tube connecting with the mass. Unfortunately, only upper abdominal MRI was initially performed, so the radiologists failed to track the cord-like structure which extended caudally to the right uterine horn. At the 6-month follow-up, complete imaging examinations were performed, including total abdomen and pelvic MRI, which provided a comprehensive diagnosis for the patient, as we could observe the supernumerary ovary anterior to the right psoas major and septate uterus. A large field of view covering the entire abdomen and pelvis is valuable to the diagnosis of the supernumerary ovary, as there may be more than one congenital anomaly associated with the ovary, as shown in this case.

In conclusion, we present the first case of a fourth supernumerary ovary in hepatorenal space associated with right upper quadrant abdominal pain that was demonstrated using MRI. Preoperative diagnosis of this condition is challenging. Our experience with the present case suggests that when MR images show a follicle-like structure, especially when concurrently associated with other urogenital malformations, supernumerary ovary should be highly suspected. Complete excision is recommended for accurate pathologic diagnosis of this rare gynecological anomaly and to eliminate the risk of malignant transformation.

Acknowledgments

Funding: None.

Footnote

Conflicts of Interest: All authors have completed the ICMJE uniform disclosure form (available at <https://qims.amegroups.com/article/view/10.21037/qims-22-1393/coif>).

The authors have no conflicts of interest to declare.

Ethical Statement: The authors are accountable for all aspects of the work in ensuring that questions related to the accuracy or integrity of any part of the work are appropriately investigated and resolved. All procedures performed in this study were conducted in accordance with the ethical standards of relevant the institutional and/or national research committee(s) and with the Declaration of Helsinki (as revised in 2013). Written informed consent was obtained from the patient to publish this case report and the accompanying images. A copy of the written consent is available for review by the editorial office of this journal.

Open Access Statement: This is an Open Access article distributed in accordance with the Creative Commons Attribution-NonCommercial-NoDerivs 4.0 International License (CC BY-NC-ND 4.0), which permits the non-commercial replication and distribution of the article with the strict proviso that no changes or edits are made and the original work is properly cited (including links to both the formal publication through the relevant DOI and the license). See: <https://creativecommons.org/licenses/by-nc-nd/4.0/>.

References

1. Lim CK, Kim HJ, Pack JS, Ha JG, Yang YS, Lee HK, Kim SH. Supernumerary ovary on recto-sigmoid colon with associated endometriosis. *Obstet Gynecol Sci* 2018;61:702-6.
2. Wharton LR. Two cases of supernumerary ovary and one of accessory ovary, with an analysis of previously reported cases. *Am J Obstet Gynecol* 1959;78:1101-19.
3. Cruikshank SH, Van Drie DM. Supernumerary ovaries: update and review. *Obstet Gynecol* 1982;60:126-9.
4. Winkel F. *Lehrbuch der Frauenkrankheiten*. 2nd ed. Leipzig: S Hirzel, 1890:617-20.
5. El-Gohary Y, Pagkratis S, Lee T, Scriven RJ. Supernumerary ovary presenting as a paraduodenal duplication cyst. *J Pediatr Surg Case Rep* 2015;3:316-9.
6. Gaur N, Jha M. The Third Ovary-Superfluous Ovary. *J Obstet Gynaecol India* 2022;72:83-5.
7. Ogishima D, Sakaguchi A, Kodama H, Ogura K, Miwa A, Sugimori Y, Matuoka S, Matsumoto T. Cystic Endometrioma with Coexisting Fibroma Originating in

- a Supernumerary Ovary in the Rectovaginal Pouch. Case Rep Obstet Gynecol 2017;2017:7239018.
8. Mayo-Smith WW, Boland GW, Noto RB, Lee MJ. State-of-the-art adrenal imaging. Radiographics 2001;21:995-1012.
 9. Wang K, Tang G, Peng Y, Li C, Fu W, Li R, Guan J. Adrenal pheochromocytoma: is it all or the tip of the iceberg? Jpn J Radiol 2022;40:120-34.

Cite this article as: Wang Y, Lin Z, Zhou L, Song K, Lu Y, Guan J. The fourth supernumerary ovary in hepatorenal space mimicking an adrenal pheochromocytoma demonstrated with magnetic resonance imaging. *Quant Imaging Med Surg* 2023;13(8):5388-5392. doi: 10.21037/qims-22-1393