



Twiddler's syndrome after dorsal root ganglion stimulation: A case report

Maarten Vanloon^{a,*}, Vincent Raymaekers^{b,c,d}, Sacha Meeuws^{e,f}, Mark Plazier^{d,e,f}

^a Faculty of Health, Medicine and Life Sciences, Maastricht University, the Netherlands

^b Department of Neurosurgery, University Hospitals Antwerp, Belgium

^c Faculty of Medicine and Health Sciences, University of Antwerp, Antwerp, Belgium

^d Faculty of Medicine and Life Science, Hasselt University, Hasselt, Belgium

^e Department of Neurosurgery, Jessa Hospital, Hasselt, Belgium

^f Study and Educational Center for Neurosurgery, Virga Jesse, Hasselt, Belgium

ARTICLE INFO

Keywords:

Dorsal root ganglion stimulation

Neurostimulation

Twiddler

Complications

ABSTRACT

Dorsal root ganglion stimulation (DRG-S) is a promising therapy for chronic neuropathic pain, but complications of this therapy are poorly understood. Twiddler's syndrome, a rare complication characterized by lead displacement and coiling of wires, has been reported in other neuromodulation devices, but has not been described in the context of DRG-S. Here, we present a first-of-a-kind case report of Twiddler's syndrome occurring after 8 months of DRG-S. This case report highlights the importance of considering Twiddler's syndrome as a potential complication in patients undergoing DRG-S, especially in those with significant weight loss history.

1. Introduction

Dorsal root ganglion stimulation (DRG-S) is an emerging therapy for chronic, neuropathic pain and an alternative to spinal cord stimulation (SCS). Compared to SCS, the DRG-S leads are characterized by a smaller cross-sectional area, contact size, contact distance, and less stiffness. Recent systematic reviews have shed light on the clinical value of dorsal root ganglion stimulation (DRG-S) in the management of chronic intractable pain. These comprehensive analyses have consistently demonstrated positive outcomes and high levels of patient satisfaction with both spinal cord stimulation (SCS) and DRG-S modalities [1]. Moreover, the evidence presented in these systematic reviews indicates that DRG-S has shown promise in the treatment of various non-complex regional pain syndrome (non-CRPS) chronic pain syndromes. Multiple lower-level studies have repeatedly and consistently reported successful outcomes with the use of DRG-S in reducing pain levels, improving functionality, and enhancing quality of life. These positive effects have been observed across various time frames, ranging from one week to three years [2]. Additionally, moderate-level evidence exists to support the efficacy of DRG stimulation in treating chronic focal neuropathic pain and complex regional pain syndrome. This further underscores the potential clinical value of DRG-S in addressing specific pain conditions that are challenging to manage with conventional treatments [3]. However, there are only a few studies examining the complications of DRG-S [4,5].

One rare complication of neuromodulation devices is Twiddler's syndrome. It presents itself with lead displacement and coiling of the wires [6]. The pathological mechanisms behind this syndrome are largely unknown. Only a few cases are described in spinal cord

Abbreviations: DRG-S, dorsal root ganglion stimulation; SCS, spinal cord stimulation; IPG, implantable pulse generator.

* Corresponding author.

E-mail address: maarten_vanloon@hotmail.com (M. Vanloon).

<https://doi.org/10.1016/j.heliyon.2023.e18365>

Received 17 May 2023; Received in revised form 10 July 2023; Accepted 14 July 2023

Available online 15 July 2023

2405-8440/© 2023 Published by Elsevier Ltd.

This is an open access article under the CC BY-NC-ND license

(<http://creativecommons.org/licenses/by-nc-nd/4.0/>).

stimulation. The mainstay of treatment for Twiddler's syndrome is complete revision of the neuromodulation device. In this article, we report a first of a kind case of Twiddler's syndrome of DRG-S. The PubMed database was used to review the first of a kind case. The search terms included were "dorsal root ganglion stimulation", "DRG-S", "neuromodulation" and "Twiddler's syndrome". No time limit was applied. No cases were found involving DRG-S. The CARE guidelines were used to describe the case and to reduce the risk of bias and increase transparency [7]. We discuss possible causes of Twiddler's syndrome and address the importance of substantial weight loss. Furthermore, we discuss different approaches to prevent lead migration.

2. Case description

We present a 43-year-old woman with complex regional pain syndrome of the right foot after the removal of osteosynthesis material due to complex ankle trauma. On physical examination, hyperesthesia, loss of temperature sensibility and pain of the right foot and ankle were present. She had a burning pain and allodynia at the medial malleolus. The pain was interpreted as partially neuro-pathic and mechanical. This pain prevented the patient from performing daily tasks such as cleaning, cooking, work, and also recreational activities such as exercising. A numeric rating scale (NRS) pain score of 8/10 was measured. The patient has a history of mild sleep apnea, chronic lumbago, hemithyroidectomy and a cerebrovascular accident at the age of 31 with a partial recovered left sided hemiparesis. Furthermore, the patient received a Roux-en-Y gastric bypass at the age of 39. This led to a significant reduction in weight from 123kg to 67kg over 4 years. In addition, the patient suffered from depressive symptoms and did not eat much due to the fear of gaining weight.

Her current medication was L-thyroxine, a SNRI, a betablocker, vitamin supplements, fentanyl, and paracetamol. The patient did not smoke, drink alcohol, or use illicit drugs. She had no known allergies.

The patient did not achieve the desired effect with painkillers and spinal nerve root blocks. After multidisciplinary consultation, the patient was approved DRG-S treatment. She responded well to the DRG-S and showed improvement in muscle spasms and pain symptoms. A NRS pain score of 3/10 was measured. Therefore, the definitive implantable pulse generator (IPG) was implanted. The pulse waves of 200 μ s were set at an amplitude of 1200 mA with a frequency of 20 Hz. Eight months post-operative, she noticed the IPG felt loose in the gluteal pocket. This caused local irritation and pain. Furthermore, she began to regain painful symptoms in her right foot. She presented with a burning sensation at the medial right ankle and the gluteal pocket. Allodynia was present at the medial malleolus. The patient regained problems to function in her daily life as mentioned above. An NRS pain score of 7/10 was noted. Due to the irritation of the IPG, a revision of the gluteal pocket was planned. Preoperative imaging revealed displacement of the electrode (Fig. 1A). During the revision, the gluteal pocket was more spacious and the IPG was held loosely. The X-ray also showed coiling of the wires and displacement of the leads (Fig. 1B).

In our patient, a percutaneous revision of the electrode was performed. The electrode was freely dissected. After this, gentle traction was applied to the epidural portion of the electrode. This released the first loops. Afterwards, dural stimulation and pain in the leg were noted when manipulating the last loop. Therefore, an open surgery was planned to reduce the risk of dural injury, postoperative bleeding, or nerve damage. Post-operative imaging revealed correct placement of the electrode and neurostimulator (Fig. 2A and B). The patient noted adequate pain relieve directly and one day postoperatively with a NRS score of 0/10 and 2/10, respectively. Two months later, the patient was seen again due to reduced effect of the DRG-S. A lumbar X-ray was repeated and showed migration of the electrode (Fig. 3A and B). Another open revision was performed without post-operative complications and correct position of the electrode. Four weeks of relative rest was advised to promote fixation of the electrode in the surrounding tissue. Two months post-

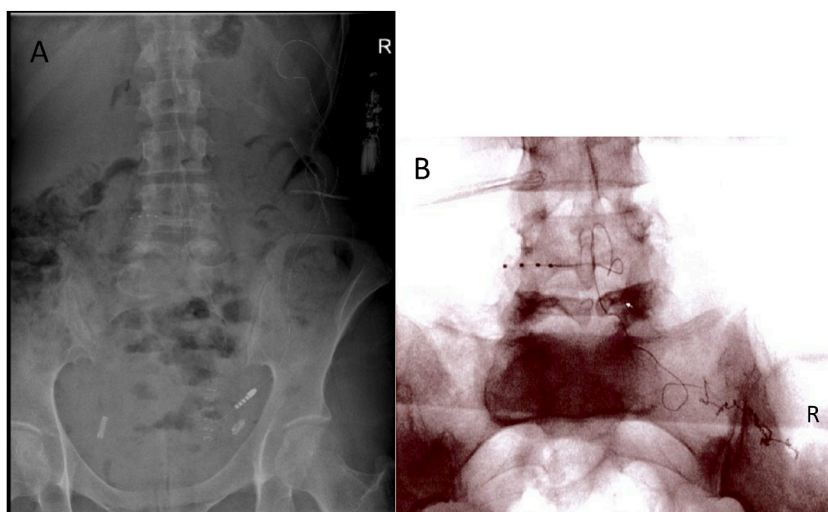


Fig. 1. (A) Preoperative lumbar X-ray showing displacement of the IPG in left flank with the tip of the electrode paramedian right at L4-L5. (B) Perioperative lumbar X-ray showing coiling of the wires and displacement of the lead.

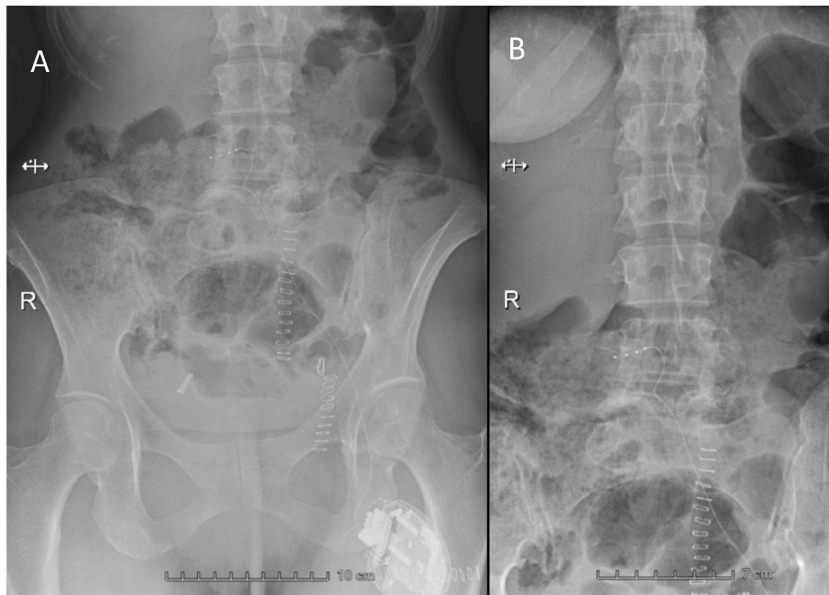


Fig. 2. Postoperative lumbar X-ray revealing the IPG in the left fossa (A) with tip of electrode paramedian right at L4-L5 (B).

operative there were no complications noted and she was satisfied with the current pain relief from the DRG-S. The current pulse waves of 200 μ s were set at an amplitude of 400 mA with a frequency of 20 Hz.

3. Discussion

Twiddler's syndrome refers to a malfunction of an implantable pulse generator due to manipulation or "twiddling" of the device. This conscious or subconscious manipulation of the patient leads to coiling and/or breaking of the wires and lead displacement. This has been commonly reported in cardiac devices and a few cases of spinal cord stimulation and intrathecal drug delivery devices [8,9]. To the best of our knowledge, this is the first case of Twiddler's syndrome after DRG-S described in literature.

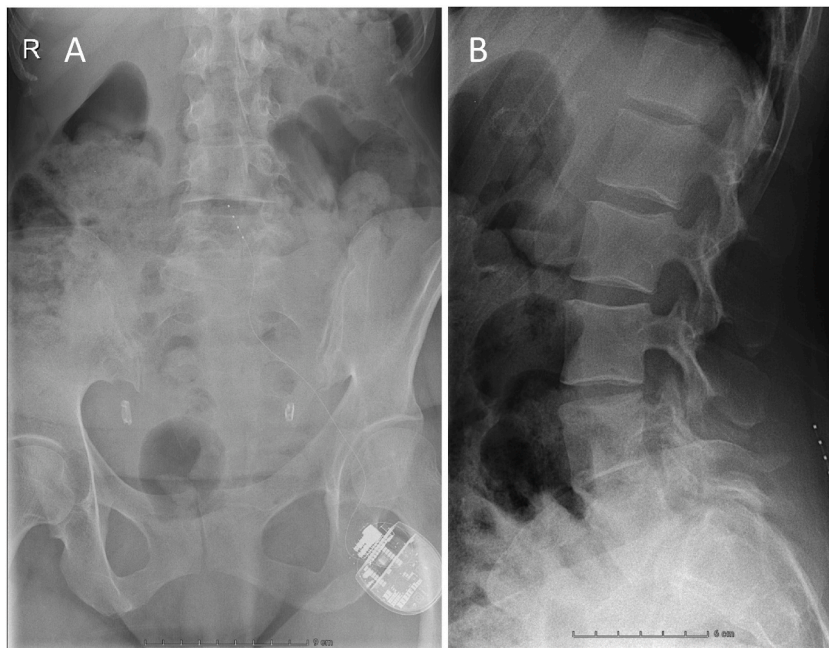


Fig. 3. Lumbar X-ray 2 months after open revision of the DRG-S showing electrode migration. (A) Anteroposterior view, (B) sagittal view. DRG-S, dorsal root ganglion stimulator.

DRG-S shows clinically significant effects for patients suffering from neuropathic pain. Nonetheless, problems related to maintenance and revision of the system have been scarcely described in literature. There are conflicting estimates of adverse events, particularly lead migration and lead fracture [4]. One possible explanation could be the change of physical properties of the leads over time. The study of Horan et al. describes their subjective experience that leads feel considerably stiffer at explantation compared to implantation [4]. Furthermore, local tissue transformations could contribute to these late complications. Our patient received DRG-S for approximately 8 months. It is possible that the aforementioned changes have contributed to the development of Twiddler's syndrome. However, it is unknown over which time period these local tissue transformations and possible lead stiffening could present itself.

One small retrospective study by Moens et al. showed a risk correlation between Twiddler's syndrome and high BMI, young age of implantation and use of antipsychotics in spinal cord stimulation and intrathecal drug delivery devices [6]. However, significant weight loss could also contribute to the risk of Twiddler's syndrome. Muscular and adipose weight loss could lead to the gluteal pocket becoming more spacious. Thus, making the device more prone to movement. In the study of Horan et al. the most reported DRG-S complications were lead fractures and migration. Consequently, the manufacturer advised to exclusively use epidural loops as fixation of the leads [4]. However, they found that the leads also broke at unanchored points. Furthermore, unanchored leads had an increased tendency to migrate.

Moens et al. suggested fixating the IPG to the fascia to prevent movement of the IPG [6]. In the case of our patient, it is important to consider the significant weight loss she experienced. Over a span of 4 years, she lost approximately 60 kg of body mass before she underwent the DRG-S trial a year later. This substantial weight loss, coupled with the utilization of physical therapy for her pain symptoms, may have contributed to the reduction of adipose tissue in the gluteal pocket, potentially making the IPG more susceptible to movement. Furthermore, the exact amount of weight lost by the patient in the 8 months following the implantation of the IPG remains unknown. Given her history of depressive symptoms and anxiety regarding weight gain, it is plausible that the weight loss was exacerbated during this period. Studies have provided insights into the long-term effects of weight loss following Roux-en-Y gastric bypass (RYGB) surgery, which may be relevant to our patient's case. In a study monitoring five women over a period of approximately 9 years after RYGB, it was observed that lean soft tissue loss averaged at 11.9 ± 5.6 kg. Fat-free mass also decreased by 12.6 ± 5.8 kg over the same period. While fat mass initially decreased significantly from pre-RYGB levels, it exhibited a trend towards an increase of 8.6 ± 7.0 kg between 1 year and 9 years post-RYGB [10]. Additionally, a meta-analysis comparing different bariatric procedures indicated that RYGB led to greater total body mass loss and fat mass loss compared to gastric banding, while lean mass loss was similar between the two procedures [11]. These findings highlight the complex dynamics of body composition changes following significant weight loss and suggest that anatomical changes in the gluteal pocket, potentially influenced by weight loss, could have contributed to the IPG displacement observed in our patient's case. Moreover, patients with chronic neuropathic pain are considered more psychologically vulnerable. Therefore, some patients might be more prone to manipulating implanted devices. Our patient suffered from depressive symptoms. Although she did not mention consciously fiddling with the device, it could be done subconsciously as a way to cope with some of the psychological distress.

In the event of a patient presenting with a similar complication of Twiddler's syndrome following DRG-S, it is crucial to follow a systematic approach to address the issue effectively. Firstly, a thorough evaluation of the patient's medical history, including any psychological vulnerabilities or tendencies towards device manipulation, should be conducted. This information will help in understanding potential risk factors and devising appropriate management strategies.

To prevent Twiddler's syndrome and mitigate the risk of lead displacement and migration, several precautionary measures can be implemented. Surgeons should consider fixing the IPG to the fascia during the initial implantation, thereby minimizing the chances of unintended movement. Additionally, securing the IPG in a well-defined pocket and considering the patient's body habitus, such as BMI and weight changes, can also be crucial factors to consider. In cases where significant weight loss or changes in adipose tissue are anticipated, close monitoring and proactive measures should be taken to ensure proper device stability.

In the event of suspected Twiddler's syndrome, thorough imaging studies, such as X-rays, should be performed to confirm the displacement or migration of the electrode. If confirmed, a staged approach can be considered. Initially, a percutaneous revision may be attempted, carefully dissecting, and releasing the electrode loops. However, if complications such as dural injury, postoperative bleeding, or nerve damage are anticipated due to the anatomical location or patient factors, an open surgical approach should be planned to reduce the associated risks. This approach allows for better visualization and manipulation of the leads while minimizing potential adverse events.

Furthermore, postoperative management and patient education play crucial roles in preventing future complications. Patients should receive comprehensive instructions regarding the proper care and handling of the IPG, including discouraging any manipulation or "twiddling" behaviors. Regular follow-up visits should be scheduled to assess the stability and functioning of the device, as well as to address any concerns or issues raised by the patient.

4. Conclusions

We present the first known case of Twiddler's syndrome with dorsal root ganglion stimulation. It is probable that significant weight loss can lead to increased movement space in the gluteal pocket. Furthermore, local tissue transformations and changes of physical properties over time could contribute to the problem. Consequently, these patients do not receive adequate pain modulation and might need additional surgery to restore the function of the neurostimulator.

It is important to be cautious of rapid weight loss and the efficacy of the DRG-S. Overweight patients with DRG-S, who are actively working on weight reduction, should receive regular follow-ups to assess DRG-S efficacy and symptom management.

Funding

The authors received no financial support or funding.

Availability of data and material

not applicable

Code availability

not applicable.

Ethics approval

not applicable.

Consent to participate

not applicable.

Consent for publication

not applicable.

Author contribution statement

All authors listed have significantly contributed to the investigation, development and writing of this article.

Data availability statement

The authors do not have permission to share data.

Declaration of competing interest

The authors declare that they have no known competing financial interests or personal relationships that could have appeared to influence the work reported in this paper.

References

- [1] J.M. Hagedorn, J. Romero, C.T. Ha, R.S. D'Souza, Patient satisfaction with spinal cord stimulation and dorsal root ganglion stimulation for chronic intractable pain: a systematic review and meta-analysis, *Neuromodulation* 25 (7) (2022) 947–955.
- [2] B. Stelter, J. Karri, A. Marathe, A. Abd-Elseyed, Dorsal root ganglion stimulation for the treatment of non-complex regional pain syndrome related chronic pain syndromes: a systematic review, *Neuromodulation* 24 (4) (2021) 622–633.
- [3] T.R. Deer, C.W. Hunter, P. Mehta, D. Sayed, J.S. Grider, T.J. Lamer, et al., A systematic literature review of dorsal root ganglion neurostimulation for the treatment of pain, *Pain Med.* 21 (8) (2020) 1581–1589.
- [4] M. Horan, A.H. Jacobsen, C. Scherer, C. Rosenlund, H.A. Gulisano, M. Søre, et al., Complications and effects of dorsal root ganglion stimulation in the treatment of chronic neuropathic pain: a nationwide cohort study in Denmark, *Neuromodulation* 24 (4) (2021) 729–737.
- [5] E. Sivanesan, M.C. Bicket, S.P. Cohen, Retrospective analysis of complications associated with dorsal root ganglion stimulation for pain relief in the FDA MAUDE database, *Reg. Anesth. Pain Med.* 44 (1) (2019) 100–106.
- [6] M. Moens, F. Petit, L. Goudman, A. De Smedt, P. Mariën, K. Ickmans, et al., Twiddler's syndrome and neuromodulation-devices: a troubled marriage, *Neuromodulation* 20 (3) (2017) 279–283.
- [7] J.J. Gagnier, G. Kienle, D.G. Altman, et al., The CARE guidelines: consensus-based clinical case reporting guideline development, *J. Med. Case Rep.* 7 (2013) 223. <https://doi.org/10.1186/1752-1947-7-223>.
- [8] R. Al-Mahfoudh, Y. Chan, H.P. Chong, J.O. Farah, Twiddler's syndrome in spinal cord stimulation, *Acta Neurochir.* 158 (1) (2016) 147–154.
- [9] B.C. Son, J.G. Choi, S.W. Ha, Twiddler's syndrome: a rare hardware complication in spinal cord stimulation, *Asian J. Neurosurg.* 13 (2) (2018) 403–406.
- [10] A.J. Cole, A.J. Kuchnia, L.M. Beckman, C. Jahansouz, J.R. Mager, S.D. Sibley, et al., Long-term body composition changes in women following roux-en-Y gastric bypass surgery, *JPEN - J. Parenter. Enter. Nutr.* 41 (4) (2017) 583–591.
- [11] A. Sylivris, J. Mesinovic, D. Scott, P. Jansons, Body composition changes at 12 months following different surgical weight loss interventions in adults with obesity: a systematic review and meta-analysis of randomized control trials, *Obes. Rev.* 23 (7) (2022), e13442.