

## Influence of Radiologically Evident Residual Intimal Tear on Expansion of Descending Aorta Following Surgery for Acute Type I Aortic Dissection

Yun Seok Kim, M.D.<sup>1</sup>, Jeong Heon Kim<sup>2</sup>, Joon Bum Kim, M.D.<sup>1</sup>, Dong Hyun Yang, M.D.<sup>3</sup>, Joon-Won Kang, M.D.<sup>3</sup>, Su Kyung Hwang, M.D.<sup>1</sup>, Suk Jung Choo, M.D.<sup>1</sup>, Cheol Hyun Chung, M.D.<sup>1</sup>

**Background:** Although a residual intimal tear may contribute to the dilatation of the descending aorta following surgical repair of acute type I aortic dissection (AD), its causal relationship has not been elucidated by clinical data due to the limited resolution of imaging modalities. **Methods:** This study enrolled 41 patients (age, 55.2±11.9 years) who were evaluated with dual-source computed tomography (CT) imaging of the whole aorta in the setting of the surgical repair of acute type I AD. Logistic regression models were used to determine the predictors of a composite of the aortic aneurysm formation (diameter >55 mm) and rapid aortic expansion (>5 mm/yr). **Results:** On initial CT, a distal re-entry tear was identified in 9 patients. Two patients failed to achieve proximal tear exclusion by the surgery. Serial follow-up CT evaluations (median, 24.6 months; range, 6.0 to 67.2 months) revealed that 14 patients showed rapid expansion of the descending aorta or aortic aneurysm formation. A multivariate analysis revealed that the residual intimal tear (odds ratio [OR], 4.31; 95% confidence interval [CI], 1.02 to 19.31) and the patent false lumen in the early postoperative setting (OR, 4.64; 95% CI, 0.99 to 43.61) were predictive of the composite endpoint. **Conclusion:** The presence of a residual intimal tear following surgery for acute type I AD adversely influenced the expansion of the descending aorta.

Key words: 1. Aortic dissection  
2. Aneurysm  
3. Surgery  
4. Risk analysis

### INTRODUCTION

Acute DeBakey type I aortic dissection is a life threatening medical emergency having a very high mortality rate if not treated surgically [1]. The surgical principles for the management of acute type I aortic dissection include the replacement of the affected proximal aorta and the exclusion of the pri-

mary intimal tear, consequently leaving the descending aorta untreated surgically [2]. Therefore, residual chronic dissection in the downstream aorta is a frequent condition following the urgent surgery for acute type I aortic dissection, and it is well known that this lesion predisposes the aorta to aneurysmal formation [3,4]. Several studies have been conducted to identify the risk factors of aneurysmal changes in the de-

<sup>1</sup>Department of Thoracic and Cardiovascular Surgery, Asan Medical Center, University of Ulsan College of Medicine, <sup>2</sup>Department of Thoracic and Cardiovascular Surgery, University of Ulsan College of Medicine, <sup>3</sup>Department of Radiology, Asan Medical Center, University of Ulsan College of Medicine

Received: September 2, 2013, Revised: October 8, 2013, Accepted: October 10, 2013

Corresponding author: Joon Bum Kim, Department of Thoracic and Cardiovascular Surgery, Asan Medical Center, University of Ulsan College of Medicine, 88 Olympic-ro 43-gil, Songpa-gu, Seoul 138-736, Korea  
(Tel) 82-2-3010-5416 (Fax) 82-2-3010-6966 (E-mail) jbkim1975@amc.seoul.kr

© The Korean Society for Thoracic and Cardiovascular Surgery. 2014. All right reserved.

© This is an open access article distributed under the terms of the Creative Commons Attribution Non-Commercial License (<http://creativecommons.org/licenses/by-nc/3.0>) which permits unrestricted non-commercial use, distribution, and reproduction in any medium, provided the original work is properly cited.

scending aorta and have shown that the presence of connective tissue disorders, the size and the false lumen status of the descending aorta, and a failure to exclude the primary intimal tear were correlated with aneurysm formation [2-6].

Further, the potential risk factors of the aneurysmal changes in the descending aorta may include the presence of a distal reentry tear that cannot be excluded during the urgent proximal operation. As with the failure to exclude the primary intimal tear, the distal reentry tears may be predisposed to the persistent patency of the false lumen in the descending aorta, which is also a well-known risk factor of aneurysm formation [7-10]. Nevertheless, this hypothesis has not been tested in real clinical settings because of the limited resolution of imaging modalities to identify such distal reentrant tears, which are typically small (<1 cm), through comprehensive evaluations on the whole aorta.

Now, in the era of evolving imaging modalities in clinical medicine, we have many modern tools that may allow us to identify such reentry tears with excellent resolution [11,12]. When gated by electrocardiography (ECG), current multi-detector computed tomography (CT) can obtain images of the cardiovascular system with a resolution of <1 mm and minimum motion artifact.

In this study, we hypothesized that a distal reentry tear identified by the current multi-detector CT in the setting of acute type I aortic dissection may correlate with aneurysm formation of the descending aorta following proximal aorta replacement. Therefore, we performed risk factor analyses to determine the independent predictors of the descending aorta aneurysmal changes following surgery for acute DeBakey type I aortic dissection, considering the distal reentry tear identifiable by the current multi-detector CT to be one of the important covariates in the multivariable model.

## METHODS

### 1) Patients

Between November 2006 and December 2011, 71 patients underwent an emergency operation for acute type I aortic dissection at Asan Medical Center. In these 71 patients, 23 patients were excluded because of poor quality CT images that were obtained from the referring hospitals. Of the remaining

48 patients, 7 patients who were not followed up with a CT evaluation beyond 6 months (including 2 patients who died within 6 months of surgery) were further excluded, resulting in the consideration of a total of 41 subjects in this study. Asan Medical Center ethics committee/review board waived the requirement for informed patient consent because this is a retrospective study.

### 2) Computed tomography techniques and follow-up

All CT scans were obtained in less than 48 hours after the symptom onset. Aortic CT angiography was conducted using either a first-generation dual-source CT (Somatom Definition; Siemens, Erlangen, Germany) or a second-generation dual-source CT (Somatom Definition Flash; Siemens). A contrast agent was administered using a power injector (Stellant D; Medrad, Indianola, PA, USA) at the rate of 3.5 to 4.0 mL/sec, with a total volume of 100 mL of iomeprol (Iomeron 370, Bracco Imaging, Italy), followed by 40 mL of a saline chaser. A region of interest was placed in the descending thoracic aorta, and image acquisition was automatically initiated once a selected threshold (100 HU) was reached using bolus tracking. An ECG-gated scan was conducted for the thoracic aorta followed by a non-ECG-gated scan for the abdominal aorta. To reduce the radiation dose, tube current modulation was implemented with a body-size adaptive tube voltage (range, 100 to 120 kVp) and a tube-current-time product (range, 270 to 440 mAs for the thoracic aorta; 200 mAs for the abdominal aorta). In addition, the ECG-based tube current modulation was implemented (relative risk interval, 65% to 85%). Image parameters were as follows: beam collimation: 64×0.6 mm (first generation) and 128×0.6 mm (second generation); gantry rotation time: 330 ms (first generation) and 280 ms (second generation); and pitch: 0.17–0.38 (for the thoracic aorta; adapted to the heart rate) and 1 (for the abdominal aorta). Axial images were obtained in contiguous 1.0- to 2.5-mm-thick sections from the aortic arch branching vessels to below the iliac bifurcation. The true and false lumen diameters were measured at the proximal descending (just distal to the aortic arch), mid descending (at the level of the pulmonary artery bifurcation), and lower descending (at the center of the left atrium) thoracic aorta and at the abdominal aorta (the level of origin of the renal ar-

tery). The endpoint of this study was the development of aortic aneurysm in any segment, defined as a maximal aortic luminal diameter  $>55$  mm, or aortic expansion rate  $>5$  mm/yr on follow-up CT [13].

### 3) Surgical technique

During median sternotomy, the right axillary or the right femoral arteries were cannulated. Venous cannulation was established by the single right atrial or bicaval method. Distal anastomosis was accomplished during moderate or deep hypothermic circulatory arrest. In general, antegrade selective cerebral perfusion was used in moderate hypothermia and retrograde cerebral perfusion was used in deep hypothermia. Based on the site of the proximal intimal tear and the presence of connective tissue disorders, we determined the extent of replacement: ascending aorta, hemiarch, or total arch replacement. If there is no proximal intimal tear in the ascending aorta or the aortic arch, the extent of replacement is limited in the hemiarch in non-Marfan patients. Resuspension of the aortic valve, replacement of the aortic valve, or modified Bentall's procedure was performed as required.

### 4) Statistics

Categorical variables are presented as numbers and percentages and were compared with the chi-square test and Fisher's exact test. Continuous variables are expressed as mean $\pm$ standard deviation or median with range, and were compared with Student unpaired t-test or the Mann-Whitney U-test. For the multivariate analyses, the logistic regression models were used to determine the risk factors of the composite of the development of aortic aneurysm or rapid aortic expansion. Preoperative and operative variables were evaluated in the models, and those with a p-value of 0.20 or less in the univariate analyses were candidates for the multivariate logistic regression models. Multivariate analyses involved a backward elimination technique, and only variables with a p-value of less than 0.10 were used in the final model. The final models were validated using 1,000 bootstrap samples. All reported p-values were two-sided, and the p-values of less than 0.05 were considered statistically significant. SPSS ver. 14.0 (SPSS Inc., Chicago, IL, USA) was used for the statistical analyses.

**Table 1.** Baseline patient profiles and CT findings

Variable	Value
Demographic & baseline risks	
Age (yr)	55.2 $\pm$ 11.9
Female gender	20 (48.8)
Diabetes mellitus	0
Hypertension	17 (41.4)
Marfan syndrome	4 (9.8)
Preoperative condition	
Shock	4 (9.8)
Malperfusion	
Cerebrovascular attack	4 (9.8)
Visceral malperfusion	0
Peripheral malperfusion	4 (9.8)
Intramural hematoma	6 (14.6)
Retro-A dissection	6 (14.6)
CT findings	
Distal extent	
Descending thoracic	2 (4.9)
Abdominal, suprarenal	3 (7.3)
Abdominal, infrarenal	7 (17.0)
Iliac or beyond iliac	28 (68.3)
Proximal intimal tear	
Ascending aorta	17 (41.5)
Aortic arch	15 (36.6)
Beyond aortic arch	2 (4.9)
Distal reentry intimal tear	
Abdominal, suprarenal	4 (9.8)
Abdominal, infrarenal	2 (4.9)
Iliac or beyond iliac	3 (7.3)
No intimal tear	6 (14.6)

Values are presented as mean $\pm$ standard deviation or number (%).

CT, computed tomography.

## RESULTS

### 1) Baseline patient characteristics

The baseline patients' demographics and clinical profiles, and the details of initial CT findings are presented in Table 1. Proximal intimal tears were identified in 34 patients (82.9%). Among them, 32 patients (78.0%) had the proximal intimal tears in the ascending aorta or the aortic arch, whereas 2 patients (4.9%) had the proximal tears beyond the aortic arch. Distal intimal tears were identified in 9 patients (22.0%) (Fig. 1). Multiple intimal tears were identified in 2 patients (4.9%): one had a proximal intimal tear at the proximal aortic

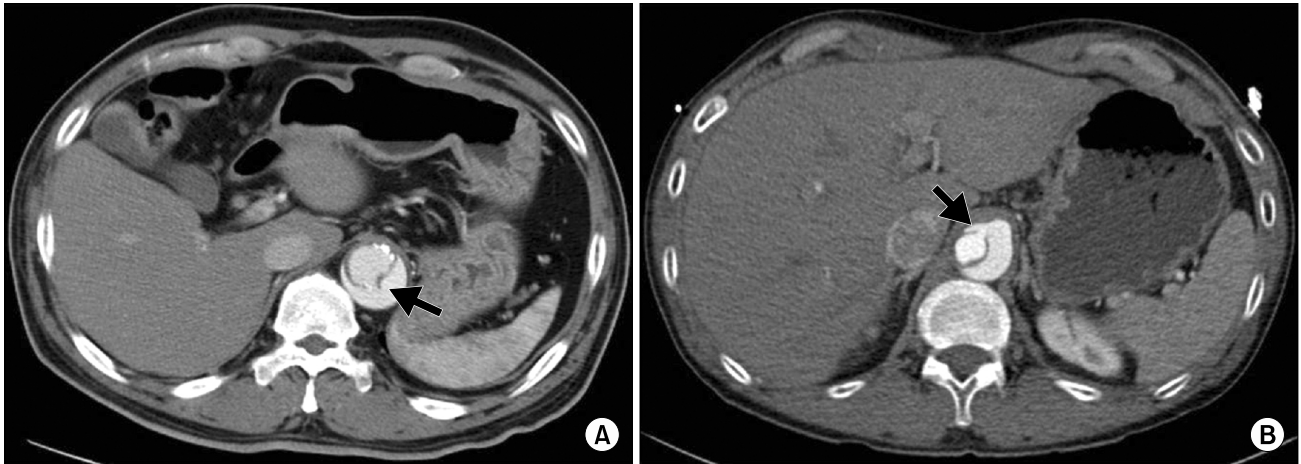


Fig. 1. (A, B) The intimal tear (arrow) connecting the true and the false lumen in the dissected descending aorta.

arch and three distal intimal tears at the suprarenal and infra-renal abdominal aorta and the left common iliac artery, and the other had a proximal intimal tear at the ascending aorta and two distal intimal tears at the suprarenal and infra-renal abdominal aorta. Six patients (14.6%) were diagnosed with type I intramural hematoma without a definite intimal tear through the whole aorta. There was one patient who had a distal intimal tear without a proximal intimal tear.

## 2) Operative procedures

Ascending aorta replacement was performed in 3 patients (7.3%). Among them, 1 patient underwent concomitant resuspension of the aortic valve, and another underwent concomitant replacement of the aortic valve. Hemiarach replacement with or without ascending aorta replacement was performed in 27 patients (65.9%). Among them, 19 patients underwent concomitant resuspension of the aortic valve, 3 patients underwent concomitant coronary artery bypass surgery, and 2 patients underwent concomitant modified Bentall's procedure. Total arch replacement with or without ascending aorta replacement was performed in 11 patients (26.8%). Among them, 8 patients underwent concomitant resuspension of the aortic valve and 1 patient underwent concomitant modified Bentall's procedure.

Among 34 patients (82.9%) who had an identified proximal intimal tear, complete exclusion of the proximal intimal tear was achieved in 32 patients (78.0%). The remaining 2 pa-

tients (4.9%) failed to achieve proximal tear exclusion; hemiarach replacement and total arch replacement were each performed in one of the 2. Of the 2 patients, one patient was one of the 9 patients who were identified as having a distal reentry tear on the initial CT evaluation. Consequently, 10 patients (24.4%) were revealed to have a residual intimal tear postoperatively.

## 3) Effects of residual intimal tear on the fate of the descending aorta

The median CT follow-up duration was 24.6 months (range, 6.0 to 67.2 months). There were no significant differences in the baseline diameters of the descending aorta according to the presence of the postoperative residual intimal tears (Table 2). However, in the early postoperative period, complete thrombosis of the false lumen was more frequently found in patients without the residual intimal tears compared with those without tears. The follow-up revealed that the diameters and growth rates of the whole descending aorta were larger and faster, respectively, in the patients with the residual tears, with statistical significance in most aortic segments (Table 2).

According to the patency of the false lumens, diameters of the descending thoracic aorta, particularly in the mid and distal segments, showed a decreasing tendency in patients with complete thrombosis of the false lumen. The last follow-up revealed that the diameters of the whole segments of the de-

**Table 2.** False lumen status, diameter and expansion rate of the descending aorta

Variable	Residual tear (+)	Residual tear (-)	p-value
Baseline aorta diameter (mm)			
Proximal descending	37.6±4.8	37.1±5.1	0.77
Mid descending	34.9±3.8	33.6±4.5	0.43
Distal descending	31.5±4.5	32.4±5.0	0.58
Abdominal aorta	24.7±3.1	24.5±3.4	0.91
Early postoperative false lumen status			0.032
Complete obliteration	1 (10.0)	14 (45.2)	
Partial thrombosis	3 (30.0)	11 (35.5)	
Patent	6 (60.0)	6 (19.4)	
Last follow-up aorta diameter (mm)			
Proximal descending	43.1±10.0	36.4±7.0	0.024
Mid descending	42.4±8.7	36.1±8.2	0.044
Distal descending	37.5±6.8	33.9±8.6	0.23
Abdominal aorta	31.6±4.9	27.9±5.0	0.049
Aortic expansion rate (mm/yr)			
Proximal descending	3.5±5.5	-0.6±4.2	0.016
Mid descending	5.6±5.8	1.1±4.4	0.014
Distal descending	4.0±4.6	0.8±4.3	0.049
Abdominal aorta	5.5±4.7	1.9±2.7	0.044

Values are presented as mean±standard deviation or number (%).

**Table 3.** Aortic expansion rate according to false lumen status in early postoperative period

Variable	Complete thrombosis	Patent false lumen	p-value
Baseline aorta diameter (mm)			
Proximal descending	35.4±5.0	37.7±4.9	0.28
Mid descending	32.1±4.5	34.4±4.1	0.35
Distal descending	30.2±5.1	32.7±4.6	0.36
Abdominal aorta	21.6±3.6	25.4±2.8	0.009
Aortic expansion rate (mm/yr)			
Proximal descending	-1.76 (-4.9 to 2.2)	0.54 (-9.4 to 16.7)	0.073
Mid descending	-1.51 (-5.5 to 1.4)	2.82 (-5.7 to 15.7)	0.004
Distal descending	-1.37 (-7.0 to 2.1)	2.14 (-7.6 to 15.4)	0.006
Abdominal aorta	1.83 (-0.4 to 9.4)	2.24 (-0.3 to 13.5)	0.95
Last follow-up aorta diameter (mm)			
Proximal descending	32.9±2.8	39.5±8.7	0.015
Mid descending	30.1±3.7	39.8±8.4	0.001
Distal descending	26.6±2.6	37.1±7.8	<0.001
Abdominal aorta	25.8±3.8	29.7±5.2	0.063

scending thoracic aorta were significantly smaller in patients with complete false lumen thrombosis than in those with patent false lumen (Table 3).

During follow-up, 14 patients (34.1%) eventually showed rapid expansion of the descending aorta, and of them, two patients developed aortic aneurysm. The multivariate analysis

revealed that the postoperative residual intimal tear was the only risk factor for the composite outcome of aortic enlargement or rapid expansion while the postoperative patency of false lumen showed borderline statistical significance (p=0.054) (Table 4).

**Table 4.** Risk factors for enlargement or rapid expansion of the descending aorta

Variable	Univariate	Multivariate		
	p-value	RR	95% CI	p-value
Age	0.32			
Gender	0.23			
Hypertension	0.70			
Marfan syndrome	0.49			
Distal extent of aortic dissection	0.14			
Initial diameter of aortic segments	0.20–0.82			
Total arch versus hemiarch repair	0.86			
Presence of distal reentry intimal tear	0.14			
Exclusion of proximal intimal tear	0.63			
Postoperative residual intimal tear	0.039	4.31	1.02–19.31	0.039
Postoperative patency of false lumen	0.179	4.64	0.99–43.61	0.054

RR, relative risk; CI, confidence interval.

## DISCUSSION

After surgical repair of acute type I aortic dissection, the distal dissected aorta is usually left untreated leaving the downstream aorta in danger of developing aortic aneurysm. Park et al. [7] identified several risk factors for the development of descending aortic aneurysm after the surgical repair of acute type I aortic dissection including patent or wide false lumens, larger aortic diameter, Marfan syndrome, younger age, and male sex. In agreement with the cited study, many studies have also indicated the ‘patent false lumen’ as a strong risk factor for distal aortic dilatation, late death, and requirements for distal aorta reintervention [3,5,6,8,14].

As non-exclusion of the primary intimal tear has also been revealed as a risk factor for aortic dilatation [9], various surgical procedures to exclude an intimal tear and thereby to obliterate the false lumen have been suggested in previous studies. For instance, a group advocated the routine performance of the total arch replacement in type I aortic dissection in order to exclude an invisible intimal tear, and revealed an acceptable operative risk and improved long-term outcomes [15]. Recently, several groups reported on the use of arch replacement combined with stent-graft implantation in the proximal descending aorta in the setting of acute type I aortic dissection [16,17]. The most important purpose of these efforts is to prevent descending aortic aneurysm by inducing false lumen thrombosis.

On the other hand, another study reported that total arch replacement was associated with greater morbidity and mortality than hemiarch replacement in acute type I aortic dissection [18]. Of note, Sakaguchi et al. [10] reported that although the patency of the false lumen was associated with poor prognosis, but it was not influenced by the extent of the aortic replacement. With respect to this, an accurate identification of the intimal tears preoperatively is very important to avoid an unnecessarily extensive arch replacement, which may increase morbidity or mortality.

In this study, we evaluated the effects of the intimal tear as well as the patency of the false lumen on the development of descending aortic aneurysm. We attempted to resect proximal intimal tears as much as possible in all individuals, but it was not achieved in two patients (4.9%), in whom the intimal tear was invisible in the operating field. In the present study, we supposed that the intimal tear was indispensable to the patency of the false lumen and demonstrated that patients with a residual intimal tear had a greater propensity to have false lumen patency. Nevertheless, only 14 patients among 31 patients who had no residual intimal tear showed complete obliteration of the false lumen. This finding indicates that the sensitivity of dual-source CT may still be limited in the detection of very small intimal tears that have hemodynamic significance.

This retrospective non-randomized study has several limitations. First, the follow-up CT scans were not taken at

the same interval, and the cumulative rate of the aortic dilatation might have been affected. Second, we included patients who survived more than 6 months and followed them by dual-source CT. This might have caused a selection bias. Third, the number of samples was relatively small (n=41), and we could not collect more samples because we introduced dual-source CT only in November 2006.

In conclusion, the presence of a residual intimal tear following surgery for acute type I aortic dissection adversely influenced the descending aorta in the late period. These results indicate that efforts should be directed to the obliteration of the distal re-entry tear in the development of forthcoming surgical techniques for acute type I aortic dissection.

## CONFLICT OF INTEREST

No potential conflict of interest relevant to this article was reported.

## REFERENCES

1. Booher AM, Isselbacher EM, Nienaber CA, et al. *The IRAD classification system for characterizing survival after aortic dissection*. Am J Med 2013;126:730.e19-24.
2. Kim JB, Lee CH, Lee TY, et al. *Descending aortic aneurysmal changes following surgery for acute DeBakey type I aortic dissection*. Eur J Cardiothorac Surg 2012;42:851-6.
3. Zierer A, Voeller RK, Hill KE, Kouchoukos NT, Damiano RJ Jr, Moon MR. *Aortic enlargement and late reoperation after repair of acute type A aortic dissection*. Ann Thorac Surg 2007;84:479-86.
4. Halstead JC, Meier M, Etz C, et al. *The fate of the distal aorta after repair of acute type A aortic dissection*. J Thorac Cardiovasc Surg 2007;133:127-35.
5. Immer FF, Hagen U, Berdat PA, Eckstein FS, Carrel TP. *Risk factors for secondary dilatation of the aorta after acute type A aortic dissection*. Eur J Cardiothorac Surg 2005;27:654-7.
6. Yeh CH, Chen MC, Wu YC, Wang YC, Chu JJ, Lin PJ. *Risk factors for descending aortic aneurysm formation in medium-term follow-up of patients with type A aortic dissection*. Chest 2003;124:989-95.
7. Park KH, Lim C, Choi JH, et al. *Midterm change of descending aortic false lumen after repair of acute type I dissection*. Ann Thorac Surg 2009;87:103-8.
8. Kimura N, Tanaka M, Kawahito K, Yamaguchi A, Ino T, Adachi H. *Influence of patent false lumen on long-term outcome after surgery for acute type A aortic dissection*. J Thorac Cardiovasc Surg 2008;136:1160-6, 1166.e1-3.
9. Unosawa S, Hata M, Niino T, Shimura K, Shiono M. *Prognosis of patients undergoing emergency surgery for type A acute aortic dissection without exclusion of the intimal tear*. J Thorac Cardiovasc Surg 2013;146:67-71.
10. Sakaguchi G, Komiya T, Tamura N, et al. *Patency of distal false lumen in acute dissection: extent of resection and prognosis*. Interact Cardiovasc Thorac Surg 2007;6:204-7.
11. Maldjian PD, Partyka L. *Intimal tears in thoracic aortic dissection: appearance on MDCT with virtual angioscopy*. AJR Am J Roentgenol 2012;198:955-61.
12. Quint LE, Platt JF, Sonnad SS, Deeb GM, Williams DM. *Aortic intimal tears: detection with spiral computed tomography*. J Endovasc Ther 2003;10:505-10.
13. Hiratzka LF, Bakris GL, Beckman JA, et al. *2010 ACCF/AHA/AATS/ACR/ASA/SCA/SCAI/SIR/STS/SVM guidelines for the diagnosis and management of patients with Thoracic Aortic Disease: a report of the American College of Cardiology Foundation/American Heart Association Task Force on Practice Guidelines, American Association for Thoracic Surgery, American College of Radiology, American Stroke Association, Society of Cardiovascular Anesthesiologists, Society for Cardiovascular Angiography and Interventions, Society of Interventional Radiology, Society of Thoracic Surgeons, and Society for Vascular Medicine*. Circulation 2010;121:e266-369.
14. Fattouch K, Sampognaro R, Navarra E, et al. *Long-term results after repair of type a acute aortic dissection according to false lumen patency*. Ann Thorac Surg 2009;88:1244-50.
15. Hirohata T, Nakamichi T, Munakata M, Takeuchi S. *Routine extended graft replacement for an acute type A aortic dissection and the patency of the residual false channel*. Ann Thorac Surg 2003;76:1957-61.
16. Kato M, Kuratani T, Kaneko M, Kyo S, Ohnishi K. *The results of total arch graft implantation with open stent-graft placement for type A aortic dissection*. J Thorac Cardiovasc Surg 2002;124:531-40.
17. Pochettino A, Brinkman WT, Moeller P, et al. *Antegrade thoracic stent grafting during repair of acute DeBakey I dissection prevents development of thoracoabdominal aortic aneurysms*. Ann Thorac Surg 2009;88:482-9.
18. Kim JB, Chung CH, Moon DH, et al. *Total arch repair versus hemiarch repair in the management of acute DeBakey type I aortic dissection*. Eur J Cardiothorac Surg 2011;40:881-7.