

Hypomagnesaemia induced hypocalcemia mimicking as acute exacerbation of COPD—Rare cause of a common presentation: A case report

Shankar Roy¹, Mahendra Meena¹, Nisha B. Dhoot², Ravi Kant³

¹Junior Resident, ²Senior Resident and ³Additional Professor, Department of General Medicine, AIIMS, Rishikesh, Uttarakhand, India

ABSTRACT

Chronic obstructive pulmonary disease (COPD) is a common respiratory condition characterized by limitation in airflow. Most of the exacerbations are due to respiratory infections, some are due to environmental pollution. Hypocalcaemia (of any etiology) is one of the rare causes of acute exacerbation. Here we are reporting a case of severe hypocalcaemia induced bronchospasm, presenting as acute exacerbation in a diagnosed case of COPD. 61 years old female patient, home maker by occupation and from a rural background and low socio-economic status with past history of chronic exposure to household wood smoke has presented to us with acute exacerbation of COPD. Her reports showed significant hypocalcaemia, hypomagnesaemia and low parathyroid hormone. Her symptoms were controlled adequately only after correcting the hypocalcemia in addition to the standard COPD management.

Keywords: Bronchospasm, COPD, hypocalcemia, hypomagnesemia

Introduction

Chronic obstructive pulmonary disease (COPD) is a common respiratory condition characterized by limitation in airflow. It affects more than 5% of the population and is associated with high morbidity and mortality.^[1] It is characterized by increased frequency and severity of coughing, worsening chest discomfort, wheezing, cough, and sputum productions.^[2] Most of the exacerbations are due to respiratory infections, some are due to environmental pollution, while a small fraction of cases etiology remains unknown.^[3] Symptomatic hypocalcemia (of any etiology) is one of those rare causes of acute exacerbation where the cause may remain obscured during the presentation.

The typical presentations of symptomatic hypocalcemia are paresthesias (perioral and extremities), muscle spasms, seizures, cardiac arrhythmias, Chvostek sign, Trousseau's sign, tetany (clinical or latent), and rarely bronchospasm^[4] Here, we are reporting a case of severe hypocalcemia induced bronchospasm, presenting as acute exacerbation in a diagnosed case of COPD.

Case Report

61 years old female patient, homemaker by occupation and from a rural background and low socio-economic status with a past history of chronic exposure to household wood smoke has presented to us with acute onset shortness of breath for 3 days and paresthesia around the cheek, lips, and bilateral upper limbs. There was no history of fever, chest pain, hemoptysis, altered sensorium abdominal pain, frequent fracture, any exposure to environmental pollutants. She is a known case of

Address for correspondence: Dr. Shankar Roy, JR Hostel, Room No 218, AIIMS, Veerbhadra Marg, Rishikesh - 249 201, Uttarakhand, India.
E-mail: dr.shankar.ghy@gmail.com

Received: 27-02-2020

Revised: 19-03-2020

Accepted: 30-03-2020

Published: 31-05-2020

Access this article online

Quick Response Code:



Website:
www.jfmpc.com

DOI:
10.4103/jfmpc.jfmpc_314_20

This is an open access journal, and articles are distributed under the terms of the Creative Commons Attribution-NonCommercial-ShareAlike 4.0 License, which allows others to remix, tweak, and build upon the work non-commercially, as long as appropriate credit is given and the new creations are licensed under the identical terms.

For reprints contact: WKHLRPMedknow_reprints@wolterskluwer.com

How to cite this article: Roy S, Meena M, Dhoot NB, Kant R. Hypomagnesaemia induced hypocalcemia mimicking as acute exacerbation of COPD—Rare cause of a common presentation: A case report. J Family Med Prim Care 2020;9:2541-3.

COPD for 1 year and was on the metered-dose inhaler (beta agonist + steroid). No past history of any head and neck surgery or renal stone. On admission, she was tachypneic and bilateral rhonchi on auscultation. She was nebulized with Budecort and salbutamol. The injectable steroid was given. But symptoms didn't improve satisfactorily. Her arterial blood gas (ABG) analysis showed low ionized calcium and her ECG [Figure 1] showed prolong QTc interval. Her blood chemistry reveals hypocalcemia. She was given injection calcium gluconate (10%) 10 mL IV bolus over 10 min and then put on calcium gluconate infusion (11 amp, i.e. approx. 1000 mg elemental) in 1 L of 5% dextrose for next 24 h and admitted in a medical intensive unit. Apparently, clear chest X-ray [Figure 2] and normal procalcitonin ruled out the infective etiology as a precipitating factor. Further evaluation revealed low serum magnesium and parathyroid hormone (PTH) levels along with normal vitamin D levels. Subsequently, she was given magnesium correction and put on oral calcitriol and calcium supplement along with inhalational beta-agonist. Gradually her symptoms improved. These are her laboratory investigation report [Table 1].

Discussion

The Global Initiative for Chronic Obstructive Lung Disease (GOLD), a project initiated by the National Heart, Lung, and Blood Institute (NHLBI) and the World Health Organization (WHO), defines COPD as follows^[5]-

“COPD is a common, preventable, and treatable disease that is characterized by persistent respiratory symptoms and airflow limitation that is due to airway and/or alveolar abnormalities usually caused by significant exposure to noxious particles or gases. The chronic airflow limitation that characterizes COPD is caused by a mixture of small airways disease (e.g. obstructive bronchiolitis) and parenchymal destruction (emphysema), the relative contributions of which vary from person to person. Chronic inflammation causes structural changes, small airways narrowing, and destruction of lung parenchyma. A loss of small

airways may contribute to airflow limitation and mucociliary dysfunction, a characteristic feature of the disease.”

On some rare occasions, the cause of exacerbation may remain unknown. Hypocalcemia is one of those causes which may not be thought initially if a strong suspicion is not kept. The typical symptoms of hypocalcemia are paresthesias in the peri-oral and extremities along with fatigue, anxiety and tetany.

Table 1: Laboratory investigation reports of the patient

Investigation	Normal value	Date		
		24/12/19	26/12/19	28/12/19
Hb%	12-15	10.4		
TLC (/mm ³)	4000-10000	7400		
Platelet (/mm ³)	1.5-4.5 lakh	2.4lakh		
Bilirubin (T) (mg/dL)	0.2-1.10	0.54		
Bilirubin (D) (mg/dL)	<0.20	0.17		
SGPT (U/L)	0-45	48		
SGOT (U/L)	0-40	51		
ALP (U/L)	Up to 270	94		
GGT (U/L)	5-36	32		
S. protein (gm/dL)	6.40-8.10	8.4		
S. albumin (gm/dL)	3.2-4.6	4.0		
S. globulin (gm/dL)	3.20-4.60	4.4		
Blood urea (mg/dL)	17-50	35		
S. creatinine (mg/dL)	0.5-1.20	0.40		
S. Na+ (mEq/L)	136-145	138		
S. K+ (mEq/L)	3.5-4.5	4.45		
S. uric acid (mg/dL)	2.6-6.0	3.0		
S. calcium (mg/dL)	8.0-10.8	5.4	6.1	7.3
Ionized Ca ²⁺ (mmol/L)	1.15-1.33	0.58	0.77	1.04
Phosphorus (mg/dL)	2.8-4.0	5.0		4.2
Magnesium (mg/dl)	1.7-2.7	1.03		2.2
PTH (pg/mL)	12-68	0.70		
Vitamin D (ng/mL)	30-50	47		
QTc (Bazett formula)	<450 ms (female)	520		
Procalcitonin	0.025-0.300	0.300		

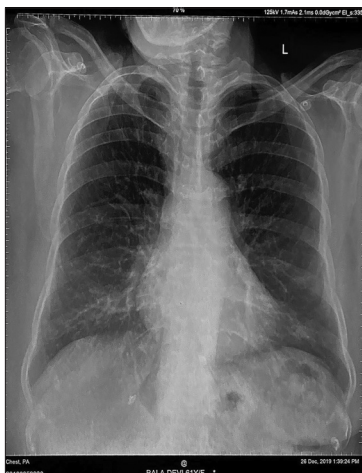

Figure 1: Chest x ray showing hyperinflation and no evidence of any infective etiology

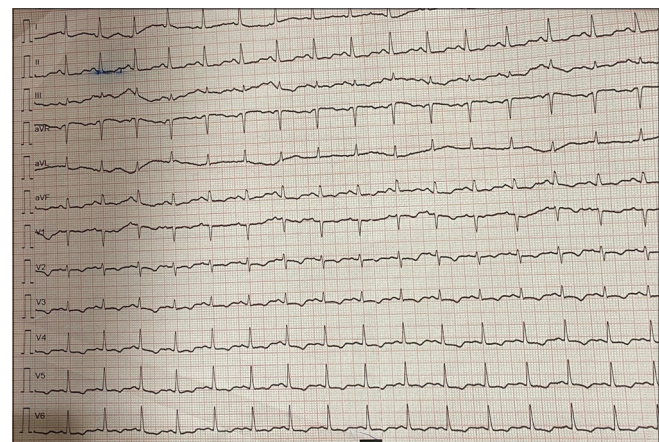


Figure 2: ECG showing prolong QTc (520msec) due to hypocalcaemia

In extreme cases, bronchospasm and laryngospasm with wheeze and stridor may occur, as a result of neuromuscular irritability.^[6]

In our case also, she presented with acute exacerbation along with typical symptoms and characteristics ECG changes of hypocalcemia. He was initially given standard treatment (inhaled bronchodilator and steroid) but without significant improvement. Subsequently, she was given calcium infusion and her symptoms dramatically improved. The cause of hypocalcemia was found to be due to hypomagnesemia and low PTH. A low magnesium level reduces the PTH secretion and as well as end-organ receptor sensitivity.^[7] In a recently conducted study it has been found that In elderly patients with acute exacerbation of COPD, hypocalcemia may be related to the disease progression, hospitalization and infection rate.

Since COPD is so common in our society because of the high burden of a smoker, a primary care physician should be able to treat those acute events. However, this case has taught us that if a smart suspicion is not kept on all the parameters related to a patient, a physician can miss the easily correctable factors.

Conclusion

COPD is a very prevalent disease in developing countries like India where smoking and environmental pollutants exist almost everywhere. Both family medicine, as well as internist, encounter a lot of patients with acute exacerbation. Hence, it is important for the primary care physician to be able to suspect those rare causes of an acute exacerbation if initial routine care doesn't seem to be effective. Being vigilant to those correctable causes like electrolyte imbalance can help the family physicians in better patient management.

Declaration of patient consent

The authors certify that they have obtained all appropriate patient consent forms. In the form the patient(s) has/have given his/her/their consent for his/her/their images and other

clinical information to be reported in the journal. The patients understand that their names and initials will not be published and due efforts will be made to conceal their identity, but anonymity cannot be guaranteed.

Financial support and sponsorship

Nil.

Conflicts of interest

There are no conflicts of interest.

References

1. Soriano JB, Abajobir AA, Abate KH, Abera SF, Agrawal A, Ahmed MB, *et al.* Global, regional, and national deaths, prevalence, disability-adjusted life years, and years lived with disability for chronic obstructive pulmonary disease and asthma, 1990-2015: A systematic analysis for the Global Burden of Disease Study 2015. *Lancet Respir Med* 2017;5:691-706.
2. van Geffen WH, Bruins M, Kerstjens HA. Diagnosing viral and bacterial respiratory infections in acute COPD exacerbations by an electronic nose: A pilot study. *J Breath Res* 2016;10:036001.
3. Sunyer J, Saez M, Murillo C, Castellsague J, Martinez F, Anto JM. Air pollution and emergency room admissions for chronic obstructive pulmonary disease: A 5-year study. *Am J Epidemiol* 1993;137:701-5.
4. Rao MN, Shoback DM. Hypocalcemia. In: *Endotext* [Internet]. MDText. com, Inc; 2018.
5. Global Initiative for Chronic Obstructive Lung Disease (GOLD). Global Strategy for the Diagnosis, Management and Prevention of Chronic Obstructive Pulmonary Disease: 2019 Report. Available from: www.goldcopd.org.
6. Schafer AL, Shoback DM. Hypocalcemia: Diagnosis and Treatment. In: *Endotext* [Internet]. MDText. com, Inc; 2016.
7. Qin J, Deng X, Wei A, Qin Y, Wu Y, Liao L, Lin F. Correlation between hypocalcemia and acute exacerbation of chronic obstructive pulmonary disease in the elderly. *Postgrad Med* 2019;131:319-23.