

## Severe Pneumomediastinum Complicating EBUS-TBNA

### *To the Editor:*

Pneumomediastinum infrequently complicates diagnostic bronchoscopy. Increased airway or alveolar pressure results in air leaks to the mediastinum through existing or induced defects. Excessive cough, recurrent episodes of increased abdominal pressure, vomiting, or sneezing can all induce spontaneous pneumomediastinum. Less commonly it has been documented with lung or neck infections, esophageal or tracheal tears, and rapid increases in altitude such as during plane flights or scuba diving, with mechanical ventilation, substance abuse, and after bronchoscopy. Pneumomediastinum may be, but is not always, associated with pneumothorax.

We recently evaluated a 63-year-old male patient with a 2-day history of hemoptysis and a left upper-lobe lung mass with hilar adenopathy and a postobstructive process. Flexible white light bronchoscopy showed a normal airway except for an occluded left upper-lobe bronchus with sparing of the lingula. Multiple forceps biopsies were obtained from the apparent endobronchial lesion. Endobronchial ultrasound (EBUS)-

guided lymph node biopsies were obtained from stations 4R, 4L, 7, and 11L. During the procedure there were no complications and no bleeding. The pathology report revealed moderately differentiated squamous cell cancer from only the left upper-lobe endobronchial biopsies.

One day after discharge the patient returned to the emergency room with recurrent severe cough and chest and neck pain associated with increasing swelling of the neck. There was no hemodynamic or respiratory compromise. CT scan of the chest and neck (Fig. 1) to investigate the neck and chest “swelling” showed pneumomediastinum with extensive subcutaneous emphysema with no apparent pneumothorax. The patient was treated with cough suppressants, analgesics, and stool softeners, along with oxygen supplementation through a nasal cannula. The pneumomediastinum and subcutaneous emphysema resolved without any other intervention. The pneumomediastinum was felt to be iatrogenic and was most likely related to the bronchoscopic procedure.

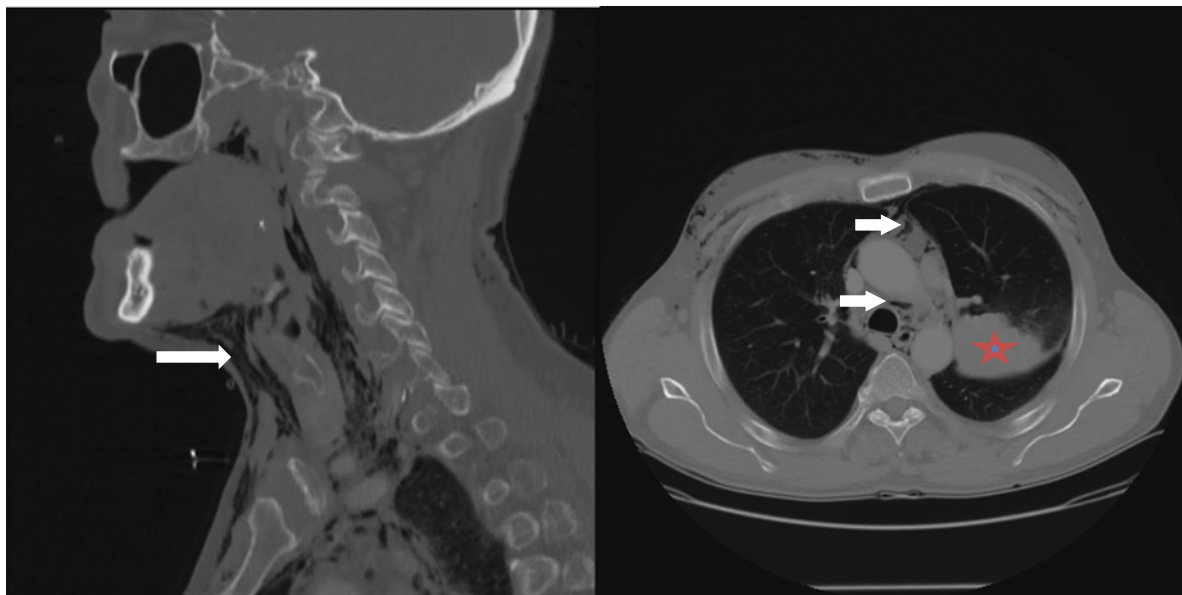
Bronchoscopy with endobronchial ultrasound-guided transbronchial needle aspiration (EBUS-TBNA) is considered to be a very safe procedure and is certainly less invasive than mediastinoscopy or percutaneous needle biopsy. It has been increasingly utilized for the diagnosis of sarcoidosis, for unexplained mediastinal adenopathy, and for lung cancer staging. Complications from EBUS-TBNA are rare. Focal tracheal stenosis secondary to intramural hematoma following EBUS-TBNA has been reported.<sup>1</sup> Barotrauma after ablation techniques has previously been seen.<sup>2</sup>

Pneumothorax was reported in 0.03% (2/7345) of procedures in a survey of 455 facilities in Japan.<sup>3</sup> There was no pneumomediastinum reported. Hemorrhagic and infectious complications were the most common. A review of the AQUIRE registry for complications revealed no reported cases of pneumomediastinum, with a rate of pneumothorax of 0.2% reported among patients who did not undergo transbronchial biopsies.<sup>4</sup> In a comprehensive review of all published articles on endosonography of the mediastinum (EBUS or EUS or their combination) from 1995 to 2012, von Bartheld et al<sup>5</sup> did not report any case of pneumomediastinum. Most complications from this procedure were infectious. EUS was the main risk factor for complications, with 18 of 23 serious complications being observed in this group, compared with EBUS.

To our knowledge, this is the first case of pneumomediastinum that is associated with EBUS-TBNA. It is unlikely that the positive pressure ventilation used during the procedure caused the pneumomediastinum. The procedure was performed through the LMA utilizing general anesthesia but with spontaneous ventilation and 5 cm water pressure support. In addition, the patient presented with pneumomediastinum >24 hours after the procedure, which makes it less likely to be related to the positive pressure and more likely related to a defect created by the procedure in the bronchial wall and exacerbated by cough. Although the direct cause of the pneumomediastinum cannot be certainly established, whether related to the TBNA or to the endobronchial biopsy, we would like to alert other bronchoscopists

Disclosure: There is no conflict of interest or other disclosures.

This is an open-access article distributed under the terms of the Creative Commons Attribution-Non Commercial-No Derivatives License 4.0 (CCBY-NC-ND), where it is permissible to download and share the work provided it is properly cited. The work cannot be changed in any way or used commercially.



**FIGURE 1.** CT scan of the chest and neck showing pneumomediastinum and subcutaneous air (arrows). Lung mass in the left upper lobe (asterisk).

of the potential rare complication and stress upon the fact that conservative therapy should be the first line of treatment. Treatment should be aimed at decreasing intrathoracic pressure spikes by reducing coughing and straining. Oxygen therapy might hasten reabsorption of the subcutaneous nitrogen bubble as it does to a pneumothorax.

**Yousef Shweihat, MBBS,  
FCCP, DAABIP\*†**

**James D. Perry, III, DO\*†  
Nancy Munn, MD, FCCP\*†**

\*Veterans Affairs Medical Center  
†Marshall University  
Huntington, WV

#### REFERENCES

1. Al-Qadi MO, Maldonado F. Focal tracheal stenosis due to intramural hematoma following endobronchial ultrasound-guided transbronchial needle aspiration. *J Bronchology Interv Pulmonol.* 2014;21:274–276.
2. Chua AP, Mehta AC. Barotrauma from novel endobronchial ablation techniques. *J Bronchology Interv Pulmonol.* 2009;16:75–77.
3. Asano F, Aoe M, Ohsaki Y, et al. Complications associated with endobronchial ultrasound-guided transbronchial needle aspiration: a

nationwide survey by the Japan Society for Respiratory Endoscopy. *Respir Res.* 2013;14:50.

4. Eapen GA, Shah AM, Lei X, et al. Complications, consequences, and practice patterns of endobronchial ultrasound-guided transbronchial needle aspiration: results of the AQuIRE registry. *Chest.* 2013;143:1044–1053.
5. von Bartheld MB, van Breda A, Annema JT. Complication rate of endosonography (endobronchial and endoscopic ultrasound): a systematic review. *Respiration.* 2014;87:343–351.

### Use of Self-expanding Metallic Airway Stents in Tracheobronchomalacia

#### To the Editor:

Airway stents have evolved in design, material, and

S.O.: conception and design, analysis and interpretation of data, authoring/revising the article. G.Z.C. and E.F.: conception and design, analysis and interpretation of data, revising the article. A.M.: conception and design, acquisition, analysis and interpretation of data, and revising the article.

Disclosure: E.F. has served as scientific advisor for Boston Scientific. There is no conflict of interest or other disclosures for the other authors.

applications. Predominantly used in the treatment of central airway obstruction, the 2 types of stents, silicone and metal (fully covered, partially covered, and uncovered), offer different advantages and disadvantages. Silicone stents suffer from mucus plugging, high rate of migration, and inability to conform to tortuous airways, and require rigid bronchoscopy for deployment. However, they are less expensive and are relatively easy to remove. Self-expanding metallic airway stents (SEMAS) have less mucus plugging, less incidence of migration, better conform to tortuous airways, and can be easily deployed using flexible or rigid bronchoscopy. However, when left for a prolonged period of time, SEMAS are significantly harder to remove, with increased potential for complications.<sup>1,2</sup> Because of these considerations, FDA has recommended that silicone stents be used as first line in the treatment of benign airway disease, and SEMAS as the last resort or for palliation of malignant airway obstruction.<sup>3</sup>