




Contents lists available at ScienceDirect

## Acta Orthopaedica et Traumatologica Turcica

journal homepage: <https://www.elsevier.com/locate/aott>

## A comparison of rat degloving injury models

Serdar Altun<sup>a,\*</sup>, Hakan Orbay<sup>b</sup>, Mehmet Ekinçi<sup>a</sup>, Ahmet Cetinbas<sup>a</sup>, Ali Bal<sup>a</sup>,  
Enver Arpacı<sup>c</sup>, Mehmet İhsan Okur<sup>a</sup><sup>a</sup> Firat Üniversitesi Tıp Fakültesi, Department of Plastic Surgery, Elazığ, Turkey<sup>b</sup> University of California – Davis Medical Center, Department of Surgery, Division of Plastic Surgery, Sacramento, CA, USA<sup>c</sup> Başkent Üniversitesi, Konya Uygulama ve Araştırma Hastanesi, Department of Plastic Surgery, Konya, Turkey

## ARTICLE INFO

## Article history:

Received 12 July 2016

Received in revised form

26 September 2016

Accepted 19 March 2017

Available online 25 April 2017

## Keywords:

Degloving injury

Rat

Tail

Hindlimb

## ABSTRACT

**Objective:** Two different rat models for degloving injury were described in the literature. Our aim in this study is to compare these rat models to determine which one is more reliable and reproducible.**Methods:** We surgically induced degloving injury on tails and left hindlimbs of Wistar albino rats (n = 8), and sutured the avulsed tissues back in their original positions after a waiting period. We observed the changes in the avulsed flaps every other day for 10 days. At the end of follow-up period we evaluated the lesions in avulsed flaps by macroscopic measurement of necrosis and histological ulcer scoring using the National Pressure Ulcer Advisory Panel (NPUAP) Scale.**Results:** The average length of necrosis in avulsed tail flaps was 28.42 ± 3.04 mm, whereas there was no necrosis in avulsed hindlimb flaps (p < 0.05). The average ulcer score of the lesions in tail and left hindlimb were 3.42 ± 0.78, and 1.28 ± 0.48, respectively (p < 0.05). Despite the lack of visible necrosis TUNEL staining revealed an increased amount of apoptotic cells in avulsed hindlimb flaps. Literature review revealed a significant variability in previous studies in terms of the amount of necrosis observed in tail degloving injury model.**Conclusion:** Tail degloving injury model proved to be a more reliable animal model for degloving injuries. However, standardization of the magnitude of degloving force is required to decrease the variability of necrosis observed in the literature.© 2017 Turkish Association of Orthopaedics and Traumatology. Publishing services by Elsevier B.V. This is an open access article under the CC BY-NC-ND license (<http://creativecommons.org/licenses/by-nc-nd/4.0/>).

## Introduction

Degloving (avulsion) injury is defined as the separation of the skin and subcutaneous tissues from the underlying deep fascia.<sup>1,2</sup> The most common emergency treatment of degloving injury is suturing the avulsed tissue back in its original anatomical position. Despite the treatment, the outcome is usually partial or total necrosis of the avulsed tissue since the subcutaneous vascular plexus nourishing the overlying tissue is injured.<sup>1,2</sup> Experimental studies focusing on the treatment of degloving injuries used two different rat models for degloving injury: the tail degloving injury model described by Oztuna et al,<sup>3</sup> and the hindlimb degloving injury

model described by Milcheski et al.<sup>4</sup> For an objective evaluation of the effects of different treatment methods, experimental degloving injury models should be reliable and easily reproducible. More specifically the extent of skin necrosis should be similar in all animals that are subjected to the same method of degloving injury.

Our aim in this study is to compare the previously described rat models for degloving injury in terms of reliability and reproducibility. We induced degloving injuries in rat tails and hindlimbs and measured the amount of tissue necrosis in each model. We also examined and compared the degloved tissues histologically.

## Materials and methods

All the animal experiments were approved by Institutional Animal Care and Use Committee (protocol # 2015-43). We created degloving injury in both tails and left hindlimbs of Wistar albino rats (n = 8) under anesthesia induced by intraperitoneal (ip.) injection of a mixture of 50 mg/kg Ketamine Hydrochloride (Ketalar<sup>®</sup>, Pfizer, İstanbul), and 10 mg/kg Xylazine (Rompun<sup>®</sup>, Bayer, İstanbul).

\* Corresponding author. Firat Üniversitesi Tıp Fakültesi Hastanesi, Plastik Cerrahi Anabilim Dalı, Merkez/Elazığ, Turkey.

E-mail addresses: [saltun@firat.edu.tr](mailto:saltun@firat.edu.tr), [serdaralt@gmail.com](mailto:serdaralt@gmail.com) (S. Altun).

Peer review under responsibility of Turkish Association of Orthopaedics and Traumatology.

## Surgical technique

### Tail degloving injury model

We performed a circular incision of skin and subcutaneous tissue 5 cm distal to the root of tail protecting underlying tendon and vascular structures as described previously.<sup>3</sup> Then, we applied a traction force to the tail distal to the incision using thumb and index fingers, avulsing the skin and subcutaneous tissue 3 cm distally (Fig. 1A). We preserved the distal subcutaneous attachments of the tail skin. After 15 min, we sutured the avulsed tissue back in its original position using 5/0 polypropylene suture (Prolene®, Ethicon Inc., Somerville, NJ).

### Hindlimb degloving injury model

We first performed a circular incision of skin and subcutaneous tissue in proximal left hindlimb following inguinal and gluteal creases. Afterwards, we avulsed the skin down to the ankle joint using a surgical towel clamp as described previously (Fig. 1B).<sup>4</sup> We sutured the resultant distally based avulsed flap in its original position 5 min later using 5/0 polypropylene suture (Ethicon Inc.).

### Data collection

Postoperatively, we applied povidone/iodine solution (Batticon, ADEKA, İstanbul) to the surgical wounds to prevent infection. We survived the animals until postoperative day 10. We observed the changes in the avulsed flaps every other day, and took pictures of the avulsed flaps under general anesthesia. On postoperative day 10, we measured the longest distance between incision and tip of necrotic skin using a ruler in tails and left hindlimbs of the animals. We considered warm, pink-white and pliable tissue as viable skin; and brown-black, cold and hardened tissue as necrotic skin.

Following measurements, we removed the avulsed flaps as a single circular block for further histologic examination. We fixed the tissues in 10% neutral buffered formalin and kept them in 5% formic acid until further processing. Following routine histopathological preparation, we cut the embedded tissues into 5 µm thick sections and stained the sections with Hematoxylin-Eosin (HE) stain. The stained sections were evaluated under light microscope by an experienced pathologist blinded to the study. The tissue lesions were scored using National Pressure Ulcer Advisory Panel (NPUAP) Scale (Table 1).<sup>5</sup>

Additionally, we performed TUNEL Assay in tissue sections to evaluate the extent of apoptosis. We cut the embedded tissues into 5–6 µm thick sections and transferred the sections to polylysine coated histologic slides. We stained the apoptotic cells using ApopTag Plus Peroxidase InSitu Apoptosis Detection Kit (S7101, Chemicon, MA) following the manufacturer's instructions. Briefly, we deparaffinized the sections using decreasing concentrations of

**Table 1**  
Pressure ulcer definition and stages.

Stage	Histological findings
0	Normal skin
1	Visible inflammation but intact skin with non-blanchable redness of a localized area.
2	Partial thickness loss of dermis presenting as a shallow open ulcer
3	Full thickness tissue loss. Subcutaneous fat may be visible but bone, tendon or muscle are not exposed
4	Full thickness tissue loss with exposed bone, tendon or muscle

xylene and alcohol. We incubated the slides with 0.05% proteinase K solution for 10 min followed by %3 hydrogen peroxide solution for 5 min to prevent endogenous peroxidase activity. Following phosphate buffered saline (PBS) wash, we incubated the slides first with Equilibration Buffer for 6 min, and then with a working solution (%70 µl Reaction Buffer + %30 TdT Enzyme) at 37 °C for 60 min in a humid chamber. We incubated the slides with Stop/WashBuffer for 10 min, and anti-digoxigenin-peroxidase for 30 min. We used diaminobenzidine (DAB) enzyme substrate to stain the apoptotic cells and counterstained the nuclei with Harris Hematoxylin prior to coverslipping the slides. The stained sections were evaluated by a Novel N-800M microscope by an experienced pathologist blinded to the study.

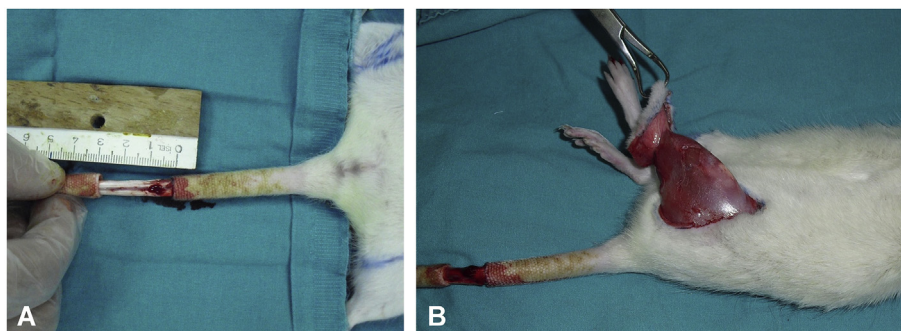
### Statistical analysis

Statistical analysis was performed by Student's t test using SPSS statistical software 18.0. Statistical significance was set at  $p < 0.05$ .

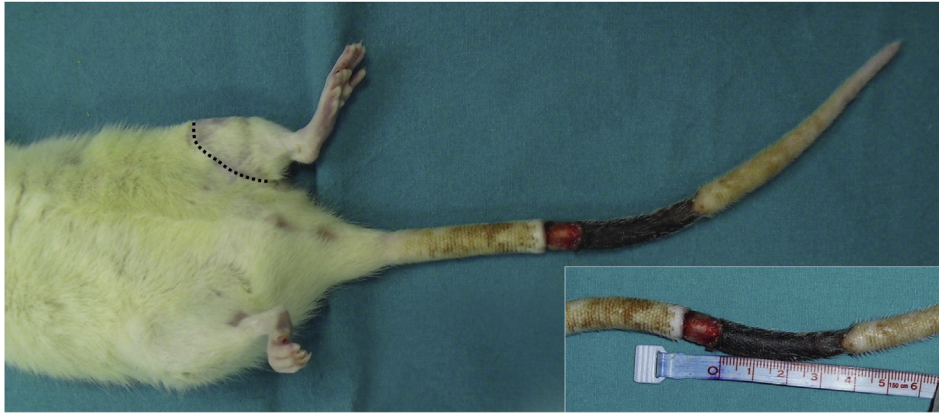## Results

All animals survived until the study endpoint. Avulsed tail flaps were cyanotic, and distal tail segments were edematous in all animals on postoperative day 2. The cyanosis in the avulsed tail flaps progressed and we observed a full thickness necrosis by postoperative day 10 (Fig. 2). On the other hand, there was a mild cyanosis along the incision lines in avulsed hindlimb flaps on postoperative day 2 which disappeared totally on postoperative day 4. We did not observe any surgical wound infection but there was a partial dehiscence in one hindlimb wound which healed by secondary intention. We also observed a total wound dehiscence measuring 4 mm in the tails of two rats secondary to full thickness necrosis of the skin. The average length of necrosis in avulsed tail flaps was  $28.42 \pm 3.04$  mm, whereas there was no necrosis in avulsed hindlimb flaps ( $p < 0.05$ ) (Fig. 3).

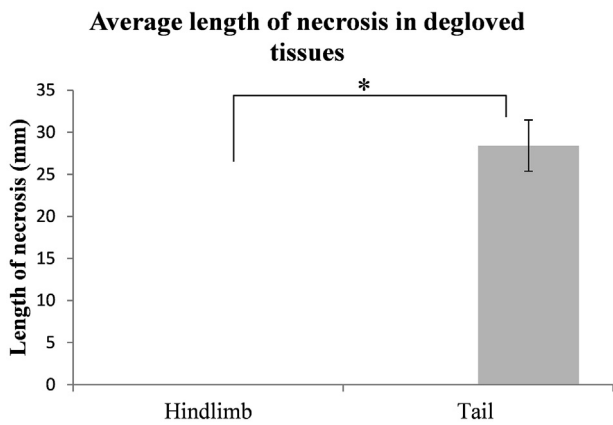
Histologically, we observed full thickness epidermal loss and ulceration accompanied by a heavy inflammatory infiltrate in the



**Fig. 1.** A) A 3 cm long avulsed tail flap and the underlying tendon and dorsal vascular structures. B) Degloved hindlimb flap following a proximal circumferential incision.

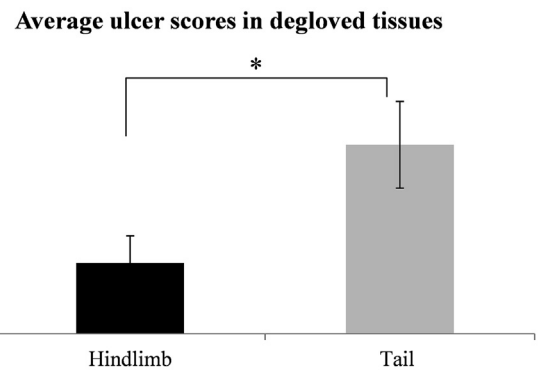


**Fig. 2.** The figure shows an avulsed tail flap with total necrosis and secondary wound dehiscence. The smaller inset shows the measurement of the length of necrosis. There was no necrosis on the avulsed hindlimb flap on the same animal. Dashed black line marks the previous incision line.



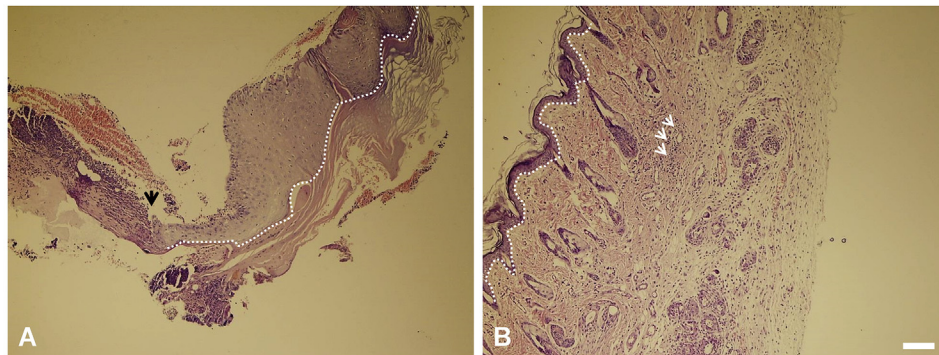
**Fig. 3.** The graph shows the average length of necrosis in avulsed hindlimb and tail flaps by day 10 after the induction of degloving injury. There was no visible necrosis in hindlimb flaps. \* $p < 0.05$ .

necrotic tail flaps (Fig. 4A). The histological findings in the avulsed hindlimb flaps were epidermal thinning, fibrosis in the superficial layer of dermis, mild widening in collagen bands and perivascular lymphocyte infiltration (Fig. 4B). These findings were compatible with early stages of wound healing. The average ulcer score of the lesions in tail and left hindlimb were  $3.42 \pm 0.78$ , and  $1.28 \pm 0.48$ , respectively ( $p < 0.05$ ) (Fig. 5).



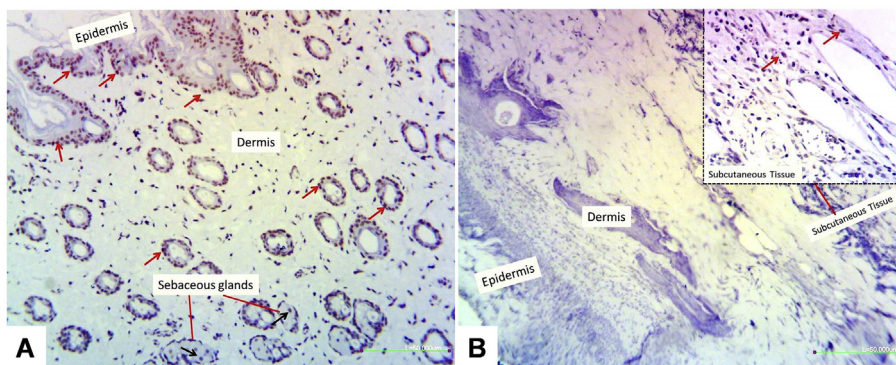
**Fig. 5.** The graph shows the average ulcer scores in the avulsed hindlimb and tail flaps. The ulcer scores in tail wounds were significantly higher than hindlimb wounds. \* $p < 0.05$ .

The microscopic examination of the slides stained with TUNEL method revealed an increased staining in epidermis, dermis and sebaceous glands in avulsed hindlimb flaps despite the lack of visible necrosis (Fig. 6A). There was no TUNEL positivity in epidermal and dermal layers of the avulsed tail flaps most likely due to necrosis. However, apoptotic cells were observed in the subcutaneous layer (Fig. 6B).



**Fig. 4.** A) Histological appearance of avulsed tail flap. Black arrow marks the transition between the ulcer with full-thickness epidermal loss (left), and the edge of the ulcer with epidermal hypertrophy (right). Dashed white line marks the inferior border of epidermis. B) Histological appearance of the avulsed hindlimb flap. White arrows mark the perivascular lymphocyte infiltration, and dashed white line marks the inferior border of epidermis. Microbars 100  $\mu$ m.





**Fig. 6.** A) TUNEL staining of the avulsed hindlimb flaps revealed increased staining in the epidermis, dermis (red arrows) and sebaceous glands (black arrow). B) TUNEL positivity was limited only to subcutaneous tissue in avulsed tail flaps as shown in inset figure (red arrows). Microbars 50  $\mu$ m.

## Discussion

The first animal model for degloving injury was described by Kurata et al, in 1978.<sup>6</sup> However, this study was performed on rabbits, hence not discussed in this paper. The first rat model for degloving injury was described by Oztuna et al in 2006.<sup>3</sup> The authors induced a 3 cm long avulsion injury in the tails of rats and examined the effects of pentoxifylline on the viability of avulsed flaps. Another degloving injury model was described by Milcheski et al in rat hindlimb.<sup>7</sup> The authors described four different types of hindlimb degloving injury in this study: proximal flow pedicled flap, distal flow pedicled flap, lateral flow pedicled flap, and medial flow pedicled flap.<sup>7</sup> They used this animal model in a subsequent study to examine the effects of pentoxifylline and allopurinol on the viability of avulsed hindlimb flaps.<sup>4</sup> Additional studies used different drugs to improve the viability of avulsed flaps using either a hindlimb or tail model of degloving injury; however, none of these studies scrutinized the reproducibility of these animal models.<sup>8–10</sup> In this study, we addressed this gap in the literature by comparing two known rat models for degloving injury. We used only a distally based flap in hindlimb degloving injury model since this flap had the highest amount of necrosis in the study performed by Milcheski et al.<sup>7</sup>

Tail degloving injury model has been used more than hindlimb degloving injury model in the literature,<sup>3,8–10</sup> but the hindlimb model is potentially a more clinically relevant model considering the fact that degloving injuries are most commonly seen in lower extremities in clinic.<sup>1</sup> However, we failed to observe necrosis in the avulsed hindlimb flaps in our study even though we followed the same surgical procedure described by Milcheski et al.<sup>7</sup> On the other hand, we consistently observed necrosis in avulsed flaps in tail degloving injury model which proved to be a more reliable model in our hands.

The lack of necrosis in hindlimb degloving injury model can be attributed to plasmatic imbibition from the underlying muscle tissue contributing to the survival of degloved hindlimb flaps. Osmosis of the nutrients from the underlying well vascularized tissues can maintain the viability of thin tissues until the new vessel in-growth is complete. This phenomenon is known as “plasmatic imbibition” and frequently observed in case of skin grafts placed on well vascularized muscles.<sup>11</sup> Plasmatic imbibition is expected to occur less in avulsed tail flaps because of the relatively avascular nature of the underlying structures, such as tendon and bone, hence explaining the increased necrosis in avulsed tail flaps. Additionally, degloving injuries in clinical cases are usually accompanied by crush injury due to the force applied on the tissues.<sup>1,2</sup> Crush injury exacerbates the vascular compromise and

increases the tissue necrosis in clinical cases.<sup>12</sup> In hindlimb degloving injury model, the avulsion of the flap is caused solely by traction using a towel clamp and there is almost no crushing force applied on the tissues. On the other hand, in the tail degloving injury model a significant amount of crushing force is applied to the tissues by fingers during the process of avulsion. Therefore, tail degloving injury model more closely resembles the clinical case of degloving injury in terms of the mechanism of injury if not the location of injury. Another interesting finding of this study was the increased apoptosis in avulsed hindlimb flaps despite the lack of visible necrosis. Based on this finding, we believe that hindlimb degloving injury model can potentially be used as an apoptosis model.

We observed a significant variability in the extent of flap necrosis in tail degloving injury model when we compared our results with the literature. Demirtaş et al, reported a necrosis length of  $7.87 \pm 3.31$  mm,<sup>10</sup> whereas Azboy et al,<sup>8</sup> and Cebesoy et al,<sup>9</sup> reported necrosis lengths of  $14 \pm 5$  mm and  $10.2$  mm respectively. The extent of necrosis in our study was higher with a length of  $28.42 \pm 3.04$  mm in comparison to previous studies. This difference can be explained by the variability in the magnitude of degloving force. Currently, degloving force is applied manually using index finger and thumb. The development of a system to deliver a standard magnitude of degloving force may decrease this variability.

## Conclusion

Tail degloving injury model is a more reliable animal model for degloving injuries even though hindlimb degloving injury model may seem to be more clinically relevant. However, further refinement of the hindlimb model is required to standardize the magnitude of degloving force applied on the tissues.

## Financial support

None of the authors has a financial interest in any of the products, devices, or drugs mentioned in this manuscript.

No products, devices or drugs are used in this manuscript.

## References

1. Latifi R, El-Hennawy H, El-Menyar A, et al. The therapeutic challenges of degloving soft-tissue injuries. *J Emerg Trauma Shock*. 2014;7:228–232.
2. Harold B, Sadri A. Good practice in the management of serious degloving injuries. *Emerg Nurse*. 2013;21:30–33. quiz 35.
3. Oztuna V, Eskandari MM, Unal S, Colak M, Karabacak T. The effect of pentoxifylline in treatment of skin degloving injuries: an experimental study. *Injury*. 2006;37:638–641.

4. Milcheski DA, Nakamoto HA, Tuma Jr P, Nobrega L, Ferreira MC. Experimental model of degloving injury in rats: effect of allopurinol and pentoxifylline in improving viability of avulsed flaps. *Ann Plast Surg.* 2013;70:366–369.
5. Pressure ulcers prevalence, cost and risk assessment: consensus development conference statement—The National Pressure Ulcer Advisory Panel. *Decubitus.* 1989;2:24–28.
6. Kurata T, O'Brien BM, Black MJ. Microvascular surgery in degloving injuries: an experimental study. *Br J Plast Surg.* 1978;31:117–120.
7. Milcheski DAFM, Nakamoto HA, Tuma Jr P. Development of an experimental model of degloving injury in rats. *Rev Bras Cir Plást.* 2012;27:514–517.
8. Azboy I, Demirtas A, Bulut M, et al. Effects of enoxaparin and rivaroxaban on tissue survival in skin degloving injury: an experimental study. *Acta Orthop Traumatol Turc.* 2014;48:212–216.
9. Cebesoy O, Isik M, Erzincan T, et al. Analysis of the effects of heparin and enoxaparin on degloving injuries. *Bratisl Lek Listy.* 2014;115:550–553.
10. Demirtas A, Azboy I, Bulut M, et al. Effect of hyperbaric oxygen therapy on healing in an experimental model of degloving injury in tails of nicotine-treated rats. *J Hand Surg Eur Vol.* 2013;38:405–411.
11. Kelly CP, Gupta A, Keskin M, Jackson IT. A new design of a dorsal flap in the rat to study skin necrosis and its prevention. *J Plast Reconstr Aesthet Surg.* 2010;63:1553–1556.
12. Jeng SF, Hsieh CH, Kuo YR, Wei FC. Technical refinement in the management of circumferentially avulsed skin of the leg. *Plast Reconstr Surg.* 2004;114:1225–1227.