



Andrology and fertility

Persistent Mullerian duct syndrome with intra-abdominal seminoma

Ali Al-Asmar^{*}, Adnan Abu-Qamar, Nizar Al-saidah, Awad Al-Kaabneh, Ayman Al-Qaralleh, Ahmad Al-Hiari

The Department of Urology, KHMC, King Abdullah II Street, Amman-Jordan, Jordan



ARTICLE INFO

Keywords:

Persistent mullerian duct
Seminoma
Malignancy
Cryptorchidism

ABSTRACT

Persistent Mullerian duct syndrome (PMDS) is a rare form of male pseudohermaphroditism; it is defined by the presence of the Mullerian duct derivatives (the uterus, the fallopian tubes, and the upper vagina) in genotypically and phenotypically males. Seminoma is the most common type of testicular tumor in the third and fourth decade of life. We report a case of intra-abdominal seminoma in a patient with bilateral undescended testes and persistent Mullerian duct syndrome.

Introduction

PMDS is characterized by the presence of uterus, fallopian tubes, and upper part of vagina in genotypically and phenotypically males.¹

It is caused either by a defect in the production of the *anti*-Mullerian hormone (AMH) or by a defect in the AMH receptor.²

The first time it was originally described was in the year 1939 by Nilsson.³

This syndrome is very rare as there are no more than 150 cases described in the literature.⁴

It is usually detected in patients who are evaluated for infertility, cryptorchidism, or during intra-abdominal surgery.

Patients with PMDS are **at high** risk for testicular neoplasm **equal to** patients with cryptorchidism. Embryonal carcinoma, seminoma, and yolk sac tumors are described in patients who are presented with PMDS.

We report a case of PMDS with intra-abdominal seminoma.

Case presentation

A 29-year-old male was presented to the urology clinic; he was complaining of primary infertility since marriage for more than 3 years. He has no past medical or surgical history; moreover, he has normal sexual history and normal intercourse; this is according to the facts he presented about his own case.

Upon examination, he has a normal, well developed penis, empty scrotal sac, and normal hair distribution; there were no surgical scars.

The Patient was sent to the radiology department in order to have an abdominal and pelvic ultrasound where he was found to have a large

right sided abdominal mass mostly of testicular origin.

The Patient underwent an abdominal and pelvic CT scan which revealed the presence of a 10 × 8 cm mass lesion in the right iliac fossa, representing a mass lesion arising from the right intra-abdominal testis.

The AFP and The B-HCG were within normal levels.

A decision for laparotomy for mass excision was taken. During laparotomy, a uterus, fallopian tubes, and upper vagina were found beside the presence of a small size left testis and large mass lesion from the right testis.

As seen in Fig. 1 and Fig. 2.

A decision was taken to excise the right testicular mass, the uterus, and both the fallopian tubes, the upper vagina and the left testis after taking the permission from the patient's family. Excised specimens were sent to histopathology.

The Patient was discharged few days later; he was in a good health and active.

A lifelong androgen supplementation was prescribed to the patient.

The histopathology report revealed the presence of left atrophied testis, a well-developed endocervix, atrophic endometrium and myometrium, identified fallopian tubes, no ovarian tissues, and right testicular **seminoma T1N0M0** as in Fig. 3a and b.

The chromosomal study of the patient revealed that he is a 46 xy. Our diagnosis after the collection of all data was of PMDS.

Discussion

PMDS is characterized by the presence of Mullerian duct derivatives (the uterus, the fallopian tubes, and the upper vagina) in phenotypically

^{*} Corresponding author.

E-mail address: layanalis@yahoo.com (A. Al-Asmar).

<https://doi.org/10.1016/j.eucr.2020.101342>

Received 17 June 2020; Received in revised form 7 July 2020; Accepted 8 July 2020

Available online 14 July 2020

2214-4420/© 2020 The Authors.

Published by Elsevier Inc.

This is an open access article under the CC BY-NC-ND license

(<http://creativecommons.org/licenses/by-nc-nd/4.0/>).

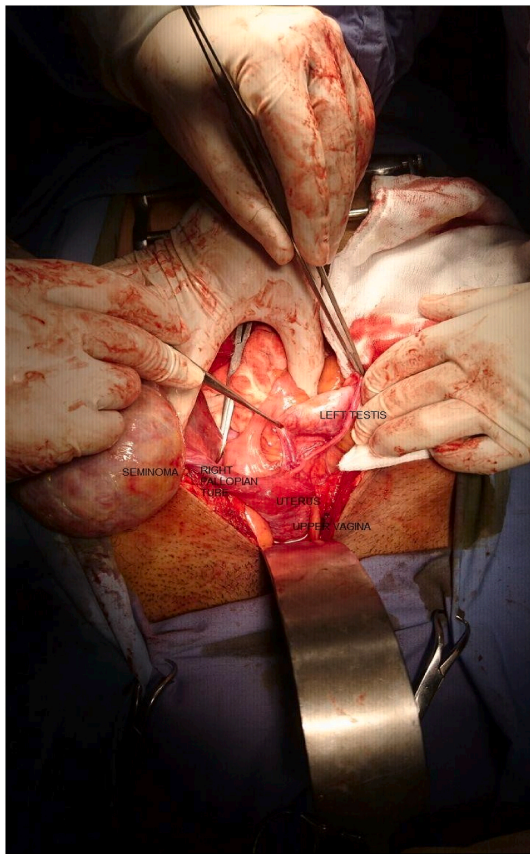


Fig. 1. Mullerian duct derivatives beside right seminoma and left testis.

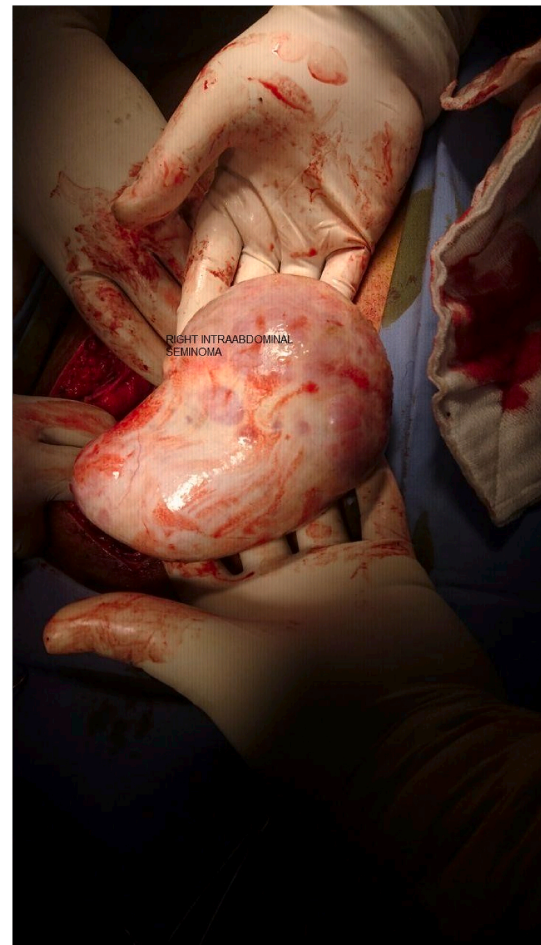


Fig. 2. Right intra-abdominal seminoma.

and genotypically males. It is the result of a defect in the production of the AMH or a defect in the AMH receptor function. The AMH is produced by sertoli's cells which are responsible for the regression of the Mullerian duct that occurs in male fetus at 8–10 weeks of the gestational age.⁵

The PMDS is usually presented in two forms: the male form³ which is also called hernia uteri inguinal which is seen in 80–90% of cases; in this form, one testis is seen in the scrotum, while the uterus, the fallopian tubes and sometimes the other testis are seen in the inguinal canal down to scrotum.

The other form is the female type, as in our case, it is characterized by a bilateral cryptorchidism, and both testes are attached to broad ligaments as in the normal ovarian position.

The PMDS has no effect on the external genitalia development that is why the diagnosis is usually delayed until surgery either for orchidopexy or for excision of intra-abdominal mass lesions as in our case.

Patients with PMDS are at higher risk of testicular malignancy as in patients with isolated undescended testis. Seminoma is the most common type, followed by embryonal carcinoma, teratocarcinoma and choriocarcinoma.

On the other hand, there are no documented studies about the risk of malignancy of the Mullerian duct derivatives in PMDS.

The Diagnosis of PMDS depends on clinical, radiological and operative evaluation, beside the 46 xy genetic karyotyping.

Infertility is a common problem in patients with PMDS as in our case. Few cases of PMDS were found to be fertile and had siblings prior to diagnosis.

The main goal of management for patients with PMDS is either for fertility or prevention of malignancy.

Orchidopexy, herniorrhaphy, hysterectomy, and bilateral salpingectomy is the treatment of choice in cases of infertility.

On the other hand, orchidectomy is the treatment of choice if malignancy is suspected in immobilized, small testis.⁵

In our case, the decision for the right sided mass lesion excision, the hysterectomy, the bilateral salpingectomy, the left orchidectomy, and the excision of the upper vagina was taken in combination by urology and gynecology team even though the risk of malignancy in the Mullerian duct derivative is very rare.

Conclusion

PMDS is a rare form of male pseudohermaphroditism because of its rarity; it is usually diagnosed in combination of clinical, radiological and surgical findings. It should be taken in concern when dealing with patients who are presented with abdominal masses and cryptorchidism.

Patients with PMDS are at higher risk for malignancy, where seminoma is the most common type.

Surgery is the treatment of choice in case of mass lesion and possibility of malignancy. Excision of the Mullerian duct derivatives is recommended.

The patient's consent

Consent to publish the case report was not obtained. This report does not contain any personal information that could lead to the identification of the real identity of the patient.

Funding

No funding or grant support Authorship.

All authors attest that they meet the current ICMJE criteria for authorship.

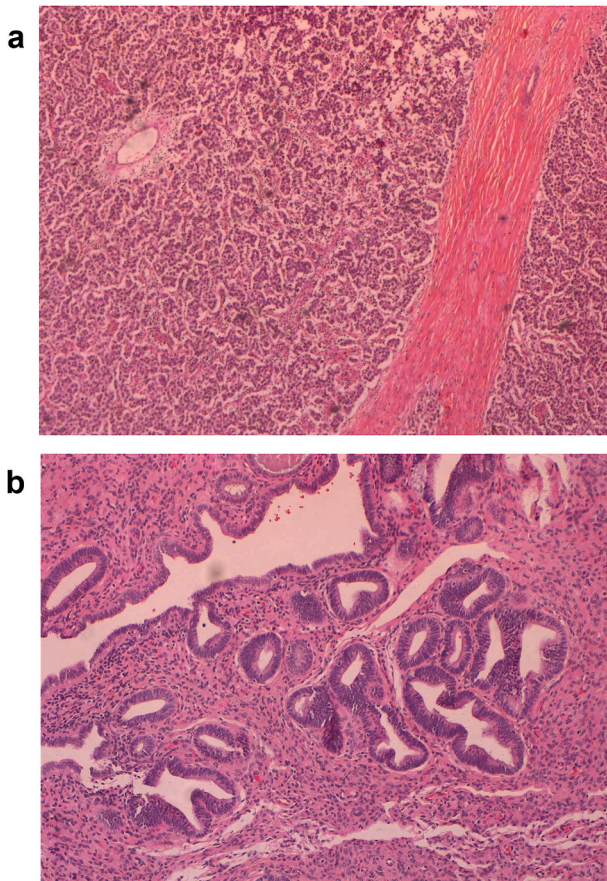


Fig. 3. (a+b)".

a- This image shows proliferation of sheets of relatively uniform tumor cells are divided into poorly demarcated lobules by delicate fibrous septa containing lymphocytes and plasma cells.

b- This image shows the uterine cavity with inactive endometrium.

Declaration of competing interest

None.

Acknowledgement

Additional authors who participated in this study are: *Rami Shwayat MD², Njood Al-Taleb MD², Omar Al- Elwan MD², Sana'a Al-Saidat MD³, Sura Al-Rawabdeh MD³*: 1: The DEPARTMENT OF UROLOGY, KHMC, 2: The DEPARTMENT OF GYNECOLOGY AND OBSTETRICS, KHMC, 3: PRINCESS IMAN BINT ALHUSSIEEN LABORATORY AND RESEARCH CENTER, KHMC.

References

1. Renu D, Rao BG, Ranganath K, Namitha. Persistent mullerian duct syndrome. *Indian J Radiol Imag.* 2010;20:72–74.
2. Josso N, Belville C, di Clemente N, Picard JY. AMH and AMH receptor defects in persistent mullerian duct syndrome. *Hum Reprod Update.* 2005;11:351–356.
3. Nilson O. Hernia uteri inguinalis beim Manne. *Acta Chir Scand.* 1939;83:231–249.
4. Deepika Kumar A. Persistent Mullerian duct syndrome with transverse testicular ectopia: rare entity. *J Clin Diagn Res.* 2014;8:162–163.
5. Jost A. Problems of fetal endocrinology: the gonadal and hypophyseal hormones. *Recent Prog Horm Res.* 1953;8:379–418 ([Google Scholar]).