



Case Report

A case of cardiac resynchronization therapy in a patient with coronary sinus ostial atresia and persistent left superior vena cava



Kosuke Fujibayashi (MD)*, Yasuhiko Saeki (MD), Jun Sawaguchi (MD), Yuushi Yasuda (MD), Eiichi Ueno (MD), Shintaro Takano (MD), Nakaba Fujioka (MD), Yasuyuki Kawai (MD), Kouji Kajinami (MD)

Department of Cardiology, Kanazawa Medical University, Ishikawa, Japan

ARTICLE INFO

Article history:

Received 11 June 2019

Received in revised form 15 October 2019

Accepted 26 October 2019

Keywords:

Coronary sinus ostial atresia

Persistent left superior vena cava

Cardiac resynchronization therapy

ABSTRACT

Coronary sinus ostial atresia is rare and usually not clinically relevant, but it should be noted in cases of cardiac resynchronization therapy. A rare case of successful left ventricular lead implantation for cardiac resynchronization therapy via the left superior vena cava in a patient with coronary sinus ostial atresia is reported. The persistent left superior vena cava associated with these cases tends to be smaller than usual in its diameter and difficult to identify, since the direction of venous drainage is reversed. Therefore, in the present case, it was useful to use a small-diameter, soft inner catheter as a guiding catheter to perform selective imaging and avoid vascular injury. In addition, it appeared to be important to plan the surgical strategy using prior imaging information, since it would be difficult to obtain the backup needed for lead insertion.

(; **Learning objective:** Cardiac resynchronization therapy via the left superior vena cava with coronary sinus ostial atresia is generally possible without problems if prior imaging information is available, such as three-dimensional computed tomography and the venous phase of coronary angiography. It is important to determine whether there is a persistent left superior vena cava before the procedure. Thromboprophylaxis remains controversial in this situation.)

© 2019 Japanese College of Cardiology. Published by Elsevier Ltd. This is an open access article under the CC BY-NC-ND license (<http://creativecommons.org/licenses/by-nc-nd/4.0/>).

Introduction

Coronary sinus ostial atresia (CSOA) is rare and is divided into two types by the drainage route. The first route is via a persistent left superior vena cava (PLSVC) toward the right superior vena cava through a vertical vein or innominate vein [1]. The other is directly into the atrium through an unroofed coronary sinus or via venous collateral pathways. The diagnosis of CSOA with PLSVC is usually incidental at autopsy, surgery, or cannula insertion into the coronary sinus, and most cases are clinically benign [2,3].

A case of successful left ventricular lead implantation for cardiac resynchronization therapy (CRT) via a PLSVC in a patient with CSOA is reported.

Case report

An 84-year-old man with ischemic cardiomyopathy was implanted with a dual-chamber implantable cardioverter defibrillator (ICD) due to sustained ventricular tachycardia. The ICD lead was inserted with the left subclavian vein approach via the right superior vena cava. He had a history of previous inferior wall myocardial infarction and repeated percutaneous coronary interventions for left anterior descending artery and left circumflex artery stenoses. At the time of admission, he had heart failure graded as New York Heart Association Class III despite optimal pharmacological therapy. Echocardiography showed a low left ventricular ejection fraction of 29%, and the electrocardiogram showed complete left bundle branch block morphology without ventricular pacing. The duration of the QRS complex was 260 ms, indicating the need for CRT.

Previous coronary angiography (CAG) and cardiac contrast computed tomography (CT) showed CSOA and PLSVC; the latter was connected to the innominate vein with a diameter of 3.5 mm (Fig. 1). It was therefore planned to insert a left ventricular lead via

* Corresponding author at: Department of Cardiology, Kanazawa Medical University, 1-1 Daigaku, Uchinada, Kahoku, Ishikawa 920-0293, Japan.
E-mail address: f-kosuke@kanazawa-med.ac.jp (K. Fujibayashi).

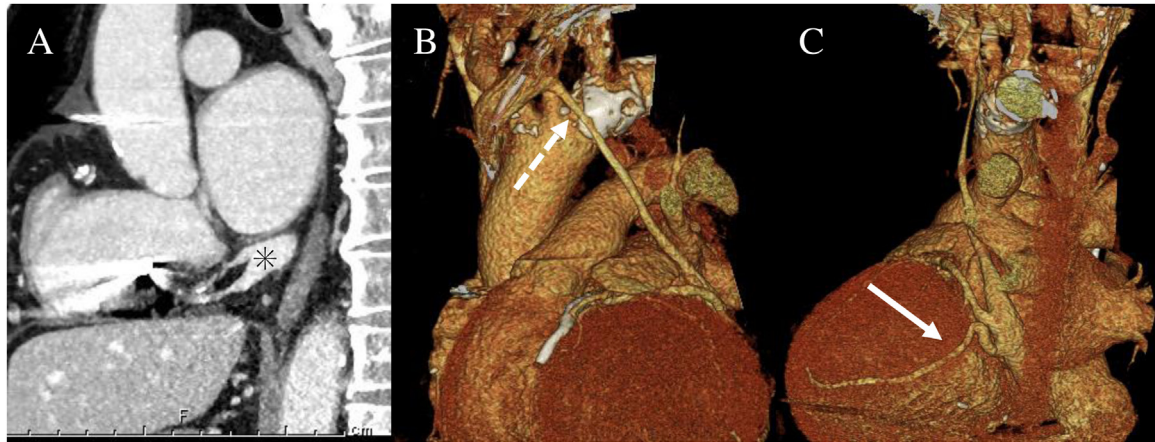


Fig. 1. The coronary sinus ostial atresia and persistent left superior vena cava on contrast-enhanced computed tomography, sagittal plane (A), anterior view (B), and posterolateral view (C) of the three-dimensional image. They show membranous occlusion of the coronary sinus at the ostium (asterisk), the persistent left superior vena cava with a small diameter, approximately 3.5 mm (dashed arrow), and the target lateral vein (solid arrow).

the PLSVC. In the venous phase of the left coronary angiogram, the contrast agent flow of the PLSVC was in the direction toward the innominate vein. The CS drained mostly into the PLSVC and somewhat into the right atrium via an anomalous collateral branch of the CS. An inferior to superior flow direction did not allow us to visualize the PLSVC by a subclavian vein angiogram. To identify the PLSVC, selective imaging using an inner catheter (Attain Select II® 6248VI-90S, Medtronic Inc., Minneapolis, MN, USA) was performed (Fig. 2A and B). Due to the small diameter of the PLSVC, the procedure was advanced without using a guiding catheter, which is usually used in the CRT procedure, to avoid vascular injury. Due to CS dilation, a long reach inner catheter (Attain Select II® 6248VI-90L, Medtronic) was selected to provide the necessary backup to insert the lead (Attain Performa® Straight 4398-88 cm, Medtronic) into the target vein (Fig. 2C). In order to improve fixation of the lead, it was placed so as to crawl inside the CS. The measured voltage, thresholds, and impedance values were within the acceptable ranges. The leads were connected to a CRT-D generator (Claria MRI Quad CRT-D, Medtronic). In this case, CS thrombosis was a major concern, because it may affect coronary blood flow. However, it was decided to observe with other modalities such as venography without anticoagulation therapy because of the high bleeding risk due to the patient's high age and concomitant antiplatelet medication. After discharge, CRT resulted in clinical improvement of the heart failure. Three months after

CRT implantation, coronary vein thrombus was not detected, and coronary blood flow was not impaired on CAG, but left ventricular lead migration was detected in the CS wall (Fig. 3).

Discussion

PLSVC is the most common thoracic venous anomaly. A recent clinical study in a normal population using echocardiography suggested that the frequency of PLSVC was 0.21% [4]. Moreover, PLSVC is frequently observed in patients with congenital heart diseases, with an incidence more than 7.0 times higher than in normal subjects [4]; it usually drains into the right atrium through a dilated CS [5,6].

CSOA is a rare anomaly with a prevalence of about 0.1% [1], and patients with CSOA are commonly asymptomatic [2]. It can be divided into two types, depending on whether it drains to the PLSVC toward the right superior vena cava with a membranous occlusion at the ostium of the CS or drains directly into the atrium.

In the case of CSOA with drainage through the PLSVC, unlike the usual type of PLSVC, it flows retrogradely and has a small diameter because the amount of reflux is small. In such cases, PLSVC blood flow is derived only from coronary venous blood. CSOA with PLSVC is clinically diagnosed by surgery, cannulation of the coronary sinus, or in the venous phase of CAG. It should be noted that PLSVC identification during subclavian vein imaging performed during

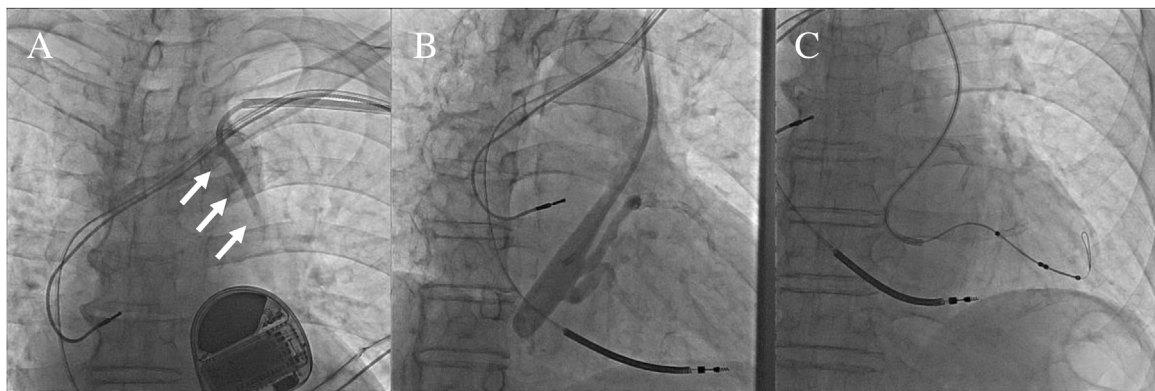
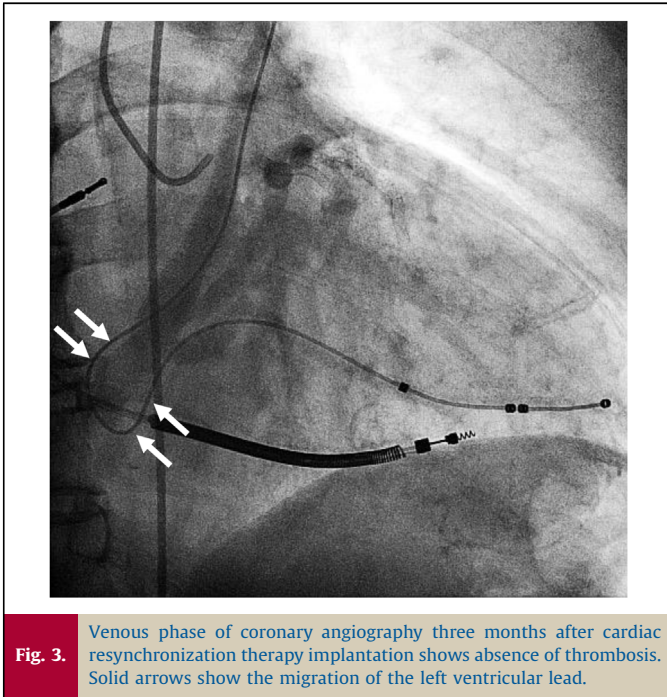


Fig. 2. (A) Selective imaging of the persistent left superior vena cava using an inner catheter. (B) Coronary sinus venogram shows the target branch. (C) Left ventricular lead insertion using a long-reach inner catheter to obtain back-up force.



transvenous implantable electronic cardiac device insertion is difficult. This is particularly important for CRT operations that require left ventricular lead placement, since this affects their success rate. In the present case, selective imaging with a small catheter made it possible to identify the PLSVC during the procedure.

There have been few reports of CRT in CSOA cases [3,7,8]. Wilson et al. reported a case of CRT implantation through a right atrial accessory venous collateral in CSOA cases [7]. In their case, they stated that there was no evidence of PLSVC. However, the supplementary video in their paper showed a small PLSVC. Therefore, it is thought that they could not detect the PLSVC because of its small diameter. In CSOA cases, it is necessary to carefully check for the presence of the PLSVC. In the present case, selective imaging with a small catheter made it possible to identify the PLSVC during the procedure.

Lim et al. reported a case of CRT-D implantation through the PLSVC in a patient with CSOA [8]. They used a Judkins right coronary catheter to cannulate the PLSVC without using a guiding catheter, and it was exchanged for a left ventricular lead. Such an insertion procedure can be difficult due to weak backups. On the other hand, they were concerned about the thrombosis associated with the procedure, but additional thromboprophylaxis was controversial, and they argued the importance of a venogram to ensure that the vessel is sufficiently large to allow the lead to traverse it without causing any compromise in venous flow.

Stevenhagen et al. reported a case of CRT-D implantation through a PLSVC in a patient with CSOA and with a large thrombus at the junction of the CS and the PLSVC [3]. They also used a Judkins right coronary catheter to catheterize the PLSVC. The CS was cannulated via the PLVCS with a 9-Fr standard guide catheter. A 6-Fr inner catheter was selectively positioned in the target branch, and it was then exchanged for a CS lead. Fortunately, they were able to successfully complete the procedure, but there is a risk of

vascular injury from the edges of the guiding catheter with a significantly larger diameter than the PLSVC. They used intravenous and oral anticoagulants for thrombus that was present before surgery.

These three cases were also considered to have similar PLSVC diameters on imaging compared with the cases we treated.

As a technical point related to left ventricular lead insertion, a guiding catheter generally used in CRT was not used in order to prevent vascular injury, because of the small diameter of the PLSVC. Therefore, it was difficult to obtain the backup necessary to advance the left ventricular lead without using a long-reach catheter. Based on our experience, it is useful to obtain contrast-enhanced three-dimensional CT to plan the CRT implantation strategy.

Moreover, to avoid lead dislodgement, in the case of left ventricular lead insertion via the right superior vena cava, backup force is obtained using the right atrium free wall. However, in the present case, since the approach was different, it was necessary to place a lead along the CS wall. Thus, left ventricular lead migration was detected in the CS wall, but fortunately, no further complications have been observed.

In the present case, thromboprophylaxis was not added to antiplatelet drugs to avoid adverse events. CS thrombosis alone may be asymptomatic [3], and it was decided to perform angiography several months after lead implantation and then follow-up with blood clotting tests. The venous phase of CAG indicated the absence of thrombus and no impairment of coronary blood flow.

Although there have been few reports of CRT for CSOA cases with PLSVC, surgery is generally possible without problems if prior imaging information is available. We consider that this abnormality alone should not be a reason for performing CRT surgery by thoracotomy. It is important to examine whether there is a PLSVC before the procedure, and indications for thromboprophylaxis should be investigated in a larger case series.

Conflict of interest

The authors declare that they have no conflict of interest.

References

- [1] Shum JS, Kim SM, Choe YH. Multidetector CT and MRI of ostial atresia of the coronary sinus, associated collateral venous pathways and cardiac anomalies. *Clin Radiol* 2012;67:e47–52.
- [2] Santoscoy R, Walters III HL, Ross RD, Lyons JM, Hakimi M. Coronary sinus ostial atresia with persistent left superior vena cava. *Ann Thorac Surg* 1996;61:879–82.
- [3] Stevenhagen J, Meijer A, Bracke FA, van Gelder BM. Coronary sinus atresia and persistent left superior vena cava with the presence of thrombus complicating implantation of a left ventricular pacing lead. *Europace* 2008;10:384–7.
- [4] Nagasawa H, Kuwabara N, Goto H, Omoya K, Yamamoto T, Terazawa A, et al. Incidence of persistent left superior vena cava in the normal population and in patients with congenital heart diseases detected using echocardiography. *Pediatr Cardiol* 2018;39:484–90.
- [5] Boussuges A, Ambrosi P, Gannier M, Quenee V, Saint JM. Left-sided superior vena cava: diagnosis by magnetic resonance imaging. *Intensive Care Med* 1997;23:702–3.
- [6] Pai RG. Echocardiographic features of persistent left superior vena cava. *Echocardiography* 1999;16:435–6.
- [7] Wilson D, Ahmed N, Sun P, Diab I. Successful transvenous cardiac resynchronization therapy in a case of coronary sinus ostial atresia. *Eur Heart J* 2017;38:477.
- [8] Lim PC, Baskaran L, Ho KL, Teo WS, Ching CK. Coronary sinus ostial atresia and persistent left-sided superior vena cava: clinical significance and strategies for cardiac resynchronization therapy. *Int J Angiol* 2013;22:199–202.