

Craniopagus twins for magnetic resonance imaging

Sir,

Conjoined twins are identical twins whose bodies are joined in utero. It is a rare phenomenon; it is estimated to range from 1 in 50,000 births to 1 in 200,000 births.^[1] They are identical twins (monozygotic and monochorionic) who develop with a single placenta from a single fertilized ovum. They are always the same sex and race. Approximately 75% of conjoined twin pairs are females. They are at a ratio of female to male 3:1. Of these, about 40% were stillborn and 60% live-born although only about 25% of those that survived to birth lived long enough to be candidates for surgery.^[2]

Conjoined twins are usually classified by the point at which they are joined (pagos). In craniopagus, there is cranial union only. Various forms and orientations of fusion may be seen, with both neural and major vascular connections. There is a high risk of brain damage. Other varieties are thoracopagus, omphalopagus, and pygopagus. Anesthetic concerns for conjoined twins are such as prematurity very low birth weight-associated congenital anomalies, immature organ systems, airway difficulty due to inadequate positioning, sharing of circulation and equipment, and workforce.

A pair of female craniopagus conjoined twins aged 6 months admitted to pediatric surgery department for the purpose of separation surgery. This pair is a looking healthy. Their mother gave birth by cesarean section under spinal anesthesia, no perioperative complications. Before going for separation surgery, neurosurgeons planned for magnetic resonance imaging (MRI) head of the twins. Before taking the twins for MRI, evaluation done by taking thorough history, NPO status, and routine blood and urine analysis. Figure 1 shows X-ray of craniopagus twins.

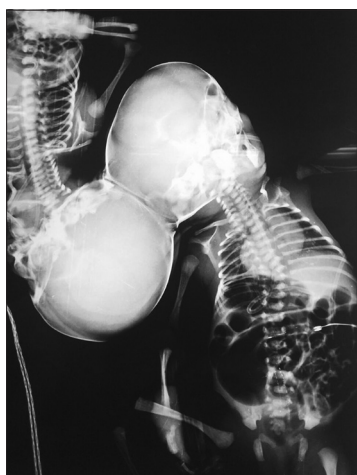

Figure 1: X-ray of craniopagus twins

Preprocedure preparation includes parent counseling and:

- Two fully dedicated anesthetic teams for each child
- MRI compatible anesthesia work station, airway equipment, monitors, and drug carts
- Close-loop communication to avoid confusion and drug error
- MRI room preparation (adequate light and extensive linings)
- Childs are labeled as Twin A and Twin B to avoid confusion between them while dosing.

Syrup triclofos 3 ml given orally to both twins. After attaching monitors baseline SpO₂, electrocardiogram, and noninvasive blood pressure, 24-gauge intravenous (IV) cannulas were placed to both twins. Before sedation, the presence of cross-circulation was tested with the administration of injection atropine administered to one twin, and no change in heart rate was observed in other twin. It appeared that there was no cross-circulation between the twins. Injection propofol 10 mg IV given bolus followed by 5 mg intermittently to both twins whenever they move till MRI procedure over. Oxygen supplementation was given with oxygen face mask to both twins. D₅ in 0.45% saline was used for fluid supplementation. Whole procedure was lasting for 2 h. The intra-procedure course and recovery were uneventful. Conjoined twins were shifted to postprocedure room for further monitoring. Both the twins were maintained stable hemodynamics and good oxygenation. They were shifted to a ward after 3 h of close monitoring. MRI is shown in Figure 2.

Conjoined twinning mainly craniopagus is the rare and devastating malformations. Treating conjoined twins is a challenge to both the surgeon as well as anesthesiologist. Most cases of separation are extremely risky and life threatening. In many cases, the surgery results in the death

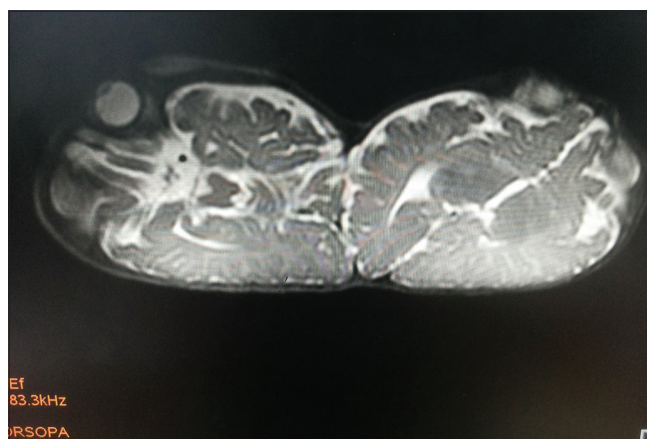


Figure 2: Magnetic resonance imaging of craniopagus twins

of one or both of the twins, particularly if they are joined at the head, craniopagus.^[3]

Sedation is mandatory in children undergoing MRI to ensure motionless. The success of sedation is measured by two factors: Safety (lack of adverse events) and effectiveness of the procedure (successful completion of the diagnostic examination). Propofol is frequently used to induce deep sedation in children, but increased doses of propofol may lead to over sedation and respiratory depression. Goals of the anesthesia care are to pay meticulous attention to detail, monitoring, and vigilance, planning for the postoperative care in the Intensive Care Unit, by a dedicated team of anesthesiologists and intensivists for each child with duplication of all monitoring and equipment in one operating room.^[4]

Pharmacokinetics and pharmacodynamics are inconsistent in various types of twins. Usually, there is more cross-circulation in the thoracopagus and craniopagus twins^[5] than in other types and therefore one can expect altered and unpredictable drug responses.^[6] Estimation of circulatory mixing is useful to help calculate drug dosage and fluid replacement during surgery.^[7] Drugs administered to one twin may have unexpected effects on the other, especially for IV administration when circulatory admixing is present.^[8] Recommended IV doses of anesthetic agents for the combined body weight of the twins are usually halved and then divided into two equal doses to be administered to each twin. Reduced incremental doses are titrated against response and help minimize the dangers of compounding drug effects in one twin.^[9]

Propofol seems to be more effective, achieve the appropriate sedation level more quickly, and provide a faster onset of sedation than midazolam in pediatric procedural sedation and analgesia. Propofol is preferred for imaging studies (computed tomography and MRI) to reduce the occurrence of undesired motion artifacts. Although both drugs are safe to use for sedation before pediatric imaging procedures, propofol is preferred with appropriate preparation.^[10]

Anesthesia for conjoined twins for procedural evaluation is a challenge to the anesthesiologist because we, the anesthesiologists, need to care for two twins at the same time instead of just one. Multidisciplinary communication, cooperation, and titrated doses of sedation remain the cornerstones for the success of procedural sedation to conjoined twins.

Financial support and sponsorship

Nil.

Conflicts of interest

There are no conflicts of interest.

**RAGHAVENDRA VAGYANAVAR,
AMRITA BHATTACHARYYA, GAURAV MISRA,
MOHAMMAD HASHIM¹, ASMITA²**

Departments of Anaesthesiology and Critical Care and
¹Radiology, ²Senior Resident, Sanjay Gandhi Postgraduate
Institute of Medical Science, Lucknow, Uttar Pradesh, India

Address for correspondence:

Dr. Raghavendra Vagyannavar,
Room No 336, New P.G Hostel, Sgpgims Campus, Rae Bareli Road,
Lucknow - 226 014, Uttar Pradesh, India.
E-mail: raghumln2005@gmail.com

References

- Hanson JW. Letter: Incidence of conjoined twinning. *Lancet* 1975;2:1257.
- Chalam KS. Anaesthetic management of conjoined twins' separation surgery. *Indian J Anaesth* 2009;53:294-301.
- Stone JL, Goodrich JT. The craniopagus malformation: Classification and implications for surgical separation. *Brain* 2006;129(Pt 5):1084-95.
- Leelanukrom R, Somboonviboon W, Bunburaphong P, Kiatkungwanklai P. Anaesthetic experiences in three sets of conjoined twins in King Chulalongkorn Memorial Hospital. *Paediatr Anaesth* 2004;14:176-83.
- Shank E, Manohar N, Schmidt U. Anesthetic management for thoracopagus twins with complex cyanotic heart disease in the magnetic resonance imaging suite. *Anesth Analg* 2005;100:361-4.
- Thomas JM. Anaesthesia for conjoined twins. *Childs Nerv Syst* 2004;20:538-46.
- Greenberg M, Frankville DD, Hilfiker M. Separation of omphalopagus conjoined twins using combined caudal epidural-general anesthesia. *Can J Anaesth* 2001;48:478-82.
- Oak SN, Joshi RM, Sandesh P, Uday B, Satish kumar KV. Successful separation of xipho-omphalopagus twins. *J Indian Assoc Pediatr Surg* 2007;12:218-20.
- Thomas JM, Lopez JT. Conjoined twins – The anaesthetic management of 15 sets from 1991-2002. *Paediatr Anaesth* 2004;14:117-29.
- Sebe A, Yilmaz HL, Koseoglu Z, Ay MO, Gulen M. Comparison of midazolam and propofol for sedation in pediatric diagnostic imaging studies. *Postgrad Med* 2014;126:225-30.

This is an open access article distributed under the terms of the Creative Commons Attribution-NonCommercial-ShareAlike 3.0 License, which allows others to remix, tweak, and build upon the work non-commercially, as long as the author is credited and the new creations are licensed under the identical terms.

Access this article online	
Website: www.saudija.org	Quick Response Code 
DOI: 10.4103/sja.SJA_89_17	

How to cite this article: Vagyannavar R, Bhattacharyya A, Misra G, Hashim M, Asmita. Craniopagus twins for magnetic resonance imaging. *Saudi J Anaesth* 2017;11:509-10.

© 2017 Saudi Journal of Anesthesia | Published by Wolters Kluwer - Medknow