



Assessment of beta-catenin expression by immunohistochemistry in colorectal neoplasms and its role as an additional prognostic marker in colorectal adenocarcinoma

Indroneel Bhattacharya, Neepamanjari Barman, Moumita Maiti, Ranu Sarkar

Pathology Department, Nilratan Sircar Medical College and Hospital, India

Abstract

Background. Cancer is one of the world's biggest health care challenges, with colorectal cancer (CRC) being one of the three most frequently encountered malignancy worldwide. The main cause of mortality associated with CRC is tumour invasion and metastasis. Pathogenesis of CRC is a multistep process, during which different molecular pathways come into play. The cardinal genomic alteration that has been found universally present in CRC is a mutation in the adenomatous polyposis coli gene (APC). APC mutation causes unrestricted action of the Wnt signaling pathway which subsequently enhances the intracellular accumulation of a protein called beta-catenin, responsible for cell proliferation, differentiation and enhanced survival of colorectal epithelial cells.

Aim. This study was conducted to analyze beta-catenin expression in various colorectal neoplasms, and its change with respect to different grades and stage of colorectal adenocarcinoma.

Study design. This was a cross-sectional observational study.

Methods. A total of 66 cases were enrolled in this study. Census method of sampling was used. Data was collected using a pre-designed, pretested semi-structured schedule on dependent variables like beta-catenin expression and independent variables like clinico-pathological profile including dietary history, macroscopic findings, histological type, histological grade, stage and other relevant parameters. An institution based cross sectional observational study was performed between February 2016 and July 2017. Representative sections taken from the specimens included in the study were subjected to histopathological examination followed by immunohistochemistry [IHC] for beta-catenin expression; the data obtained were analyzed by mean \pm SD, Student t test, Chi-square/ Fisher Exact test using statistical software SPSS 18.0.

Results. A statistically significant correlation ($P = 0.004$), of beta-catenin localization and IHC score was noted between the benign, premalignant and malignant neoplasms following a gradual transition from a membranous to a nuclear positivity; also, a significant ($P < 0.001$) correlation between beta-catenin nuclear score and the corresponding American Joint Committee on Cancer (AJCC) stage of colorectal adenocarcinoma was also found in this study.

Conclusion. The purpose of this study was to determine the change in beta-catenin expression which demonstrates a gradual shift from a membranous to subsequent cytoplasmic and nuclear positivity from normal colorectal tissue to benign, premalignant and malignant neoplasms respectively. This property of beta-catenin can determine the malignant potential of various premalignant neoplasms of the large intestine, thus aiding in an early initiation of prophylactic treatment, which can prevent the development of an invasive disease. The membranous, cytoplasmic and nuclear scores show a linear progression with the advancing stages of colorectal carcinoma, making beta-catenin a prognostic marker in malignant colorectal neoplasms.

Keywords: beta-catenin, colorectal neoplasm, neoplasm staging, prognostic markers

DOI: 10.15386/mpr-1218

Manuscript received: 23.10.2018

Received in revised form: 07.04.2019

Accepted: 14.04.2019

Address for correspondence:
drneepab2018@gmail.com

Introduction

Among the various malignancies of the gastrointestinal tract, adenocarcinoma of the colon ranks first both in incidence and as a major cause of mortality and morbidity worldwide. Globally colorectal adenocarcinoma accounts for approximately 1.2 million new cases, and 600,000 deaths each year [1]. In India, the incidence of colorectal cancer is 4.3 and 3.4 per 100,000 male and female respectively [2].

Colorectal carcinoma (CRC) is also one of the most preventable cancers because in many cases it arises from benign neoplasms, called tubular adenomas and serrated polyps, which evolve into colorectal carcinomas over many years. The slow polyp-cancer progression sequence seen in the general population offers an opportunity to detect and remove the polyps before they undergo malignant transformation [3].

Genomic and epigenomic instability distinguishes neoplastic from normal colonic epithelium and is a hallmark feature of colorectal carcinogenesis [4]. Several kinds of genomic or epigenetic instability have been described in colorectal cancers: (a) chromosomal instability [CIN], (b) microsatellite instability [MSI], (c) non-MSI hypermutability, (d) aberrant DNA methylation, and (e) global DNA hypomethylation [5].

APC/beta-catenin pathway plays an integral role in the classic adenoma-carcinoma sequence. The inactivation of the adenomatous polyposis coli (APC) tumor suppressor gene initiates colorectal tumorigenesis. Under physiological conditions the APC protein is responsible for the destruction of transcription activators like beta-catenin and T cell transcription factor 4 (Tcf-4). In cases of mutation in APC gene and its subsequent dysfunction, overactivity of these transcription factors is noted, which results in cellular proliferation and elevated survival. This indicates that the APC protein has a tumor suppressive effect [6].

In case of APC mutation, the destruction complex fails to biquitinise beta-catenin, which leads to its accumulation intracellularly, potentiating its nuclear translocation, where it acts as a transcriptional activator to target genes like *c-myc* and *cyclin D1*, which subsequently play an integral role in the development of colorectal neoplasms [7].

Studies have been undertaken to investigate and compare the expression pattern of beta-catenin in normal colorectal tissue and in various colorectal neoplasms; benign, premalignant and malignant. Normal colorectal tissue does not display nuclear or cytoplasmic immunoreactivity with beta-catenin, and an exclusively a diffuse membranous positivity [7].

Gradual decrease in membranous staining and subsequent increase in cytoplasmic and nuclear immunostaining by beta-catenin has been associated with increasing levels of dysplasia in neoplastic lesions of the large intestine [8].

Furthermore, studies have been undertaken to determine the correlation between beta-catenin expression in colorectal cancer and lymph node metastasis, which is one of the most important prognostic markers for colon cancer [7], as well as the possibility of the future of anti-beta-catenin targeted chemotherapy for the treatment of colorectal cancers [9,10].

Thus, the present study was designed with the aim to assess the variability in the expression of beta-catenin among histologically different neoplasms of the large intestine, including benign polyps, premalignant dysplastic adenomas and carcinoma. The objective of this study is to present beta-catenin as a possible marker which can detect the malignant potential of premalignant neoplasms of the large intestine, thus enabling early management of these neoplasms, which could prevent the subsequent development of a malignant disease. The study also aims to establish the relationship between beta-catenin expression with the histological grade as well as the stage of colorectal carcinoma, examining the possibility of its use as an additional immunohistochemical prognostic marker in colorectal adenocarcinomas, as well as giving way to the possibility of anti-beta-catenin targeted chemotherapy to effectively treat colon cancers in the future.

Materials and method

Specimens and general information

An institutional based cross-sectional observational study was conducted in a tertiary care center from February 2016 to July 2017. The work was initiated after obtaining ethical clearance from the Institutional Ethical Committee and informed consent from the study population. Specimens obtained by colorectal endoscopic biopsies and surgical procedures including segmental colectomies, hemicolectomies, anterior resection and abdomino-perineal resection for colorectal growth were included in the study. All specimens with histopathological features suggestive of a nonepithelial lesion and an inflammatory/infective colorectal disease, inadequate sample and non-consensual patients were excluded from the study. Following these criteria a total of 66 specimens were enrolled in the study. Data was collected by interview, observations, record review and laboratory techniques including histopathology and immunohistochemistry. Reporting was done by trained histopathologists.

Histopathology

All tissue samples were collected in 10% buffered formalin and processed for routine histopathological examination. Grossing and reporting of colectomy specimens suspicious of colorectal carcinoma were conducted according to CAP (College of American Pathologists) protocol [11]. Five micrometers thick sections from formalin fixed paraffin embedded blocks were cut and stained with hematoxylin and eosin for histopathological diagnosis. After histological confirmation of the diagnosis

(colorectal neoplasms including colorectal carcinoma), the following parameters were analyzed: histological type, degree of differentiation, tumor grade, lymphovascular and perineurial invasion, nodal involvement, status of margins, and staging (American Joint Committee on Cancer, TNM, 2010). An apparently uninvolved mucosa (at least 5 cm away from the tumour) in all the cases was considered as normal mucosa. Histological examination was done in all the cases of normal mucosa for confirmation.

Immunohistochemistry (IHC) for beta-catenin

For IHC staining, 3 µm thick sections from formalin fixed paraffin embedded tissues were taken on poly-L-Lysine coated slides. The primary antibody used for beta-catenin IHC was *Goat monoclonal, Anti-human, sc-1496, by Santa Cruz Biotechnology*, and the steps mentioned in the kit supplied were followed. During IHC staining, antigen retrieval was performed using the “pressure cooker” method. Di-amino benzidine (DAB) was used as chromogen. Positive controls which were used are as follows (a) normal colorectal tissue was taken as an internal control for beta-catenin immunohistochemistry and (b) histologically diagnosed section of fibromatosis (Desmoid tumour) for nuclear positivity by beta-catenin immunohistochemistry. Negative control was achieved by

omitting primary antibody.

Evaluation of IHC staining

Expression of beta-catenin in cells was compared between normal mucosa and neoplastic tissue. The criterion for a positive immune reaction was brown membranous staining in histologically normal colorectal tissue (internal control) and dark brown to black nuclear staining in the fibroblasts of Desmoid tumour (external control). Positive findings were evaluated in four fields (1000 cells) under a light microscope at 400X magnification, without knowledge of the clinical outcome.

Scoring of immunohistochemistry

The scoring of positive beta-catenin expression was performed according to Mauri et al [12]. In brief, the staining intensity was scored as follows (Figure 1):

- 0 = no expression
- 1+ = weak expression
- 2+ = moderate expression
- 3+ = strong expression
- 4+ = very strong expression

The final score was expressed as immunohistochemical staining score (IHC score) obtained by multiplying the percentage of positive cells (or nuclei) with the staining intensity.

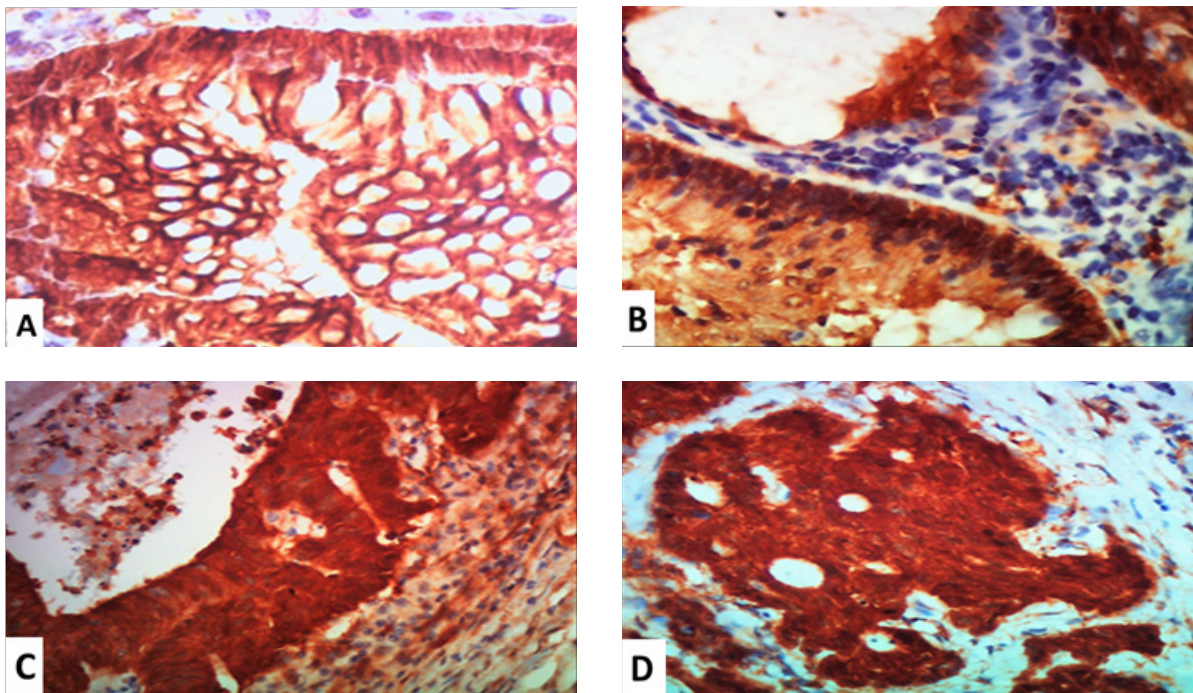


Figure 1. Scoring for beta-catenin nuclear expression; A: Beta-catenin immunohistochemistry, 400X, 1+ = weak beta-catenin nuclear expression, B: Beta-catenin immunohistochemistry, 400X, 2+ = moderate beta-catenin nuclear expression, C: Beta-catenin immunohistochemistry, 400X, 3+ = strong beta-catenin nuclear expression, D: Beta-catenin immunohistochemistry, 400X, 4+ = very strong beta-catenin nuclear expression.

Statistical analysis

Data was entered in MS Excel of Windows 7. For descriptive purposes mean \pm SD, range and percentage were used. Student t test (two tailed, independent) and Fisher Exact test was used to find the significance of study parameters on categorical scale between two or more groups, using SPSS-18. Significance level was considered at p value < 0.05 .

Results

Distribution of colorectal neoplasms according to their histopathological diagnosis, as well as other important pathological parameters

A total of 66 colorectal neoplasm cases were included in the study. On histopathological examination it was concluded that there were 22 benign and premalignant neoplasms and 44 colorectal adenocarcinomas.

Among the 22 nonmalignant neoplasms there were 5 hyperplastic polyps, 5 Peutz Jegher polyps, and 12 adenomatous polyps which included 6 adenomatous polyps with low grade dysplasia and 6 with high grade dysplasia.

In the category of 44 malignant neoplasms, 35 were adenocarcinoma not otherwise specified (NOS) as indicated by their histopathological examination, and the remaining 9

were mucinous adenocarcinomas. Of these, one third were either stage I and stage II disease while the rest in stage III or stage IV. Among the 44 malignant neoplasms, 25 showed microscopic evidence of lymphovascular invasion, and 18 presented with microscopic evidence of perineurial invasion.

Distribution of epidemiological and clinicopathological parameters

The average age of the participants was estimated to be 61.62 ± 11.11 (mean \pm SD) years with a range of 45 (32-77) years. About 29% of the participants were female. The majority (57.14%) had no addiction for tobacco. About 30.16% were obese and 17.63% reportedly had inclination towards alcohol consumption. Only, 14.29% had at least one family member affected by cancer. The symptom/clinical features of the patients enrolled in the study included the following: 77.77% presented with bleeding per rectum, 15.87% with occult blood in stool and the rest with pain abdomen. Majority (28.57%) of participants had their pathology either in caecum closely followed by rectum (25.40%). Almost one third (34.84%) of the lesions were benign. Nearly two thirds (66%) of the cases had a polypoid exophytic appearance. The size of the malignant neoplasms ranged from 2 to 10 cm with a mean of 3.50 cm. Macroscopic tumour perforation was seen only in 6% of the specimens.

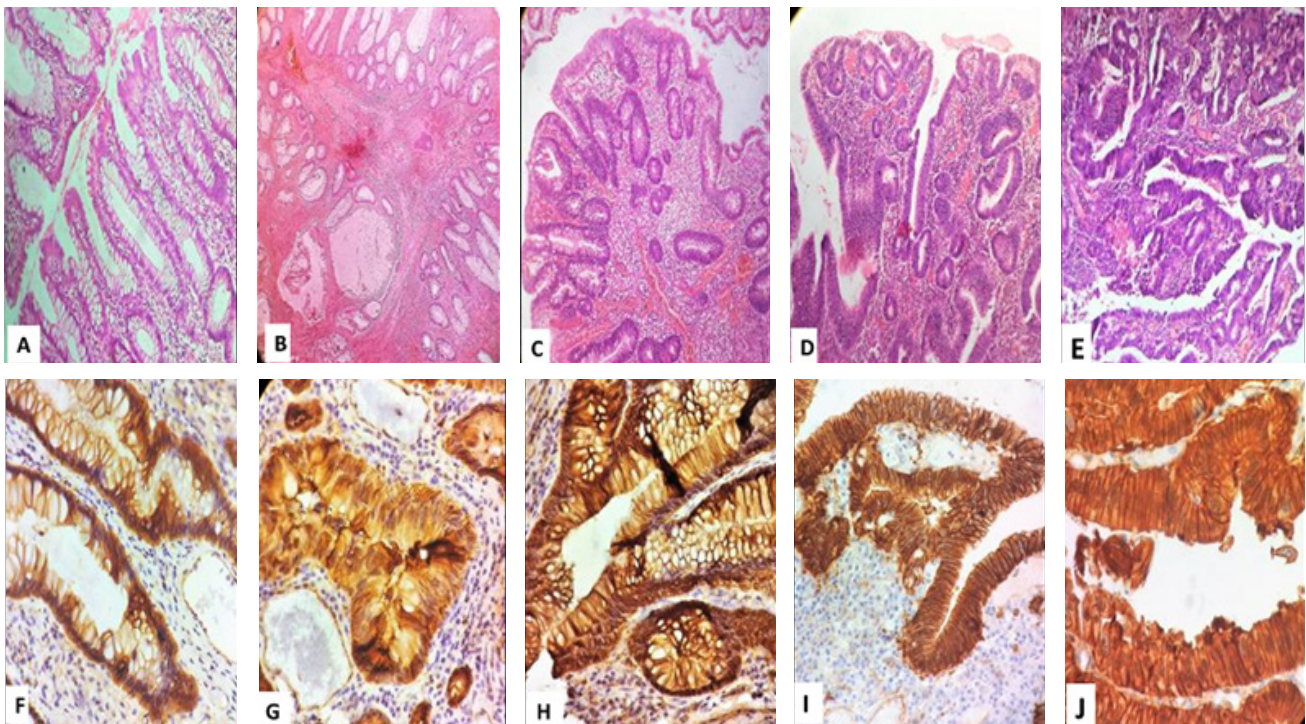


Figure 2. Histopathological and Immunohistochemical examination of various colorectal neoplasms; **First row:** Hematoxylin & eosin, 100X; A: Hyperplastic polyp, B: Peutz Jegher polyp, C: Adenoma with low grade dysplasia, D: Adenoma with high grade dysplasia, E: Adenocarcinoma. **Second row:** Beta catenin immunohistochemistry, 400X; F: Hyperplastic polyp, G: Peutz Jegher polyp, H: Adenoma with low grade dysplasia, I: Adenoma with high grade dysplasia, J: Adenocarcinoma.

Beta-catenin expression in colorectal neoplasms

Immunohistochemical examination was performed to determine beta-catenin subcellular localization and score in various colorectal neoplasms included in the study (Figure 2). On descriptive analysis of IHC results the following were noted: (1) highest beta-catenin membranous expression in benign polyps, namely Peutz Jegher polyps and hyperplastic polyps, (2) highest cytoplasmic beta-catenin scores noted in dysplastic adenomatous polyps, (3) highest beta-catenin nuclear score noted in colorectal adenocarcinomas (Table I).

A statistically significant correlation was obtained between beta-catenin expression (subcellular localization

and score) and the histopathological categorization of the colorectal neoplasms, as benign, premalignant and malignant entities, ($P < 0.001$, Student t test), with the presence of a higher nuclear beta-catenin score in the malignant neoplasms (Table II).

A gradual increase in beta-catenin score and its translocation from a membranous to cytoplasmic and finally a nuclear positivity was noted in higher stages (American Joint Committee on Cancer, TNM, 2010) of colorectal adenocarcinomas (Figure 3). This correlation was found to be statistically significant on Pearson correlation study ($r = 0.512$; $p < 0.001$) using Fisher Exact test (Table III).

Table I. Descriptive assessment of beta-catenin subcellular localization and scores (\bar{x}) across colorectal neoplasms (n=66).

Colorectal neoplasms		Beta-catenin Expression			Number (%)
		Membranous score (\bar{x})	Cytoplasmic score (\bar{x})	Nuclear score (\bar{x})	
Benign neoplasms	Polyp [hyperplastic polyp and Peutz Jegher polyp]	132.0	59.70	15.40	10(15.1)
	Adenoma with low grade dysplasia	172	201.5	62.5	6(7.57)
Premalignant neoplasms	Adenoma with high grade dysplasia	190.66	178	71.33	6(7.57)
	Adenocarcinoma NOS	28.17	118.79	212.52	35(79.54)
Malignant neoplasms	Mucinous adenocarcinoma	19.0	111.5	223	9(13.63)

Table II. Comparison of membranous, cytoplasmic and nuclear beta-catenin scores across colorectal neoplasms (n=66):

Beta-catenin score	Colorectal neoplasms		P value
	Benign/Premalignant (\bar{x})	Malignant (\bar{x})	
Membranous Score	154.70	28.40	<0.001**
Cytoplasmic Score	107.22	119.05	0.175
Nuclear score	29.91	212.05	<0.001**

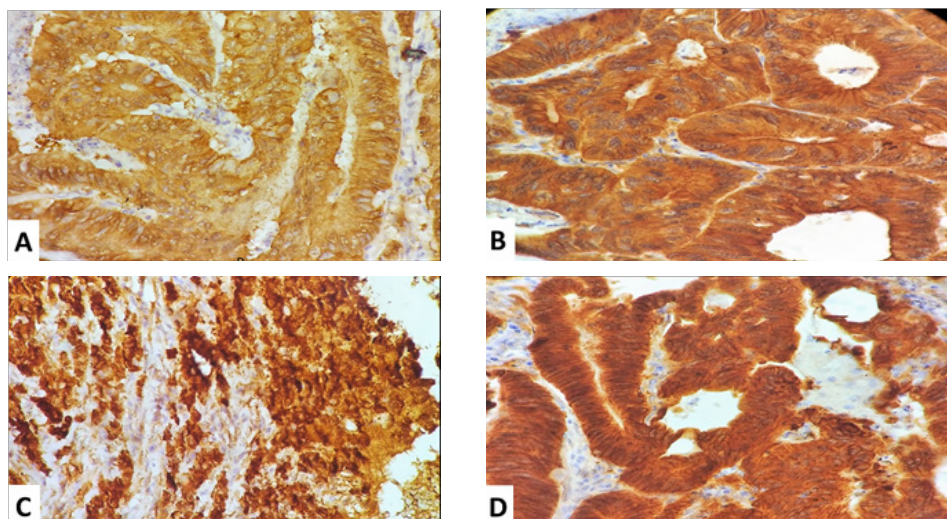


Figure 3. Beta-catenin expression in different AJCC-TNM stages of colorectal adenocarcinoma; A: Beta catenin immunohistochemistry, 400X; Stage I, well differentiated adenocarcinoma, not otherwise specified (NOS), B: Beta catenin immunohistochemistry, 400X; Stage II, moderately differentiated adenocarcinoma NOS, C: Beta catenin immunohistochemistry, 400X; Stage III poorly differentiated adenocarcinoma, D: Beta catenin immunohistochemistry, 400X; Stage IV, moderately differentiated adenocarcinoma NOS.

Table III. Beta-catenin subcellular localization and corresponding membranous, cytoplasmic and nuclear scores (\bar{x}) in different AJCC stage of CRC (n=44).

AJCC Stage of Malignant neoplasms	Membranous Beta-catenin score (\bar{x})	Cytoplasmic Beta-catenin score (\bar{x})	Nuclear Beta-catenin score (\bar{x})
I	82.33	166.33	149.0
II	IIA	59.5	142.50
	IIB	42.0	124.60
	IIC	27.17	113.83
III	IIIA	23.14	107.43
	IIIB	15.25	108.0
	IIIC	9.17	108.0
IV	IVA	6.00	120.0
p value	<0.001**	<0.001**	<0.001**

r = 0.512, Pearson correlation using Fisher Exact test

A higher nuclear beta-catenin score was detected in poorly differentiated adenocarcinomas, in comparison to well differentiated and moderately differentiated adenocarcinomas, however a statistically significant relationship between different histopathological grades and beta-catenin expression/scores could not be established (P value > 0.01, Chi-square test).

On comparing the average nuclear score of beta-catenin between adenocarcinoma NOS and mucinous adenocarcinoma, a higher nuclear score was detected in the latter further accentuating the poor prognosis of mucinous adenocarcinomas (Table IV).

Table IV. Nuclear Beta-catenin scores of colorectal mucinous adenocarcinomas (\bar{x}) and adenocarcinoma NOS (\bar{x}) (n=43).

Adenocarcinoma type	Average beta-catenin nuclear scores (\bar{x})
Adenocarcinoma NOS	212.52
Mucinous adenocarcinoma	223.5

Discussion

Beta-catenin has been identified as an integral membrane protein which in association with E-cadherin facilitates cell to cell interactions [13]. Beta-catenin function is under the control of the intracellular Wnt signaling pathway. Mutations in APC genes, beta-catenin genes and genes of various important components of the Wnt signaling pathway, causes overaccumulation of the beta-catenin protein intracellularly followed by its nuclear translocation. Intranuclear presence of beta-catenin stimulates the activity of various other transcription factors leading to cell proliferation and tumorigenesis [6,7].

The most common genetic abnormality found in colorectal tumorigenesis is the mutation in APC gene,

which is an important component of the Wnt signaling pathway. Dysfunction in Wnt pathway causes abnormal localization and nuclear accumulation of beta-catenin [14]. Since colorectal tumorigenesis occurring as a result of mutation in the APC gene (85% cases) follows a gradual multistep sequence, beta-catenin expression by immunohistochemistry (nuclear positivity) can be used to determine the malignant potential of colorectal polyps and adenomas [7,15]. Enhancing the possibility of prophylactic interventions and sustained follow up which in turn can prevent the subsequent development of a malignancy.

Keeping in mind the role played by beta-catenin in the pathogenesis of colorectal neoplasms, the purpose of this study was to detect beta-catenin expression immunohistochemically in various colorectal neoplasms ranging from benign hyperplastic polyps, premalignant adenomatous polyps to colorectal adenocarcinoma, as well as to determine the correlation between beta-catenin expression by immunohistochemistry with the AJCC-TNM staging, which is the most vital prognostic marker in colorectal carcinoma.

The colorectal neoplasms included in this study depict a predominance for proximal segment of the large intestine; caecal growth, similar to the findings of the study conducted by Wong et al [7]. However, studies conducted by Mi et al. [18], Schlemper et al. [19] found the distal colon, namely rectum, to be the most common site of colorectal neoplasms including CRC. In the present study distal colon, rectum, was the second most common site for colorectal neoplasms.

Adenocarcinoma, not otherwise specified (NOS) was the most common (80%) histological type among the CRC cases in the present study. Among the adenocarcinoma NOS category, moderate differentiation of tumors was most frequently noted (85%) followed by well differentiated tumors (10%). This corroborated with the findings of Wong et al. [7], and Back et al [15].

The present study inferred that the most common (31.8%) AJCC stage of CRC was Stage IIIB followed by stage IIA (13.7%), corresponding to the TNM of pT3N2M0 and pT3N0M0 respectively. This was in accordance with the observations of Wong et al. [7], and Bienz et al [17].

The normal colorectal mucosa which was used as an internal control was found to possess an exclusive membranous expression of beta-catenin, with a score of 102±1.5 (mean ± Standard Deviation, SD), without any cytoplasmic or nuclear positivity in all the sections examined, which is in concordance to the findings of Wong et al. [7], Brabletz et al. [20] and Mi et al [18]. In this study a descriptive assessment of beta-catenin expression [subcellular localization and score] among the various colorectal neoplasms was undertaken. The result showed the gradual intracellular translocation of beta-catenin from a membranous to a nuclear expression in a stepwise manner, following the polyp---adenoma---carcinoma sequence,

which is in concordance with the findings of Wong et al. [7].

In this study a statistically significant changes in the subcellular localization and increase in beta-catenin score was noted between benign and malignant neoplasms, ($P < 0.001$, Student t test) with the subsequent presence of a higher nuclear beta-catenin score in the malignant neoplasms, identical to the findings of the studies conducted by Wong et al. [7], and Kobayashi et al [21].

In our study a statistically significant positive correlation was obtained between beta-catenin subcellular localization along with their corresponding membranous, cytoplasmic, and nuclear scores with the AJCC-TNM stage ($r = 0.512$; $p < 0.001$) of colorectal adenocarcinoma, concordant with the findings of Wong et al. [7], Kobayashi et al [21].

Conclusion

From the descriptive and analytical methods applied in this study, it can be concluded that the subcellular beta-catenin scores by immunohistochemistry exhibits a sequential change between the benign, premalignant and malignant colorectal neoplasms, which begins from a benign polyp, followed by a dysplastic adenoma and ultimately giving rise to carcinomas.

The study also highlights the possible use of immunomarkers like beta-catenin to detect the malignant potential of premalignant dysplastic colorectal lesions, which can possibly guide in its early management and prevent the development of a subsequent malignancy. Furthermore, the positive and statistically significant correlation of beta-catenin nuclear scores by immunohistochemistry with the AJCC-TNM stage, the most important prognostic marker of colon cancer, supports the use of beta-catenin immunohistochemistry as an additional prognostic marker in colorectal adenocarcinoma.

References

1. Ferlay J, Soerjomataram I, Dikshit R, Eser S, Mathers C, Rebelo M, et al. Cancer incidence and mortality worldwide: sources, methods and major patterns in GLOBOCAN 2012. *Int J Cancer*. 2015;136:E359-E386.
2. Yeole BB. Trends in cancer incidence in esophagus, stomach, colon, rectum and liver in males in India. *Asian Pac J Cancer Prev*. 2008;9:97-100.
3. Polakis P. The many ways of Wnt in cancer. *Curr Opin Genet Dev*. 2007;17:45-51.
4. Grady WM, Carethers JM. Genomic and epigenetic instability in colorectal cancer pathogenesis. *Gastroenterology*. 2008;135:1079-1099.
5. Little MP, Vineis P, Li G. A stochastic carcinogenesis model incorporating multiple types of genomic instability fitted to colon cancer data. *J Theor Biol*. 2008;254:229-238.
6. Morin PJ, Sparks AB, Korinek V, Barker N, Clevers H, Vogelstein B, et al. Activation of β -catenin-Tcf signaling in colon cancer by mutations in β -catenin or APC. *Science*. 1997;275:1787-1790.
7. Wong SC, Lo ES, Lee KC, Chan JK, Hsiao WL. Prognostic and diagnostic significance of β -catenin nuclear immunostaining in colorectal cancer. *Clin Cancer Res*. 2004;10:1401-1408.
8. Iwamoto M, Ahnen DJ, Franklin WA, Maltzman TH. Expression of β -catenin and full-length APC protein in normal and neoplastic colonic tissues. *Carcinogenesis*. 2000;21:1935-1940.
9. Jamieson C, Sharma M, Henderson BR. Targeting the β -catenin nuclear transport pathway in cancer. *Semin Cancer Biol*. 2014;27:20-29.
10. Jamieson C, Sharma M, Henderson BR. Wnt signaling from membrane to nucleus: β -catenin caught in a loop. *Int J Biochem Cell Biol*. 2012;44:847-850.
11. College of American Pathologists. Protocol for the Examination of Specimens From Patients With Primary Carcinoma of the Colon and Rectum, June 2017. Available from: <https://documents.cap.org/protocols/cp-gilower-colonrectum-17protocol-4010.pdf>
12. Mauri FA, Caffo O, Veronese S, Verderio P, Boracchi P, Bonzanini M, et al. Tissue carcinoembryonic antigen and oestrogen receptor status in breast carcinoma: an immunohistochemical study of clinical outcome in a series of 252 patients with long-term follow-up. *Br J Cancer*. 1998;77:1661-1668.
13. Ben-Ze'ev A. The dual role of cytoskeletal anchor proteins in cell adhesion and signal transduction. *Ann N Y Acad Sci*. 1999;886:37-47.
14. Willert K, Nusse R. β -catenin: a key mediator of Wnt signaling. *Curr Opin Genet Dev*. 1998;8:95-102.
15. Back W, Loff S, Jenne D, Bleyl U. Immunolocalization of beta catenin in intestinal polyps of Peutz-Jeghers and juvenile polyposis syndromes. *J Clin Pathol*. 1999;52:345-349.
16. Cheah PY. Recent advances in colorectal cancer genetics and diagnostics. *Crit Rev Oncol Hematol*. 2009;69:45-55.
17. Bienz M, Clevers H. Linking colorectal cancer to Wnt signaling. *Cell*. 2000;103:311-320.
18. Mi B, Wang X, Bai Y, Gong W, Wang X, Geng Y, et al. β -catenin expression is altered in dysplastic and nondysplastic aberrant crypt foci of human colon. *Appl Immunohistochem Mol Morphol*. 2009;17:294-300.
19. Schlemper RJ, Riddell RH, Kato Y, Borchard F, Cooper HS, Dawsey SM, et al. The Vienna classification of gastrointestinal epithelial neoplasia. *Gut*. 2000;47:251-255.
20. Brabletz T, Jung A, Reu S, Porzner M, Hlubek F, Kunz-Schughart LA, et al. Variable β -catenin expression in colorectal cancers indicates tumor progression driven by the tumor environment. *Proc Natl Acad Sci U S A*. 2001;98:10356-10361.
21. Kobayashi M, Honma T, Matsuda Y, Suzuki Y, Narisawa R, Ajioka Y, et al. Nuclear translocation of beta-catenin in colorectal cancer. *Br J Cancer*. 2000;82:1689-1693.