

CASE REPORT

Open Access



# Intestinal ulcers in a patient with myelodysplastic syndrome: a case report

Xiaofen Zhang<sup>1†</sup>, Meng Jin<sup>1†</sup>, Zhe Shen<sup>1</sup>, Xingyong Wan<sup>1</sup>, Lan Li<sup>1</sup>, Yuwei Zhang<sup>1</sup>, Xinping Zhou<sup>2</sup>, Chen Mei<sup>2</sup>, Hongyan Tong<sup>2</sup> and Chaohui Yu<sup>1\*</sup>

## Abstract

**Background:** Trisomy 8 positivity myelodysplastic syndrome with Behçet's disease is rare. Isolated trisomy 8 is a frequent cytogenetic abnormality in the MDS, but the characteristic of trisomy 8 and the association between trisomy 8 positivity myelodysplastic syndrome and Behçet's disease is unclear.

**Case presentation:** Here, we reported a 63-year-old man, who presented with fever, abdominal pain and hematochezia. Imaging studies revealed bowel wall thickening and mural hyperenhancement of terminal ileum and cecum. Colonoscopy found multiple round ulcers in terminal ileum, ileocecal valve and multiple yellow dotted pseudomembranous attachments throughout the colon. Capsule endoscopy also revealed multiple irregular ulcers in lower ileum. Serum C-reactive protein levels and fecal calprotectin were abnormally high. The clostridium difficile toxin A and B was positive. However, the patient's intestinal ulcers did not resolve after two weeks course of vancomycin. Considered that the patient was diagnosed as MDS-RAEB2 with a karyotype of 47 XX, +8. And detailed inquiry of medical history revealed epifolliculitis and frequently recurrent oral ulcers 2 months before admission. A diagnosis of trisomy 8 positivity MDS with BD was made. Then he received glucocorticoid along with the 5th course of azacitidine. The follow-up endoscopy showed significantly improved intestinal ulcer 2 months after treatment. we report a rare disease and provide the diagnose and treatment ideas.

**Conclusions:** We highlight the challenges and the process of thinking about of the diagnosis. This may provide a new idea for the diagnosis of intestinal ulcers.

**Keywords:** Intestinal ulcers, Endoscopy, Myelodysplastic syndrome, Trisomy 8, Case report

## Background

Myelodysplastic syndrome (MDS) is a group of heterogeneous acquired clonal malignant diseases. Isolated trisomy 8 is one of the most frequent cytogenetic abnormalities in MDS which presents in 10–15% of MDS/ myeloproliferative neoplasm (MPN) cases [1]. It has a much shorter median survival compare to normal

karyotype. But it is regrettable that the characteristics of trisomy 8 positivity MDS are poorly reported.

Behçet's disease (BD) is a type of autoimmune vasculitis which characterized by recurrent involvement of the mouth, eyes, genitals and skin. A number of cases have developed gastrointestinal ulcers which called gastrointestinal (GI) BD. Nowadays, some evidence shown an association between MDS, trisomy 8 and Behçet's-like disease [2].

In our report, we describe a case of trisomy 8 positivity MDS with GI BD and provide the diagnose and treatment ideas. We share the challenges and the process of thinking about of the diagnosis. This may provide a new idea for the diagnosis of intestinal ulcers.

\*Correspondence: zyyyych@zju.edu.cn

<sup>†</sup>Xiaofen Zhang and Meng Jin have contributed equally to this study.

<sup>1</sup> Department of Gastroenterology, The First Affiliated Hospital, Zhejiang University School of Medicine, Hangzhou 310003, Zhejiang Province, China

Full list of author information is available at the end of the article



### Case presentation

A 63-year-old man was admitted to our hospital because of fever, abdominal pain and hematochezia for 2 months. He was treated with broad-spectrum antibiotics (ceftizoxime and imipenem) in local hospital. However, symptoms aggravated along with persistent diarrhea. One week later, he was transmitted to our hospital. Nine months before admission, the patient was diagnosed as MDS-RAEB2 and received 4 courses of azacytidine and micro-transplantation. The number of primitive cells in bone marrow declined from 25 to 5% after 4 courses of treatment. There was no family history of autoimmune diseases or inflammatory bowel disease.

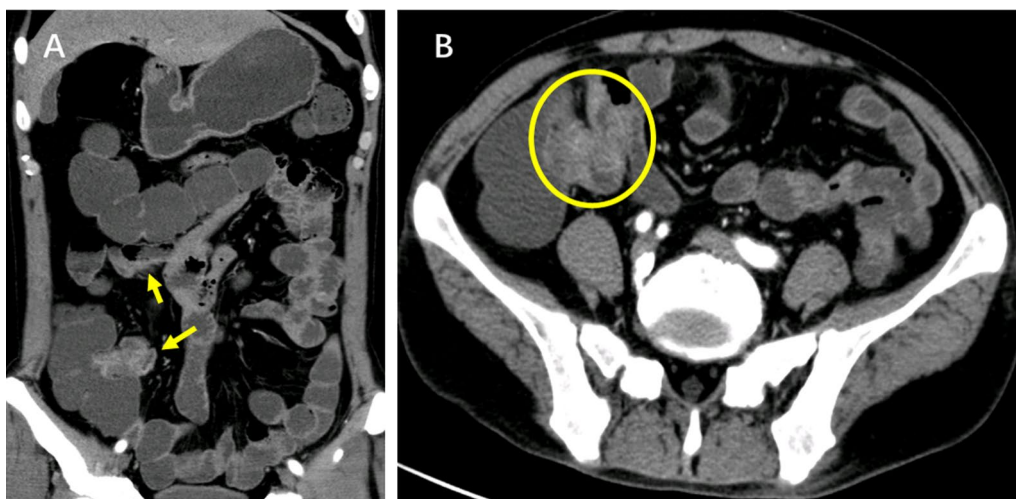
On admission, he was conscious and anemic. There was tenderness on palpation of the right lower quadrant with mild rebound pain. Blood tests showed that white blood cells count was  $13 \times 10^9/L$ , hemoglobin level was 82 g/L, platelet count was  $93 \times 10^9/L$ . Erythrocyte sedimentation rate was 53 mm/h (reference, < 18 mm/h), high sensitivity C-reactive protein was 247 mg/L (reference, < 3.1 mg/L). Fecal calprotectin was 872  $\mu\text{g/g}$ .

The computed tomography enterography (CTE) (Fig. 1) showed bowel wall thickening and mural hyperenhancement of terminal ileum and cecum. Gastroscopy (Fig. 2A, B) revealed multiple erosions in stomach. Colonoscopy (Fig. 2C–F) showed multiple round ulcers in terminal ileum and ileocecal valve and multiple yellow dotted pseudomembranous attachments throughout colon. Capsule endoscopy also revealed multiple irregular ulcers in lower ileum. Histological analysis showed partially thickened with hyaline degeneration in the wall of small blood vessels.

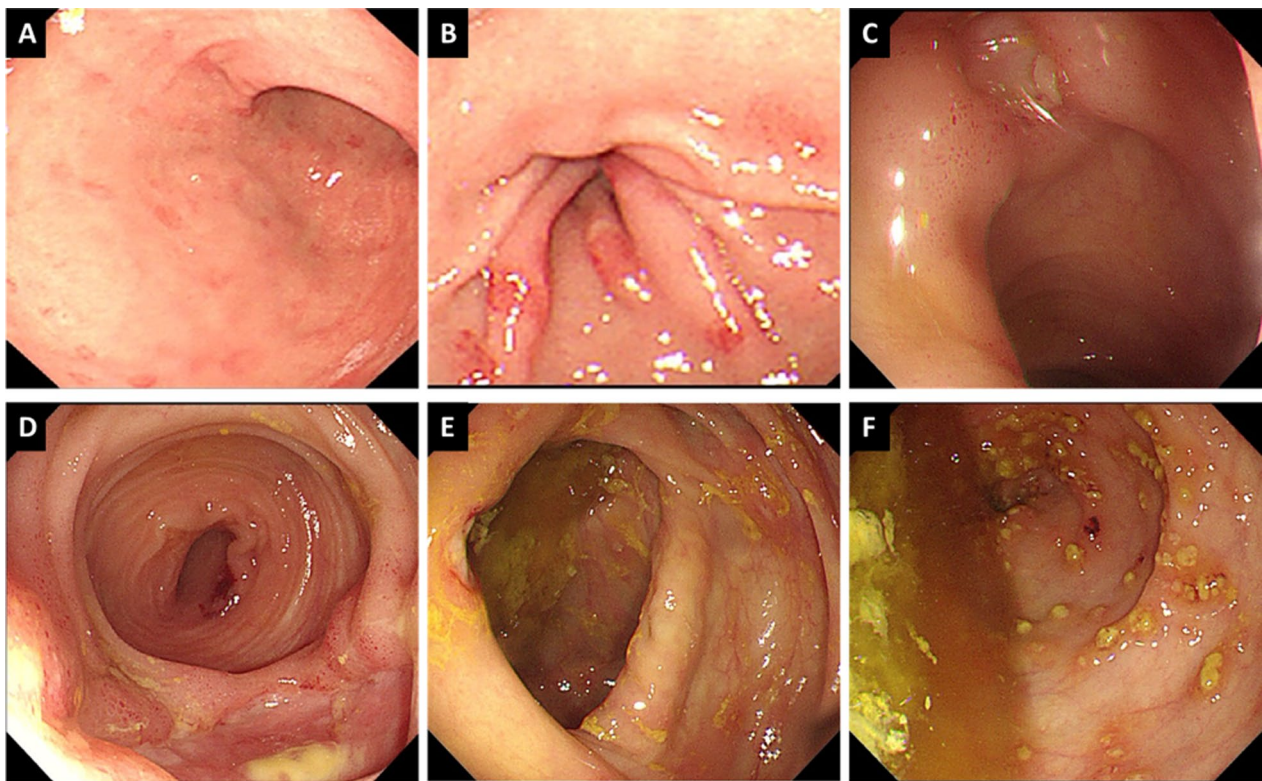
During multidisciplinary team meeting, diagnosis and differential diagnosis was discussed as infectious colitis, cytotoxic drug-related intestinal ulcer, BD, Crohn's disease and intestinal tuberculosis, etc.

Firstly, stool samples, blood samples and previous colonoscopy biopsy specimen were sent to the laboratory to be tested for infection (including bacteria, tuberculosis, virus and fungus). Intriguingly, the clostridium difficile toxin A and B in stools was positive and clostridium difficile infection was confirmed. The patient received vancomycin 125 mg 4 times per day orally [3]. The fever and diarrhea relieved soon after medication. The test of clostridium difficile toxin A and B were negative after two weeks treatment. Colonoscopy showed that the pseudomembrane disappeared but the intestinal ulcers have no tendency to shrink (Fig. 3). Thus, opportunistic infections not enough to explain the whole state of the symptoms.

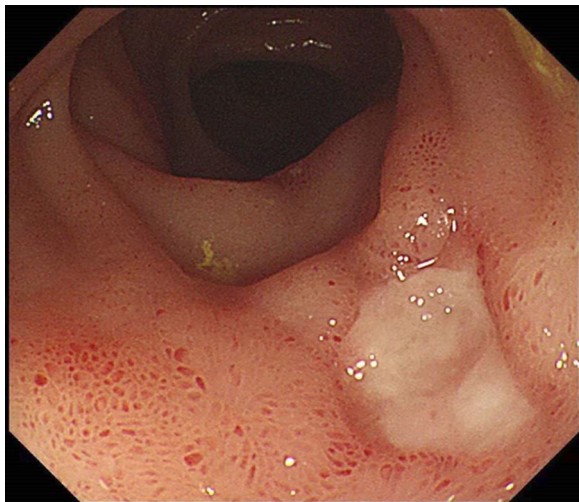
Secondly, azacytidine has been reported to induce hematochezia and intestinal ulcer in literature. Since our patient's symptom occurred between the 3rd and 4th course of azacytidine, we assessed the relationship between azacytidine and intestinal ulcer in our case. According to literature, the intestinal ulcers induced by azacytidine occurred shortly after medication and relieved 7 to 20 days after stopping the medication. [4] However, the intestinal ulcers of our patient existed 54 days after last course. The Naranjo adverse drug reaction probability score of this patient is suspicious (2 scores) which not enough to confirm the diagnosis of drug-related bowel disease.



**Fig. 1** The coronal images (A) and cross-sectional images (B) of computed tomography enterography showed bowel wall thickening and mural hyperenhancement of terminal ileum and cecum (the arrows)



**Fig. 2** Gastroscopy (A, B) revealed multiple erosions and telangiectasias in the antrum of stomach. Colonoscopy showed multiple round ulcers in terminal ileum and ileocecal valve and multiple yellow (C–E) dotted pseudomembranous attachments throughout colon (F)



**Fig. 3** Colonoscopy showed that the intestinal ulcers have no tendency to shrink following successful treatment of *Clostridium difficile* infection


Recently, studies show that trisomy 8 positivity MDS with Behçet's-like disease often performed as gastrointestinal ulcers. The bone marrow cells analysis of this patient

showed a karyotype of 47 XX,+8 (Fig. 4) accompanied with BCOP, IDH1, PHF6 and RUNX1 gene mutation. Detailed inquiry of medical history revealed epifolliculitis and frequently recurrent oral ulcers 2 months before admission. Based on the International Criteria for BD [5] which point score system that scoring  $\geq 4$  indicates BD, this patient scored 4. Above all, a diagnosis of trisomy 8 positivity MDS with BD was considered. The patient received glucocorticoid for BD along with the 5th course of azacytidine. Symptoms relieved and follow-up endoscopy (Fig. 5) showed significantly improved intestinal ulcer 2 months after treatment with glucocorticoid.

### Discussion and conclusion

The patient is an elderly man with recurrent abdominal pain and hematochezia. He had been diagnosed as MDS and had received 4 courses of chemotherapy and micro-transplantation. The first appearance of abdominal pain and hematochezia were during the fourth course of therapy. Whether the patient's intestinal ulcer is related to the MDS based on the theory of monism?

Nowadays, evidence showed a high frequency of trisomy 8 and intestinal ulcers are striking features of patients presented with both MDS and BD [2]. But the

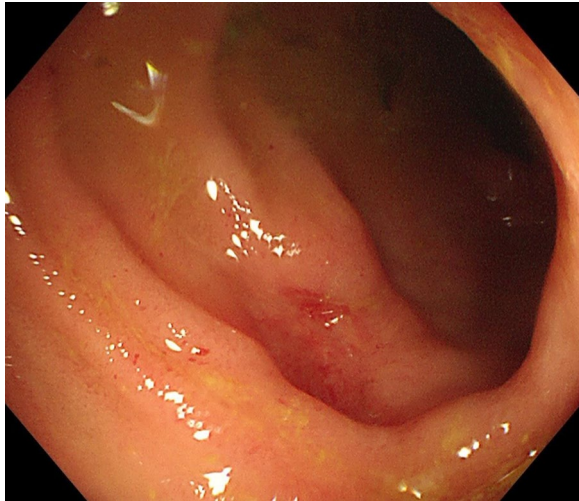


**Fig. 4** The bone marrow cells analysis of this patient showed a karyotype of 47 XX, +8

clinical phenotype, diagnosis, treatments and outcome are poorly reported. So far, only a total of 53 cases about Behçet's-like syndrome with trisomy 8 positivity MDS were reported in literature [6]. However, none of these reports accurately diagnosed BD from clinical symptoms, imaging and laboratory results. Diagnosis and treatment of these patient remains a challenging clinical task. Thus, prompt and accurate diagnosis of trisomy 8 positivity MDS with BD which involve

gastrointestinal ulcers may prevent unnecessary diagnostic procedures.

There are also several limitations in our report. We are unable to explain the association of trisomy 8 positivity MDS and BD. Whether BD as an intestinal performance of trisomy 8 positivity MDS need further verified. The characteristic and the best regimen for treatment of this disease is also unknown. Further studies are needed to determine the underlying mechanisms of trisomy 8.



**Fig. 5** Endoscopy showed significantly improved intestinal ulcer 2 months after treatment

#### Abbreviations

MDS: Myelodysplastic syndrome; MDN: Myeloproliferative neoplasm; BD: Behçet's disease; GI: Gastrointestinal; CTE: Computed tomography enterography.

#### Acknowledgements

Thanks to Dr. Xiping Zhou, Dr. Chen Mei, Dr. Hongyan Tong, who have helped in our diagnosis and treatment.

#### Authors' contributions

XFZ drafting of the manuscript. MJ do the critical revision of the manuscript. ZS, XYW, LL, YWZ, XPZ, CM and HYT participate in the patient's diagnosis and treatment. CHY is the study supervisor. All authors have read and approved the manuscript.

#### Funding

No funding was received.

#### Availability of data and materials

Data sharing is not applicable to this article as no datasets were generated or analysed during the current study.

#### Declarations

#### Ethics approval and consent to participate

Not applicable.

#### Consent for publication

Written informed consent was obtained from the patient for publication of this case report and any accompanying images. A copy of the written consent is available for review by the Editor of this journal.

#### Competing interests

The authors declare that they have no competing interests.

#### Author details

<sup>1</sup>Department of Gastroenterology, The First Affiliated Hospital, Zhejiang University School of Medicine, Hangzhou 310003, Zhejiang Province, China.

<sup>2</sup>Department of Hematology, The First Affiliated Hospital, Zhejiang University School of Medicine, Hangzhou 310003, Zhejiang Province, China.

Received: 26 May 2021 Accepted: 20 September 2021

Published online: 11 October 2021

#### References

- Garcia-Manero G. Myelodysplastic syndromes: 2014 update on diagnosis, risk-stratification, and management. *Am J Hematol.* 2014;89(1):97–108.
- Esatoglu SN, Hatemi G, Salihoglu A, Hatemi I, Soysal T, Celik AF. A reappraisal of the association between Behçet's disease, myelodysplastic syndrome and the presence of trisomy 8: a systematic literature review. *Clin Exp Rheumatol.* 2015;33(6):S145–51.
- McDonald LC, Gerding DN, Johnson S, Bakken JS, Carroll KC, Coffin SE, et al. Clinical practice guidelines for clostridium difficile infection in adults and children: 2017 update by the Infectious Diseases Society of America (IDSA) and Society for Healthcare Epidemiology of America (SHEA). *Clin Infect Dis.* 2018;66(7):987–94.
- Hagino T, Shinomiya W, Hidai H, Umeda M, Kurimoto M, Saga R, et al. Azacitidine-associated haemorrhagic enteritis in a case of myelodysplastic syndrome: a case report. *J Clin Pharm Ther.* 2020;45(4):828–31.
- International Team for the Revision of the International Criteria for Behçet's Disease (ITR-ICBD). The International Criteria for Behçet's Disease (ICBD): a collaborative study of 27 countries on the sensitivity and specificity of the new criteria. *J Eur Acad Dermatol Venereol.* 2014;28(3):338–47.
- Yilmaz U, Ar MC, Esatoglu SN, Bavunoglu I, Erzin YZ, Hatemi AI, et al. How to treat myelodysplastic syndrome with clinical features resembling Behçet syndrome: a case-based systematic review. *Ann Hematol.* 2020;99(6):1193–203.

#### Publisher's Note

Springer Nature remains neutral with regard to jurisdictional claims in published maps and institutional affiliations.

#### Ready to submit your research? Choose BMC and benefit from:

- fast, convenient online submission
- thorough peer review by experienced researchers in your field
- rapid publication on acceptance
- support for research data, including large and complex data types
- gold Open Access which fosters wider collaboration and increased citations
- maximum visibility for your research: over 100M website views per year

At BMC, research is always in progress.

Learn more [biomedcentral.com/submissions](https://biomedcentral.com/submissions)

