



■ HIP, ARTHROPLASTY

Serum cobalt concentrations remain at low levels at a minimum of 20 years following metal-on-metal total hip arthroplasty

**W. Waldstein,
U. Koller,
B. Springer,
P. Kolbitsch,
W. Brodner,
R. Windhager,
R. Lass**

*Department of
Orthopaedic and
Trauma Surgery,
Medical University of
Vienna, Vienna, Austria*

Aims

Second-generation metal-on-metal (MoM) articulations in total hip arthroplasty (THA) were introduced in order to reduce wear-related complications. The current study reports on the serum cobalt levels and the clinical outcome at a minimum of 20 years following THA with a MoM (Metasul) or a ceramic-on-polyethylene (CoP) bearing.

Methods

The present study provides an update of a previously published prospective randomized controlled study, evaluating the serum cobalt levels of a consecutive cohort of 100 patients following THA with a MoM or a CoP articulation. A total of 31 patients were available for clinical and radiological follow-up examination. After exclusion of 11 patients because of other cobalt-containing implants, 20 patients (MoM (n = 11); CoP (n = 9)) with a mean age of 69 years (42 to 97) were analyzed. Serum cobalt levels were compared to serum cobalt levels five years out of surgery.

Results

The median cobalt concentration in the MoM group was 1.04 µg/l (interquartile range (IQR) 0.64 to 1.70) at a mean of 21 years (20 to 24) postoperatively and these values were similar (p = 0.799) to cobalt levels at five years. In the CoP control group, the median cobalt levels were below the detection limit (< 0.3 µg/l; median 0.15 µg/l, IQR 0.15 to 0.75) at 20 years. The mean Harris Hip Score was 91.4 points (61 to 100) in the MoM group and 92.8 points (63 to 100) in the CoP group.

Conclusion

This study represents the longest follow-up series evaluating the serum cobalt levels after 28 mm head MoM bearing THA and shows that serum cobalt concentrations remain at low levels at a mean of 21 years (20 to 24) after implantation.

Cite this article: *Bone Joint Res.* 2020;9(3):146–151.

Keywords: Total hip arthroplasty, Metal-on-metal bearing, Cobalt levels

Article focus

- What are the serum cobalt levels at a minimum of 20 years following metal-on-metal (MoM) (Metasul; Sulzer, Winterthur, Switzerland) total hip arthroplasty (THA)?
- How do serum cobalt levels at 20 years following MoM (Metasul) THA compare to serum cobalt levels of a control group with a ceramic-on-polyethylene (CoP) articulation?
- What is the clinical and radiological outcome following THA with a MoM or a

CoP articulation at a minimum follow-up of 20 years?

Key messages

- Serum cobalt concentrations remain at low levels 21 years after implantation of 28 mm high-carbon MoM bearing THA, and in patients with unilateral hip implants serum cobalt concentrations are not different to the values recorded at five years (p = 0.799, Wilcoxon signed-rank test).

Correspondence should be sent to
W. Waldstein;
email: wwaldstein@gmail.com

doi: 10.1302/2046-3758.93.
BJR-2019-0218.R1

Bone Joint Res 2020;9:146–151.

- Cobalt concentrations in the MoM group were significantly higher ($p = 0.017$, Mann-Whitney U test) compared to serum cobalt levels in the CoP control group at 20 years.
- The Alloclassic Zweymüller system (Zimmer, Warsaw, Indiana, USA) is well-functioning at a mean of 21 years postoperatively with excellent clinical results and a low rate of relevant periprosthetic osteolysis.

Strengths and limitations

- Longest follow-up of small head MoM THA available in the literature.
- Young and active patient cohort.
- Small sample size.

Introduction

Second-generation metal-on-metal (MoM) articulations in total hip arthroplasty (THA) were introduced in 1988¹ in order to avoid polyethylene (PE) wear-related complications.² Good-to-excellent long-term results have been demonstrated for uncemented THA with small head MoM bearings.^{3–8} However, some designs of MoM hip implants have demonstrated poor survival and were consequently withdrawn from the market.^{9–11} Beside systemic effects of cobalt debris, it can also induce local effects like periprosthetic soft tissue reaction and osteolysis, which is described in literature as adverse reactions to metal debris (ARMD) and can cause THA failure.¹² With regard to large head MoM THA, it has been shown that especially implants with heads up to 54 mm diameter and the bilateral usage of MoM THAs may increase the risk for ARMD.¹³ The development of systemic symptoms, however, appears to be a rare complication.¹⁴ Toxic cobalt levels do not result in one pathognomonic clinical symptom but rather present as a combination of several systemic symptoms in association with a painful MoM hip prosthesis.^{14,15} The measurement of cobalt levels is not consistently described in the literature.^{16,17} Cobalt ions may be measured from whole blood, serum, erythrocytes, synovial fluid, or urine.^{18–20} Until now there has been no international consensus on the blood metal ion threshold(s) that should cause clinical concern after MoM THA. Consequently, the United States Food and Drug Administration currently does not use a specific threshold for identifying patients at high risk of ARMD,²¹ even though measurements of cobalt ion levels represent an important adjunct to the routine clinical and radiological workup of MoM implants.

Based on the available literature, this study represents the longest follow-up series evaluating the serum cobalt levels, as well as the clinical and radiological results using an uncemented implant with a 28 mm MoM bearing (Metasul; Sulzer, Winterthur, Switzerland).

The following research questions were asked: 1) how do serum cobalt levels at a minimum of 20 years following implantation of MoM (Metasul) THA compare to

previously published²² serum cobalt levels at five years?; 2) how do serum cobalt levels at 20 years following THA with a Metasul articulation compare to serum cobalt levels of a control group with a ceramic-on-polyethylene (CoP) articulation?; 3) what is the clinical and radiological outcome following THA with a MoM or a CoP articulation at a minimum follow-up of 20 years?

Methods

The present study provides an update of a previous prospective randomized controlled cohort at a minimum follow-up of 20 years.²² From January 1993 to November 1995, 100 patients underwent unilateral uncemented THA with the Alloclassic Zweymüller system. A group of 50 patients was treated with a MoM articulation (Metasul) and 50 patients received a CoP bearing (BioloX; CeramTec, Plochingen, Germany). A 28 mm head diameter was used in both groups. At the time of surgery, patients were free of cobalt-containing orthopaedic or dental implants and no degenerative changes were observed in other major joints. The methods pertaining to the randomization, hip implants, demographics of each group, and blood sample analysis are described in detail by Brodner et al.²² The Alloclassic Zweymüller system consists of a Ti-6Al-7Nb alloy femoral component and a conical self-tapping cement-free (CSF) cup, which is a conical screw cup made of commercially pure titanium. The articulation surface was the only implant parameter that differed between the groups. For this study, blood samples were taken after 20 years postoperatively. In order to compare the updated results with previous data, the same method as previously described by Brodner et al.²² was applied. Cobalt-free Vacutainer needles and Vacutainer glass tubes (Becton, Dickinson and Company, Franklin Lakes, New Jersey, USA) without additives were used for blood collection. Serum cobalt concentrations were measured with a 5100-ZL atomic absorption spectrometer (PerkinElmer, Shelton, Connecticut, USA) at a wavelength of 242.5 nm. The detection limit of cobalt in the serum in our laboratory is 0.3 µg/l and all concentrations below that limit were defined as 0.15 µg/l to allow statistical calculation. Depending on the hip articulation, patients were assigned to a MoM group or a CoP group, respectively.

For the current follow-up study, institutional review board approval was obtained. For a radiological assessment, standard anteroposterior pelvis and hip radiographs, as well as lateral radiographs of the affected hip, were reviewed in consensus by two different experienced reviewers (UK and BS). Acetabular osteolysis was evaluated according to the classification system of DeLee and Charnley.²³ Acetabular components with progressive radiolucent lines or evidence of migration of more than 3 mm were considered to be loose.²⁴ Femoral loosening was defined as axial subsidence on consecutive radiographs or varus or valgus tilting.²⁵ Femoral radiolucent lines or osteolysis were evaluated using the Gruen classification.²⁶

Table I. Reasons for exclusion of patients during the course of the study.

Reason for exclusion	Number of patients (n = 80)
Multimetal (e.g. contralateral THA, dental implants)	11
Excluded or lost to follow-up by previous study*	27
Death: six patients due to malignancy (two pancreatic cancer; one stomach cancer; one breast cancer; one lung cancer; one prostate cancer)	32
Revision surgery due to metallosis	2
Unwilling to return for follow-up because of age	4
Lost to follow-up	4

*Brodner et al.²²

THA, total hip arthroplasty.

Cup inclination was measured in relation to the horizontal inter-teardrop reference line.²⁷ Anteversion of the cup was measured as described by Widmer.²⁸

At a minimum of 20 years, 31 out of 100 patients were available for examination. A total of 32 patients had already died in the follow-up period at a mean age of 82 years (44 to 95) due to reasons unrelated to their THA. Of these patients, six died due to malignant tumours not associated with debris of the hip prosthesis (Table I). No patient died of renal failure. Four patients were lost to follow-up and four patients were unwilling to return to follow-up visits. A total of 27 patients were already excluded within the first five postoperative years as mentioned by Brodner et al.²² None of the patients who were unwilling to return or were lost to follow-up had signs of implant failure at the time of the most recent available follow-up. Two patients in the MoM group received a head/liner exchange due to metallosis after 12 years and 14 years, respectively. A total of 11 patients received a contralateral total hip or knee arthroplasty, or implantation of cobalt-containing orthopaedic or dental devices, after the fifth postoperative year, and were consequently excluded to avoid any bias of the serum cobalt concentrations (Table I). Patients with other cobalt-containing implants were labelled multimetal. The demographic data and cobalt concentrations of these multimetal patients were separately reported.

The final study cohort consisted of 20 patients (ten males, ten females) in 20 hips (MoM (n = 11); CoP (n = 9)) with a mean age of 69 years (42 to 97) and a mean body mass index (BMI) of 25.6 kg/m² (95% confidence interval (CI) 23.8 to 27.5) at a mean follow-up of 21 years (20 to 25). The MoM group and CoP control group were similar with regards to age (p = 0.549, Mann-Whitney U test), BMI (p = 0.113, Mann-Whitney U test), and sex (p = 0.182, Mann-Whitney U test).

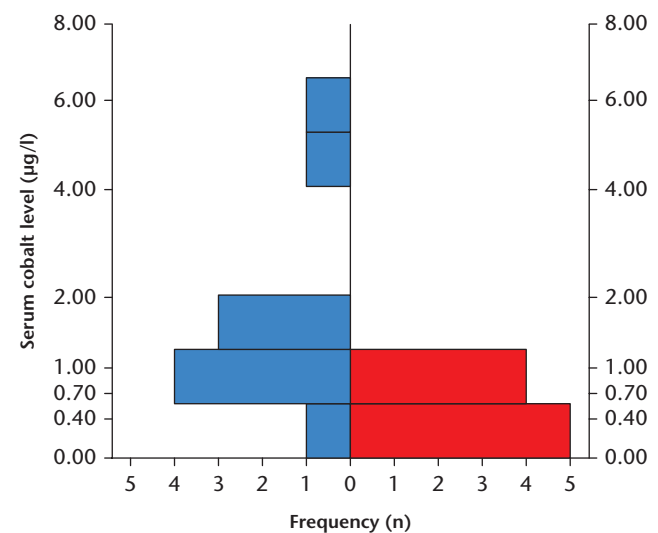
We also reviewed the 27 patients originally excluded by Brodner et al.²² Of these 27 patients, 20 patients had already died. Six patients died due to malignancy (two pancreatic cancer, one stomach cancer, one breast cancer, one lung cancer, one prostate cancer), six patients died due to heart disease, three patients died due to neurological disease, two patients due to infection, and one

patient due to cirrhosis. For two patients, we were not able to detect the reason of death. In one patient, the hip prosthesis was explanted due to a septic complication (eight years after implantation in a peripheral hospital), and three patients were lost to follow-up. Out of the 27 patients initially excluded, we were able to collect the cobalt levels of three patients at 20 years. In patient one, cobalt levels increased from 0.15 µg/l at five years to 0.8 µg/l at 20 years. In patient two, cobalt levels slightly decreased from 1.6 µg/l to 1.2 µg/l at 20 years. In patient three, an increase of serum cobalt to 4.4 µg/l at 20 years was observed. The cobalt levels in this patient were 1.1 µg/l at five years. The patient had received a contralateral hip prosthesis. The renal function was good (creatinine of 0.59 mg/dl with a reference of 0.50 mg/dl to 0.90 mg/dl) and the hip was well-fixed on radiographs.

Statistical analysis. The median as well as the interquartile range (IQR) of the cobalt concentrations were calculated for the two groups. For comparison of each patient's serum cobalt concentration, the Mann-Whitney U test was used. The absolute mean values of cup inclination were measured in degrees with 95% CI. The Mann-Whitney U test was performed to compare the distribution of two independent variables. A p-value of < 0.05 was regarded as significant for all tests. No power analysis was performed due to the descriptive nature of the study. Statistical tests were performed using SPSS Version 24 (IBM, Armonk, New York, USA).

Results

At a mean of 21 years postoperatively, the median cobalt concentration in the MoM group was 1.04 µg/l (IQR 0.64 to 1.7) and did not differ (p = 0.799, Wilcoxon signed-rank test) from cobalt levels at five years (Figure 1).

**Fig. 1**

Histogram illustrating the frequency (n) of respective serum cobalt levels (µg/l) in the metal-on-metal group (blue) and the ceramic-on-polyethylene group (red).

As previously reported, one young female patient with end-stage chronic renal failure had a high serum cobalt level of 119.20 $\mu\text{g/l}$ five years postoperatively. At 21 years, serum cobalt levels had decreased to 7.90 $\mu\text{g/l}$. The patient suffered from systemic lupus erythematosus which primarily affected her kidneys. Up to the last follow-up, this patient had undergone six renal transplantations. In the pathological workup, no cobalt deposits were observed in any failed kidney. With regard to the hip, the patient was doing very well with a Harris Hip Score (HHS) of 97 points. On radiographs, the implant was well-fixed with no signs of loosening. To avoid biased results, this patient was excluded from the statistical analysis.

In the CoP control group, the median cobalt levels were below the detection limit ($< 0.3 \mu\text{g/l}$; median 0.15 $\mu\text{g/l}$, IQR 0.15 to 0.75). Cobalt concentrations in the MoM group were significantly higher ($p = 0.017$, Mann-Whitney U test) compared to serum cobalt levels in the CoP control group at 20 years. Cobalt levels above the detection limit were found in four patients; two cases had a cobalt level of 0.70 $\mu\text{g/l}$, one case had a cobalt level of 0.80 $\mu\text{g/l}$, and one case had a cobalt level of 1.10 $\mu\text{g/l}$, respectively.

In the multimetal group, seven patients had a MoM bearing and four patients a CoP bearing. The multimetal group was slightly older than the rest of the patient cohort at last follow-up with a mean age of 78 years (63 to 92). Their mean BMI was 29.2 kg/m^2 (95% CI 25.0 to 33.5). The median cobalt concentration in patients with a MoM articulation and other cobalt-containing implants was 2.50 $\mu\text{g/l}$ (IQR 0.7 to 4.3). Patients with a CoP bearing and other cobalt-containing implants had a median cobalt concentration of 1.15 $\mu\text{g/l}$ (IQR 0.3 to 5.1).

Analyzing all 31 patients, similar ($p = 0.108$, Mann-Whitney U test) excellent clinical results (HHS) were observed in both groups, with a mean of 91.4 points (61 to 100) in the MoM group and a mean of 92.8 points (63 to 100) in the CoP control group. Two female patients aged 97 years and 92 years in the MoM group had poor clinical results with a HHS of < 70 points, due to their age-related limited mobility. In the CoP group, a 76-year-old female patient with end-stage osteoarthritis of the contralateral hip had a HHS of < 70 points.

Looking at all 31 patients, the mean cup inclination on anteroposterior (AP) pelvis radiographs was 47.6° (95% CI 45.9° to 49.4°) and the mean cup anteversion was 25.0° (95% CI 22.7° to 27.3°). No significant difference in cup inclination ($p = 0.457$, Mann-Whitney U test) and cup anteversion ($p = 0.819$, Mann-Whitney U test) was observed between the MoM and the CoP groups. Within the MoM group, no trend for higher cobalt levels in hips with higher inclination ($p = 0.735$, Spearman rank correlation) and hips with higher anteversion ($p = 0.513$, Spearman rank correlation) was observed. At the last follow-up, there was no evidence of implant loosening in any patient (Figure 2).

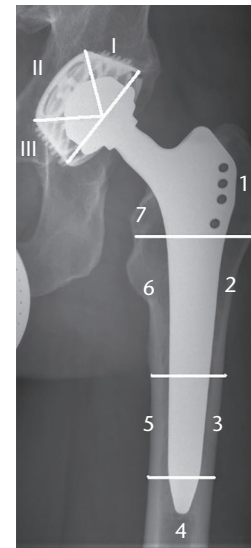


Fig. 2a

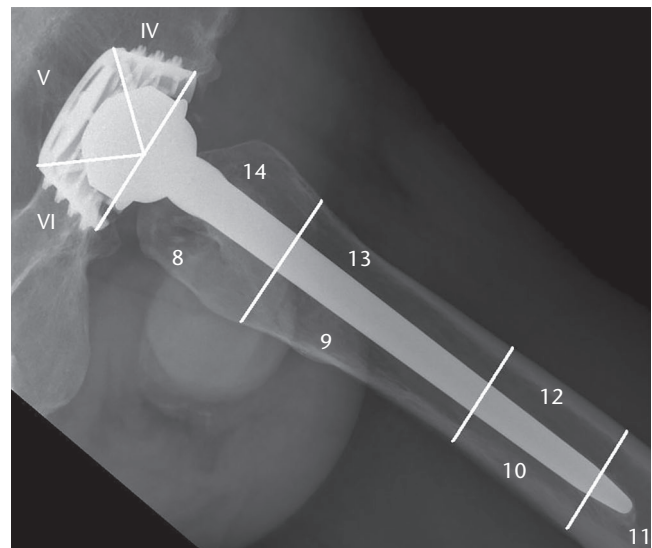


Fig. 2b

a) Distribution of radiolucent lines and osteolytic lesions observed on an anteroposterior radiograph of the femoral component (Gruen zones, 1 to 7²⁸) and the cup (DeLee classification, I to III²³) of a 56-year-old male patient at the last follow-up at 20 years. b) Distribution of radiolucent lines and osteolytic lesions observed on a lateral radiograph of the femoral component (Gruen zones, 8 to 14²⁸) and the cup (DeLee classification, IV to VI²³) of a 56-year-old male patient at the last follow-up at 20 years.

Discussion

Data on systemic cobalt levels with small head MoM THA with a follow-up of more than 15 years are limited.

The present study is the first to demonstrate that serum cobalt concentrations remain at low levels 21 years after implantation of 28 mm high-carbon MoM bearing (Metasul) THA. The results of this study are in line with an earlier report of our research group on a different patient cohort showing a median serum cobalt concentration of 0.70 $\mu\text{g/l}$ (IQR 0.4 to 2.1) at 17 years.²⁹ Savarino et al³⁰ reported similar mean serum cobalt values of 0.69 $\mu\text{g/l}$

(0.32 to 1.58) in 16 subjects with small head MoM at a minimum follow-up of eight years. Migaud et al⁷ published median whole blood cobalt concentrations of 0.95 µg/l (range 0.4 to 4.8) in 39 MoM (Metasul) hips at 12 to 14 years. Slightly higher mean whole blood cobalt concentrations of 1.8 µg/l (0.4 to 13.6) were seen in active female patients at a mean follow-up of 16 years.³

The results of this study might also suggest that long-term systemic exposure to low levels of cobalt does not lead to an increased rate of renal failure or malignancies. The incidence rate of malignant tumours in this study is consistent with the expected incidence rate of malignancies for the given period of time and number of patients.³¹

In the CoP control group, the median serum cobalt levels were below the detection limit. These findings are in line with previously reported serum cobalt concentrations of well-functioning unilateral CoP THAs.^{32,33}

At 20 years after surgery, the overall clinical results remained at a high level in comparison to previously reported clinical results five years postoperatively.²² These results were similar to those reported in the literature for THA with the Metasul bearing and a minimum follow-up of ten years.^{5,7} With regard to the radiological assessment, there was no evidence of cup migration or femoral component loosening at last follow-up. Minimal focal osteolytic lesions were observed surrounding the proximal femoral component. However, these mild radiological signs in Gruen zones 1, 7, 8, and 14 are a well-known phenomenon with the Zweymüller stem and do not suggest aseptic loosening (Figure 2).^{29,34}

The present study has some limitations. Only 20 of the 31 patients for whom serum cobalt analysis was performed at 20 years were eligible for final detailed analysis. In all, 11 patients were retrospectively excluded from comparative analysis; however, their median cobalt levels were separately reported. Furthermore, no radiological follow-up was available for the 27 patients who were already excluded in the previous study by Brodner et al.²² Finally, no CT scans were performed to detect osteolytic lesions or implant migration; consequently, the study might underestimate the presence of periprosthetic osteolysis.³⁵

In conclusion, this study represents the longest follow-up series evaluating the serum cobalt levels after 28 mm head MoM bearing THA, and shows that serum cobalt concentrations remain at low levels at a mean of 21 years after implantation, without any difference to the levels at five years.

References

1. Weber BG. [Metal-metal total prosthesis of the hip joint: back to the future]. *Z Orthop Ihre Grenzgeb.* 1992;130(4):306-309.
2. Kim YH, Kim JS, Park JW, Joo JH. Periacetabular osteolysis is the problem in contemporary total hip arthroplasty in young patients. *J Arthroplasty.* 2012;27(1):74-81.
3. Ayoub B, Putman S, Cholewinski P, Paris A, Migaud H, Girard J. Incidence of Adverse Reactions to Metal Debris From 28-mm Metal-on-Metal Total Hip Arthroplasties With Minimum 10 Years of Follow-Up: Clinical, Laboratory, and Ultrasound Assessment of 44 Cases. *J Arthroplasty.* 2017;32(4):1206-1210.
4. Desmarchelier R, Viste A, Chouteau J, Lerat JL, Fessy MH. Metasul vs Cerasul bearings: a prospective, randomized study at 9 years. *J Arthroplasty.* 2013;28(2):296-302.
5. Innmann MM, Gotterbarm T, Kretzer JP, et al. Minimum ten-year results of a 28-mm metal-on-metal bearing in cementless total hip arthroplasty in patients fifty years of age and younger. *Int Orthop.* 2014;38(5):929-934.
6. Malek IA, Rao SP, Rath NK, Mallya UN. Cemented metal-on-metal total hip replacement with 28-mm head: prospective, long-term, clinical, radiological and metal ions data. *Eur J Orthop Surg Traumatol.* 2015;25(4):749-755.
7. Migaud H, Putman S, Krantz N, Vasseur L, Girard J. Cementless metal-on-metal versus ceramic-on-polyethylene hip arthroplasty in patients less than fifty years of age: a comparative study with twelve to fourteen-year follow-up. *J Bone Joint Surg Am.* 2011;93-A Suppl 2:137-142.
8. Randelli F, Banci L, D'Anna A, Visentin O, Randelli G. Cementless Metasul metal-on-metal total hip arthroplasties at 13 years. *J Arthroplasty.* 2012;27(2):186-192.
9. Langton DJ, Jameson SS, Joyce TJ, Hallab NJ, Natu S, Nargol AV. Early failure of metal-on-metal bearings in hip resurfacing and large-diameter total hip replacement: A consequence of excess wear. *J Bone Joint Surg Br.* 2010;92-B(1):38-46.
10. Schouten R, Malone AA, Frampton CM, Tiffen C, Hooper G. Five-year follow-up of a prospective randomised trial comparing ceramic-on-metal and metal-on-metal bearing surfaces in total hip arthroplasty. *Bone Joint J.* 2017;99-B:1298-1303.
11. Bergiers S, Hothi HS, Henckel J, Eskelinen A, Skinner J, Hart A. Wear performance of retrieved metal-on-metal Pinnacle hip arthroplasties implanted before and after 2007. *Bone Joint Res.* 2018;7(11):595-600.
12. Smith AJ, Dieppe P, Vernon K, Porter M, Blom AW; National Joint Registry of England and Wales. Failure rates of stemmed metal-on-metal hip replacements: analysis of data from the National Joint Registry of England and Wales. *Lancet.* 2012;379(9822):1199-1204.
13. Kasperek MF, Renner L, Faschingbauer M, Waldstein W, Weber M, Boettner F. Predictive factors for metal ion levels in metal-on-metal total hip arthroplasty. *Arch Orthop Trauma Surg.* 2018;138(2):281-286.
14. Cheung AC, Banerjee S, Cherian JJ, et al. Systemic cobalt toxicity from total hip arthroplasties: review of a rare condition Part 1 - history, mechanism, measurements, and pathophysiology. *Bone Joint J.* 2016;98-B(1):6-13.
15. Goodnough LH, Bala A, Huddleston J III, Goodman SB, Maloney WJ, Amanatullah DF. Metal-on-metal total hip arthroplasty is not associated with cardiac disease. *Bone Joint J.* 2018;100-B:28-32.
16. De Smet K, De Haan R, Calistri A, et al. Metal ion measurement as a diagnostic tool to identify problems with metal-on-metal hip resurfacing. *J Bone Joint Surg Am.* 2008;90-A Suppl 4:202-208.
17. Hart AJ, Sabah SA, Bandi AS, et al. Sensitivity and specificity of blood cobalt and chromium metal ions for predicting failure of metal-on-metal hip replacement. *J Bone Joint Surg Br.* 2011;93-B(10):1308-1313.
18. Daniel J, Ziaee H, Pynsent PB, McMinn DJ. The validity of serum levels as a surrogate measure of systemic exposure to metal ions in hip replacement. *J Bone Joint Surg Br.* 2007;89-B(6):736-741.
19. Smolders JM, Bisseling P, Hol A, Van Der Straeten C, Schreurs BW, van Susante JL. Metal ion interpretation in resurfacing versus conventional hip arthroplasty and in whole blood versus serum. How should we interpret metal ion data. *Hip Int.* 2011;21(5):587-595.
20. Lass R, Gröbl A, Kolb A, et al. Comparison of synovial fluid, urine, and serum ion levels in metal-on-metal total hip arthroplasty at a minimum follow-up of 18 years. *J Orthop Res.* 2014;32(9):1234-1240.
21. Zywił MG, Cherian JJ, Banerjee S, et al. Systemic cobalt toxicity from total hip arthroplasties: review of a rare condition Part 2. measurement, risk factors, and step-wise approach to treatment. *Bone Joint J.* 2016;98-B(1):14-20.
22. Brodner W, Bitzan P, Meisinger V, Kaider A, Gottsauner-Wolf F, Kotz R. Serum cobalt levels after metal-on-metal total hip arthroplasty. *J Bone Joint Surg Am.* 2003;85-A(11):2168-2173.
23. DeLee JG, Charnley J. Radiological demarcation of cemented sockets in total hip replacement. *Clin Orthop Relat Res.* 1976;(121):20-32.
24. Zenz P, Stiehl JB, Knechtel H, Titzer-Hochmaier G, Schwagerl W. Ten-year follow-up of the non-porous Allofit cementless acetabular component. *J Bone Joint Surg Br.* 2009;91-B(11):1443-1447.
25. Engh CA, Bobyn JD, Glassman AH. Porous-coated hip replacement. The factors governing bone ingrowth, stress shielding, and clinical results. *J Bone Joint Surg Br.* 1987;69-B(1):45-55.

26. **Gruen TA, McNeice GM, Amstutz HC.** "Modes of failure" of cemented stem-type femoral components: a radiographic analysis of loosening. *Clin Orthop Relat Res.* 1979;(141):17-27.
27. **Waldstein W, Merle C, Schmidt-Braekling T, Boettner F.** Does stem design influence component positioning in total hip arthroplasty using a minimal invasive posterolateral approach? *Int Orthop.* 2014;38(7):1347-1352.
28. **Widmer KH.** A simplified method to determine acetabular cup anteversion from plain radiographs. *J Arthroplasty.* 2004;19(3):387-390.
29. **Lass R, Gröbl A, Kolb A, et al.** Primary cementless total hip arthroplasty with second-generation metal-on-metal bearings: a concise follow-up, at a minimum of seventeen years, of a previous report. *J Bone Joint Surg Am.* 2014;96-A(5):e37.
30. **Savarino L, Padovani G, Ferretti M, et al.** Serum ion levels after ceramic-on-ceramic and metal-on-metal total hip arthroplasty: 8-year minimum follow-up. *J Orthop Res.* 2008;26(12):1569-1576.
31. **No authors listed.** Statistic Yearbook for Austria 2017. http://www.statistik.at/web_de/services/stat_jahrbuch/index.html (date last accessed 20 February 2020).
32. **Barlow BT, Ortiz PA, Boles JW, Lee YY, Padgett DE, Westrich GH.** What Are Normal Metal Ion Levels After Total Hip Arthroplasty? A Serologic Analysis of Four Bearing Surfaces. *J Arthroplasty.* 2017;32(5):1535-1542.
33. **Nam D, Keeney JA, Nunley RM, Johnson SR, Clohisy JC, Barrack RL.** Metal Ion Concentrations in Young, Active Patients Following Total Hip Arthroplasty with the Use of Modern Bearing Couples. *J Arthroplasty.* 2015;30(12):2227-2232.
34. **Kolb A, Gröbl A, Schneckener CD, et al.** Cementless total hip arthroplasty with the rectangular titanium Zweymüller stem: a concise follow-up, at a minimum of twenty years, of previous reports. *J Bone Joint Surg Am.* 2012;94-A(18):1681-1684.
35. **Huber M, Reinisch G, Zenz P, Zweymüller K, Lintner F.** Postmortem study of femoral osteolysis associated with metal-on-metal articulation in total hip replacement: an analysis of nine cases. *J Bone Joint Surg Am.* 2010;92-A(8):1720-1731.

Author information

- W. Waldstein, MD, Consultant Orthopaedic Surgeon,
- U. Koller, MD, MSc, Consultant Orthopaedic Surgeon,
- B. Springer, MD, Registrar,
- P. Kolbitsch, MD, Registrar,
- R. Windhager, MD, Professor of Orthopaedic Surgery, Consultant Orthopaedic Surgeon,
- R. Lass, MD, MSc, Consultant Orthopaedic Surgeon, Department of Orthopaedic and Trauma Surgery, Vienna General Hospital, Medical University of Vienna, Vienna, Austria.
- W. Brodner, MD, Consultant Orthopaedic Surgeon, Department of Orthopedics, University Hospital Krems, Krems, Austria.

Author Contributions

- W. Waldstein: Prepared the manuscript, Performed the statistical analysis.
- U. Koller: Prepared the manuscript, Conceptualized and designed the study.
- B. Springer: Prepared the manuscript, Assessed the patients.
- P. Kolbitsch: Assessed the patients.
- W. Brodner: Drafted the manuscript.
- R. Windhager: Drafted the manuscript.
- R. Lass: Conceptualized, designed, and coordinated the study.

Funding statement

- No benefits in any form have been received or will be received from a commercial party related directly or indirectly to the subject of this article.

ICMJE COI statement

- None declared

Acknowledgements

- None declared

Ethical review statement

- The present study was approved by the local Ethic Committee of the Medical University of Vienna (IRB Number 1476/2014) and all patients gave their written informed consent.

©2020 Author(s) et al. This is an open-access article distributed under the terms of the Creative Commons Attribution Non-Commercial No Derivatives (CC BY-NC-ND 4.0) licence, which permits the copying and redistribution of the work only, and provided the original author and source are credited. See <https://creativecommons.org/licenses/by-nc-nd/4.0/>.