



## Case report

## Hidradenoma masquerading digital ganglion cyst: A rare phenomenon

Navnit Makaram <sup>a,\*</sup>, Iskander H. Chaudhry <sup>b</sup>, Makaram S. Srinivasan <sup>c</sup><sup>a</sup> Department of Surgery, Ninewells Hospital & Medical School, University of Dundee, Dundee, DD1 9SY, UK<sup>b</sup> St. James's University Hospital, 16 17 Beckett St., Leeds, West Yorkshire, LS9 7TF, UK<sup>c</sup> Royal Blackburn Hospital, East Lancashire Hospitals NHS Trust, Blackburn, BB2 3HH, UK

## HIGHLIGHTS

- We describe the rare phenomenon of an atypical cystic hidradenoma mimicking in presentation a mucous ganglion cyst on the DIPJ of the finger.
- We put this rarity into context by performing a literature review of reported presentations of such tumours.
- We emphasise the importance of a thorough and systematic assessment in patients presenting with such lesions.
- Also highlighted is the importance of considering these tumours in the differential diagnosis of lesions of the DIPJ.
- Thorough immunohistochemistry of resulting biopsies is invaluable in aiding diagnosis in these scenarios of ambiguous soft tissue swellings.

## ARTICLE INFO

## Article history:

Received 30 March 2016

Received in revised form

20 July 2016

Accepted 20 July 2016

## Keywords:

Hidradenoma

Ganglion cyst

Adnexal tumour

Eccrine

Hand

## ABSTRACT

**Introduction:** Mucous cyst is the commonest soft tissue tumor in the dorsum of the distal interphalangeal joint (DIPJ) of the finger. We report the first case of a recurring eccrine tumor (nodular hidradenoma), mimicking a mucous/ganglion cyst, on the dorsum of the DIPJ.

**Case report:** A 54 year old man presented with painless, hemispherical, colored swelling on the dorsum of his right middle finger (dominant hand), which appeared to have recurred from a previous surgery. The lesion was excised and operative findings from the medical notes showed the gross appearance to be a soft, white, glistening, smooth-surfaced, myxoid nodule resembling a “ganglion cyst”. Immunohistochemistry showed the tumour to be positive for S100, smooth muscle actin and cytokeratin 7. Ductal differentiation was confirmed by staining for epithelial membrane antigen and carcinoembryonic antigen. The histological features were that of atypical and solid cystic hidradenoma.

**Discussion:** This is the first reported case of this rare tumour presenting as mucous cyst. We conduct a review of the literature of nodular hidradenomas, illustrating the immunohistologic findings in this tumour to emphasise the atypical features. We emphasise the importance of considering hidradenoma in the differential diagnosis of such lesions of the finger, in view of its high recurrence rate and the possibility of malignant transformation.

© 2016 The Author(s). Published by Elsevier Ltd on behalf of IJS Publishing Group Ltd. This is an open access article under the CC BY-NC-ND license (<http://creativecommons.org/licenses/by-nc-nd/4.0/>).

## 1. Introduction

There are two types of digital ganglion or mucus cysts that develop on the dorsum of the digits between DIPJ and the proximal nail fold: (i) those arising typically secondary to osteoarthritis of the DIPJ, and (ii) those arising

independently of the joint, secondary to metabolic derangement of fibroblasts, producing hyaluronic acid. Both types of cyst occasionally cause mild pain or deformity of the nail bed secondary to pressure.

The clinical differential diagnoses of digital cyst include ganglion and synovial cysts, Heberden's nodes, gouty tophi, herpetic whitlow, molluscum contagiosum, rheumatoid nodules, sarcoidosis, post-trauma-induced nodules, giant cell tumour of tendon sheath, implantation dermoid, dermatofibroma, pyogenic granuloma, leiomyoma, and adnexal tumors. Rarely, malignant

\* Corresponding author.

E-mail addresses: [navnit\\_makaram@hotmail.co.uk](mailto:navnit_makaram@hotmail.co.uk) (N. Makaram), [i.h.chaudhry01@gmail.com](mailto:i.h.chaudhry01@gmail.com) (I.H. Chaudhry), [makaram@btinternet.com](mailto:makaram@btinternet.com) (M.S. Srinivasan).

conditions such as basal cell carcinoma, squamous cell carcinoma, and melanoma should be considered. For a definitive diagnosis, tissue examination of the lesion is required, with ancillary investigation such as immunohistochemistry in difficult cases.

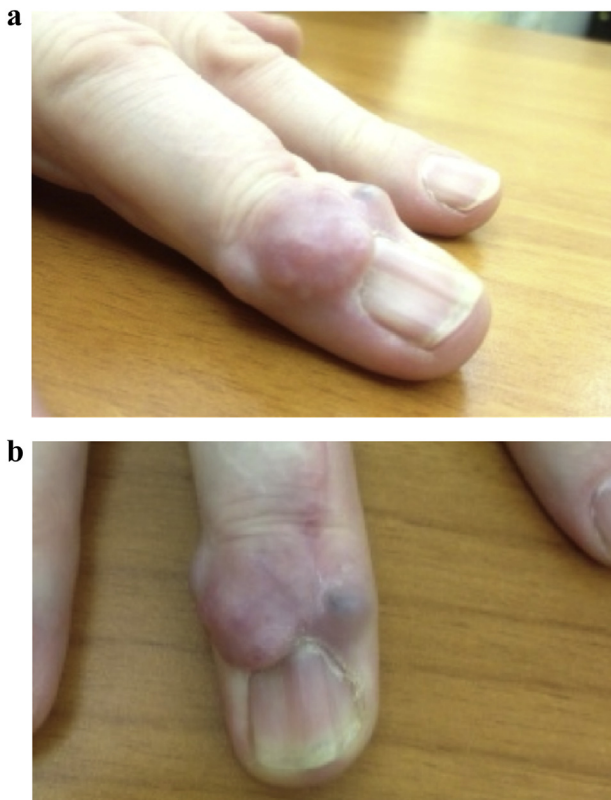
## 2. Case report

In July 2013, a 54-year-old man presented with a painless, hemispherical, skin-colored swelling on the dorsum of his right middle finger (dominant hand), which appeared to have recurred from a previous surgery. The lump had grown insidiously over a year to 15 × 8 mm, causing mild aching, and was a nuisance to the patient. The patient also had a recurrence of pea-sized lesions (8 × 8 mm) on the dorsal aspect of the same finger (Fig. 1). He worked as a self-employed furniture removals man.

Local examination revealed a soft, mobile skin-colored globular mass, with multiple bosselations, just distal to the DIPJ on the dorsum of the patient's right middle finger, with associated nail indentation.

There was also a healed surgical scar, indicating the site of failed previous surgery and recurrence. Trans-illumination test was negative and the skin over the swelling was shiny with no surface inflammation. Radiography showed that the joint space was normal and well preserved.

Review of the patient's notes showed that he had presented initially in April 2012 to another physician with a similar painless, hemispherical, skin-colored swelling on the dorsum of the same right middle finger (dominant hand). Local examination in 2012 by the previous hand surgeon revealed a pea-sized, soft, mobile, skin-colored globular mass just distal to the DIPJ. The operation notes stated that a curvilinear incision was used to excise the swelling.



**Fig. 1.** a: Swelling over DIP joint masquerading as digital ganglion cyst with previous surgical scar of prior surgical excision, and nail deformity. b: Swelling over DIP joint masquerading as digital ganglion cyst with previous surgical scar, and nail deformity.

Operative findings from the medical notes showed the gross appearance to be a soft, white, glistening, smooth-surfaced, myxoid nodule resembling a “ganglion cyst.” There was no obvious spur in the DIPJ. Postoperative histology reports were not available.

Based on this, a diagnosis of a possible recurrence of the mucous cyst was made, and the patient was listed for a revision surgery.

Wide local excision was made through a curvilinear incision, based proximally, and the skin flaps were raised very carefully to prevent any seeding. The swelling appeared to be 15 × 8 mm in diameter, with a bosselated nodular surface and a few cystic areas. The grayish bosselated soft tissue mass was excised totally from either side of the extensor tendon, with the attachment of this tendon to the distal phalanx preserved. Any spur or osteophyte in the region of the DIPJ was removed with fine rongeurs. The DIPJ and distal phalanx was covered with the proximally based skin flap de-rotated to cover the extensor tendon.

The postoperative course was uneventful, with the wound healing by primary intention in 12 days, and the patient regained full function and range of movement in 3 weeks.

Histologically, the tissue sample showed features of fibrous tissue containing a multi-nodular basaloid tumor showing peripheral palisade and high nuclear to cytoplasmic ratio (Fig. 2a–d). There was evidence of squamous morules and ductal differentiation. This lesion had an increased mitotic activity. Immunohistochemistry showed the tumor to be positive for S100, smooth muscle actin and cytokeratin 7. Ductal differentiation was confirmed by staining for epithelial membrane antigen and carcinoembryonic antigen. BerEP4 also highlighted the ducts, but the remaining tumor was negative. The proliferation index (Ki67 staining) was high. The lesion was found to be incompletely excised. The features differed from a conventional “hidradenoma”, given the increased mitotic activity and proliferation index, and the lesion was classified as “atypical solid and cystic hidradenoma.”

The histological results of the previous excised lesion in 2012 were then traced to the local National Health Service hospital, and were found to suggest that the primary lesion was suggestive of a “possible cystic hidradenoma;” however, immunohistochemistry had not been performed.

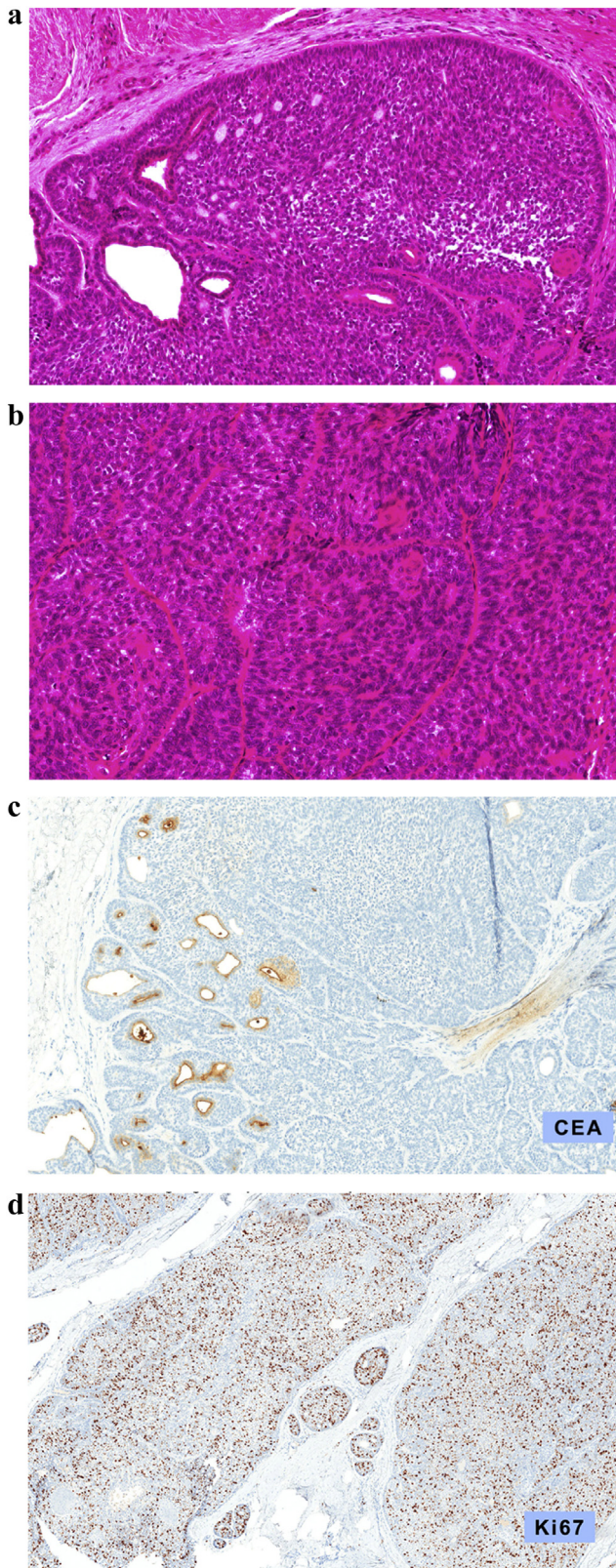
The differential diagnosis includes myoepitheliomas, poromas and aggressive digital papillary adenocarcinomas (ADPA). Myoepitheliomas tend to be circumscribed firm tumours, usually located in the deep soft tissue and have a pseudolobulated growth pattern with small cellular aggregates embedded within hyalinized and chondroid matrix. Poromas are distinguished from hidradenomas by their connection to the overlying epidermis. ADPAs are usually poorly circumscribed lesions, involving the dermis and subcutis and consist of both solid and cystic components; characteristically they show tubulo-alveolar and ductal structures with areas of papillary projections protruding into cystic lumina; such features are not evident in our case. Furthermore, ADPA is usually mistaken for a metastasis rather a primary adnexal tumour.

The patient has now been followed up regularly for over 2 years, and has been informed of the chance of recurrence and the unpredictability of lesions that have atypical features but fall short of a malignant diagnosis. Over the past 4 months, there has been little change in the finger appearance, and he continues to have normal function.

## 3. Discussion

Cutaneous adnexal tumours are a large group of benign and malignant neoplasms. They exhibit morphologic differentiation towards one of the four primary adnexal structures present in





**Fig. 2.** a.: Medium power photomicrograph (100 x magnification): the tumour nodules show peripheral palisade and ductal differentiation. b.: Medium power photomicrograph (200× magnification): Mitotic activity is evident. c.: Medium power photomicrograph (100× magnification): Ductal differentiation is highlighted by CEA antibody. d.: Medium power photomicrograph (100× magnification): This highlight the high proliferation index within the tumour islands.

normal skin: hair follicles, sebaceous glands, apocrine glands, and eccrine glands [1,2]. They either occur sporadically or may be markers of rare genetic syndromes, including Birt-Hogg-Dubé syndrome, Brooke-Spiegler syndrome, Cowden syndrome, and Muir-Torre syndrome [3]. Patients with multiple adnexal tumors should be evaluated for possible syndromes. Hidradenomas and other eccrine tumors are often located in the head and neck.

Hidradenoma is a benign adnexal tumor related to poroma that presents as a solitary nodule and can be either apocrine or eccrine, with variants including solid-cystic, clear (pale) cell, nodular, and poroid types. The term “acrosiroma” has also been used for the spectrum of hidradenoma and poroma [4].

Eccrine hidradenoma clinically presents as an asymptomatic, solitary, skin-colored intradermal nodule, elevated above the surrounding skin [4]. Although typically 5–60 mm, the average size of these nodules is 10 mm; the swelling that appeared as a recurrence on our patient’s hand within 6 months was 15 mm × 8 mm. Occasionally, there is a brown, blue, or reddish discoloration, and surface erosions or ulceration may be present. Larger lesions are irregular and lobulated. Hidradenoma is a slow-growing tumor; rapid growth may represent trauma, hemorrhage, or a malignant change [5].

Malignant adnexal tumors are rare, and typically affect older adults or individuals with familial tumor syndromes. The malignant counterpart has different clinico-pathologic features, such as larger size, infiltrative growth pattern, poor circumscription, nuclear enlargement and pleomorphism, increased mitotic activity, necrosis and ulceration [5].

Although clinical diagnosis of hidradenoma is confirmed histologically, errors can be made if histologic evidence is overlooked, as evidenced by our case. There is perhaps a need to be more cautious with recurring lesions, and investigate further with additional imaging e.g. ultrasonography examination. This case highlights the importance of considering adnexal tumors in the differential diagnosis.

Histopathological analysis can clearly distinguish these clinically similar pathologies.

For example, a digital mucous cyst is a pseudocyst, and the wall of the cyst is formed by fibrous tissue that contains amorphous, often myxoid material [6]. The cyst fluid is made up of hyaluronic acid, which is the predominant mucopolysaccharide within the cyst cavity [7]. The lesions are benign, and any recurrence after surgical excision should raise the possibility of alternate pathology in the swelling excised. By contrast, eccrine hidradenoma is a rare, benign tumor of eccrine gland origin that arises in the skin [8]. It usually presents in the third to fifth decade, with a greater predilection for females over males, in the ratio 1.7:1 [8]. Because of extensive overlap in the clinical features of cutaneous adnexal tumors, biopsy and immunohistochemistry are essential for diagnosis, and immunohistochemistry is particularly useful for the diagnosis of tumors with ambiguous histopathologic features.

A review of nodular hidradenomas by Hernandez-Perez and Cestoni-Parducci [9] showed a mean age at presentation of 37.2 years, with sites of involvement including the upper limb (25.8% of cases reviewed), trunk (20.2%), and most commonly the scalp (30.3%) [9]. These tumors have also been reported to appear in the breast, masquerading as ductal breast cancer with recurrence [10].

However, their involvement in the distal extremities, particularly the dorsum of the hand, is very rare [11]. A few have been reported from the foot. We believe our case to be the first to be reported on the dorsum of the finger in the region of the DIPJ, where sweat glands are relatively sparse as compared to the palmar side of the hand, sole of the foot and other regions such as the scalp.

Our case illustrates the varied occurrence of a hidradenoma, and

**Table 1**

MedLine, EMBASE review of all benign and malignant eccrine tumours in the hand – cases published.

No.	Site	Location	Histology	Author	Journal & Year
1	Hand	Finger	Hidradenocarcinoma	Nazeral RS et al.	<i>Ann Plast Surg</i> 2013, Mar 11
2	Hand	Dorsum of nail bed	Bengin eccrine poroma	Wilson KM, Jubert AV Joseph JL	<i>J Hand Surg Eur</i> 2009; 34:402–403
3	Hand	Palm	Benign eccrine poroma	Rasool MN, Hawary MB	<i>Ann Saudi Med</i> 2004; 24:46–467
4	Hand	Thumb	Eccrine carcinoma	Gohla T, Van Schoonhoven J, Lanz U	<i>Handchir Mikrochir Plast Chir</i> 2004; 36:333–336 (German)
5	Hand	Hand	Malignant eccrine poroma	O'Toole G, Gateley D	<i>J R Soc Med</i> 1999; 92:410
6	Hand	Hand	Malignant eccrine paroma	DaSilva MF, Terek R, Weiss AP	<i>J Hand Surg Am</i> 1997; 22:511–514
7	Hand	Hand	Recurrent eccrine acrospiroma	Kalainov DM, DiCarlo EF, Yang SS, Weiland AJ	<i>J Hand Surg Br</i> 1996; 21:280–282
8	Hand	Hand	Malignant acrospiroma		<i>J Hand Surg Am</i> 1989; 14:531–535 (Review)

**Table 2**

Classification of cutaneous adnexal tumors.

Tumor type	Derivation	Genetic abnormalities
<b>Sweat gland tumors, benign</b>		
Poroma (classic poroma, hidrocanthoma simplex, dermal duct tumor)	Eccrine or apocrine	LOH in APC
Hidradenoma	Eccrine or apocrine	t(11:19) <i>MAML2;MECT1</i>
Hidradenoma papilliferum	Anogenital apocrine	
Spiradenoma/cylindroma	Eccrine or apocrine	<i>CYLD</i> mutation/ <i>LDH</i>
Mixed tumor	Sweat duct ± follicular	
Syringofibroadenoma	Eccrine	
Syringoma	Eccrine or apocrine	
Syringocystadenoma papilliferum	Apocrine	9p21 deletion; 9q22 LOH
Tubular/papillary adenoma	Eccrine or apocrine	
<b>Sweat gland tumors, malignant</b>		
Porocarcinoma	Eccrine or apocrine	
(Aggressive) digital papillary adenocarcinoma	Eccrine or apocrine	
Adenoid cystic carcinoma	Eccrine or apocrine	
Apocrine adenocarcinoma	Apocrine	
Syringomatous carcinoma	Eccrine or apocrine	
Hidradenocarcinoma	Eccrine or apocrine	
Malignant mixed tumor	Eccrine or apocrine	
Cylindrocarcinoma/spiradenocarcinoma	Eccrine or apocrine	<i>CYLD</i> mutation/ <i>LOH</i>
Mucinous carcinoma	Eccrine or apocrine	
Microcystic adnexal carcinoma	Eccrine or apocrine	
Extramammary Paget's disease	Multiple possibilities	Chr 19 & X amplification; 10q loss
<b>Follicular and sebaceous tumors, benign</b>		
Trichoblastoma/trichoepithelioma	Follicular	<i>CTNNB1</i> , <i>CYLD</i> , <i>PTCH1</i> mutations
Trichofolliculoma	Follicular	
Panfolliculoma	Follicular	
Proliferating follicular-cystic acanthoma (proliferating pilar tumor)	Follicular (outer root sheath)	
Trichilemmoma	Follicular (outer root sheath)	<i>HRAS</i> , <i>PTEN</i> mutations
Trichoadenoma	Follicular (infundibulum)	
Tumor of the follicular infundibulum	Follicular (isthmus)	
Pilar sheath acanthoma	Follicular (isthmus/infundibulum)	
Pilomatricoma	Follicular (matrix)	<i>CTNNB1</i> mutation; trisomy 18
Sebaceous adenoma	Sebaceous gland	<i>LEF1</i> , <i>MLH1</i> , <i>MSH2</i> , <i>MSH6</i> mutation
Sebaceoma	Sebaceous gland	<i>LEF1</i> , <i>MLH1</i> , <i>MSH2</i> , <i>MSH6</i> mutation
Fibrofolliculoma/trichodiscoma	Sebaceous mantle	<i>FLCN</i> mutation
<b>Follicular and sebaceous tumors, malignant</b>		
Trichoblastic carcinoma	Follicular	
Trichilemmal carcinoma	Follicular (outer root sheath)	
Pilomatrix (metrical) carcinoma	Follicular (matrix)	<i>CTNNB1</i> mutation
Sebaceous carcinoma	Sebaceous	<i>LEF1</i> , <i>MLH1</i> , <i>MSH2</i> , <i>MSH6</i> mutation

LOH; Loss of heterozygosity.

Adapted from North et al. *Cutaneous adnexal tumors*. Wolters Kluwer Health. Up to date 4 February 2015.

is the first to be reported in the dorsum of the middle finger, masquerading as a mucous cyst. We found just 129 recorded cases of the family of hidradenomas in the English literature (eccrine poromas and solid cystic hidradenomas), with only 8 of them

presenting on the hand. All of them were listed as benign or malignant eccrine poromas, except one, which was a malignant counterpart of hidradenoma. However, all presented in areas of the palmar surface of the hand that are not usual locations for digital

mucous cyst (Table 1). The classification of cutaneous adnexal tumors is presented in Table 2.

#### 4. Conclusion

•Our case illustrates the importance of including eccrine hidradenoma, a very rare tumor, in the differential diagnosis of soft-tissue swellings of the hand. An awareness of this rare tumour and exclusion at the outset is crucial for effective clinical management. This case highlights the importance of sending biopsies of all hand lesions for histological examination, and tracing reports before repeat surgery. There should not be any hesitation to perform immunohistochemistry, if needed. This practice would help identify rare pathologies and allow patients to be warned of the potential chances of recurrence. It would also alleviate patient anxiety, and prepare for a rare possibility of a low-grade malignant change and need for wide local excision with negative surgical margins or Mohs micrographic surgery [12].

This has been reported in line with CARE Criteria [13].

#### Ethical approval

Not required for this case report.

#### Sources of funding

Study sponsors had no involvement or role in study.

#### Author contribution

Dr Makaram was involved in the data collection, interpretation, and manuscript preparation.

Dr Chaudhry was involved in immunohistochemistry data collection, tissue sample data processing, and assisted in manuscript preparation.

Mr Srinivasan oversaw the creation of the report and was additionally involved in the care of the patient.

#### Conflicts of interest

No conflicts of interest.

#### Research registry UIN

Registered with Research Registry as part of the World Medical

Association's Declaration of Helsinki 2013 article 35. researchregistry1095.

#### Guarantor

Dr Navnit Makaram.  
Dr Iskander Chaudhry.  
Mr Srinivasan.

#### Consent

Written and signed consent gained.

#### References

- [1] K.O. Alsaad, N.A. Obaidat, D. Ghazarian, Skin adnexal neoplasms—part 1:an approach to tumours of the pilosebaceous unit, *J. Clin. Pathol.* 60 (2) (2007) 129–144.
- [2] N.A. Obaidat, K.O. Alsaad, D. Ghazarian, Skin adnexal neoplasms—part 2:an approach to tumours of cutaneous sweat glands, *J. Clin. Pathol.* 60 (2) (2007) 145–159.
- [3] D.A. Lee, M.E. Grossman, P. Schneiderman, J.T. Celebi, Genetics of skin appendage neoplasms and related syndromes, *J. Med. Genet.* 42 (11) (2005) 811–819.
- [4] L.D. Dodge, R.L. Brown, J.J. Niebauer, H.R. McCarroll Jr., The treatment of mucous cysts:long term follow-up of sixty two cases, *J. Hand Surg. Am.* 9 (6) (1984) 901–904.
- [5] C.M. Stefanato, G. Ferrara, I.H. Chaudhry, C. Guevara Pineda, G. Waschkowski, C. Rose, E. Calonje, Clear cell nodular hidradenoma involving the lymphatic system: a tumor of uncertain malignant potential or a novel example of “metastasizing” benign tumor? *Am. J. Surg. Pathol.* 36 (12) (2012) 1835–1840.
- [6] M. Rizzo, R.D. Beckenbaugh, Treatment of mucous cysts of the fingers:review of 134 cases with minimum 2 year follow-up evaluation, *J. Hand Surg. Am.* 28 (3) (2003) 519–524.
- [7] B.J. Wilhelmi, E.A. Appelt, L.G. Philips, A rare case of atypical eccrine acrospinoma of the scalp and a literature review., *Ann. Plast. Surg.* 42 (5) (1999) 568–569.
- [8] N. Shaikh-Naidu, A. Breitbart, Eccrine spiradenoma of the upper extremity: case report and an algorithm for management, *Eur. J. Plast. Surg.* 26 (2003) 160–163.
- [9] E. Hernandez-Perez, R. Cestoni-Parducci, Nodular hidradenoma and hidradenocarcinoma:a 10-year review, *J. Am. Acad. Dermatol.* 12 (1) (1985) 15–20.
- [10] P.J. Mullaney, E. Becker, B. Graham, D. Ghazarian, R.H. Riddell, D.C. Salonen, Benign hidradenoma:magnetic resonance and ultrasound features of two cases, *Skelet. Radiol.* 36 (12) (2007) 1185–1190.
- [11] D. Touma, M. Laporte, A. Goossens, Ledoux M Malignant clear cell hidradenoma, *Dermatology* 186 (4) (1993) 284–286.
- [12] Ad Hoc Task Force, S.M. Connolly, D.R. Baker, et al., AAD/ACMS/ASDSA/ASMS 2012. Appropriate use criteria for Mohs micrographic surgery:a report of the American Academy of Dermatology, American College of Mohs surgery, American Society for Dermatologic surgery association, and the American Society for Mohs surgery, *J. Am. Acad. Dermatol.* 67 (4) (2012) 531–550.
- [13] J.J. Gagnier, G. Kienle, D.G. Altman, D. Moher, H. Sox, D. Riley, The CARE Group. The CARE guidelines: consensus-based clinical case report guideline development, *J. Clin. Epidemiol.* 67 (1) (2014) 46–51.