

Case Report

Primary single stage Total Hip Arthroplasty in a patient 40 years post traumatic Hip dysplasia, a case report

Krisna Yuarno Phatama^{*}, Ananto Satya Pradana, Edi Mustamsir, Mohamad Hidayat, Satria Wira Sakti, Ray Asaf Hexa Pandiangan, Surya Iman Muhammad, Marvin Anthony Putera

^a Orthopaedic and Traumatology Department, Faculty of Medicine Brawijaya University, Saiful Anwar General Hospital, Malang, Indonesia

ARTICLE INFO

Keywords:

Hip dysplasia
Post traumatic Hip dysplasia
Total Hip Arthroplasty
Total hip replacement

ABSTRACT

Introduction: Hip dysplasia refers to an abnormal development of size, shape, or organization of the femoral head, acetabulum, or both. Managing acetabular dysplasia is very challenging in arthroplasty especially in traumatic hip dysplasia case. Mostly, hip dysplasia cases need a special implant, procedure and techniques.

Case presentation: We performed primary Total Hip Arthroplasty (THA) + partial tenotomy of hamstring, iliotibial band, hip abductor in a 73 year old male. His main complaint was that he was unable to sit due to an increasingly intense pain since 3 months ago and he has been unable to walk properly since 40 years ago when he had a major traffic accident and received inadequate treatment. The procedure had been successfully done using a well press-fit cementless acetabular cup and a cementless narrow stem application 1 cm on leg length discrepancy (LLD).

Conclusion: Preoperative planning, surgical techniques and a post-surgery rehabilitation are the key to a successful management in this case.

Introduction

Hip dysplasia refers to an abnormal development of size, shape, or organization of the femoral head, acetabulum, or both. These changes may increase the contact pressures on the joint and hip arthrosis. However, before the development of frank degenerative changes, many patients become symptomatic because of abnormal hip biomechanics, hip instability, impingement, or labral and chondral pathologies. These processes arise from increased and abnormal forces across the joint with resultant shear forces. Changes commonly appear at the anterolateral region of the acetabulum, the posterior region of the femoral head, or the femoral head and neck junction [1].

Managing acetabular dysplasia is very challenging in arthroplasty especially in traumatic hip dysplasia case. Mostly, hip dysplasia recovery needs special implant, procedure and techniques. Total Hip Arthroplasty, also called total hip replacement (THR), is deemed to be successful since it has been suggested as “the operation of the century” [2]. It is the main orthopaedics surgical procedure which is cost-effective to recover pain mobility in patients [3]. In this report, we present the care management of a 40-year old patient with post traumatic acetabular dysplasia by using primary single stage cementless THA which is cost-effective.

^{*} Corresponding author.

E-mail addresses: krisnayurno@ub.ac.id (K.Y. Phatama), edimustamsir@ub.ac.id (E. Mustamsir), moh_hidayat@ub.ac.id (M. Hidayat).

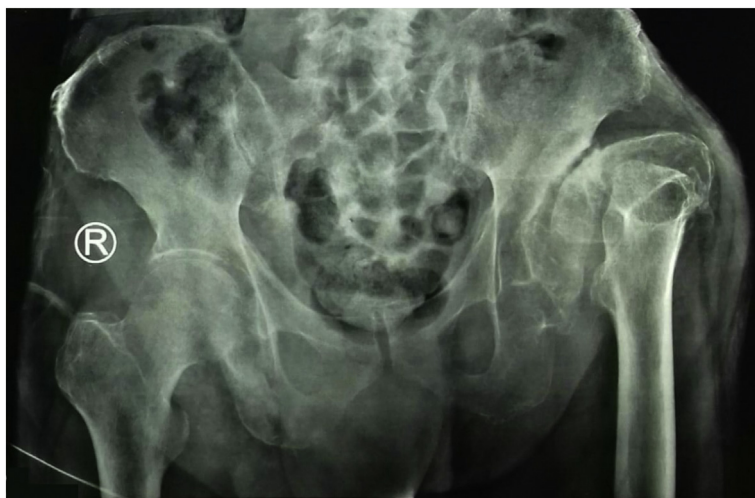

Fig. 1. Radiographic image of hip initial condition.

Case

A 73 year old male was unable to sit for 3 months due to a severe pain, and unable to walk properly since 40 years ago when he had a major traffic accident and received inadequate treatment (Harris hip score 11, with LLD 4 cm). Before the accident, this patient had a normal hip. The patient was diagnosed with traumatic acetabular hip dysplasia. Therefore, a primary THA was performed. During the surgery, we encountered shallow acetabulum, porotic bone and thigh abductor muscle (Fig. 1).

Acetabulum medialization and rimming was performed using a small size reamer with well press-fit cementless acetabular cup and cementless narrow femoral stem application 1 cm on LLD. We did partial tenotomy of hamstring, iliotibial band, hip abductor as well to overcome the tightness of abductor muscle, so that the hip position could be more relax and had a wider range of motion (Fig. 2).

After the surgery, the patient underwent rehabilitation to recover the muscle strength and gait balance. The evaluation conducted three months after the surgery showed a better Harris score (Harris score 52). Six months post the surgery, the score became better, with Harris hip score of 79, and the patient was able to walk without pain using a walker.

An informed consent was obtained from the patient for the treatment of the injury and publication of radiographic materials without any personal identification.

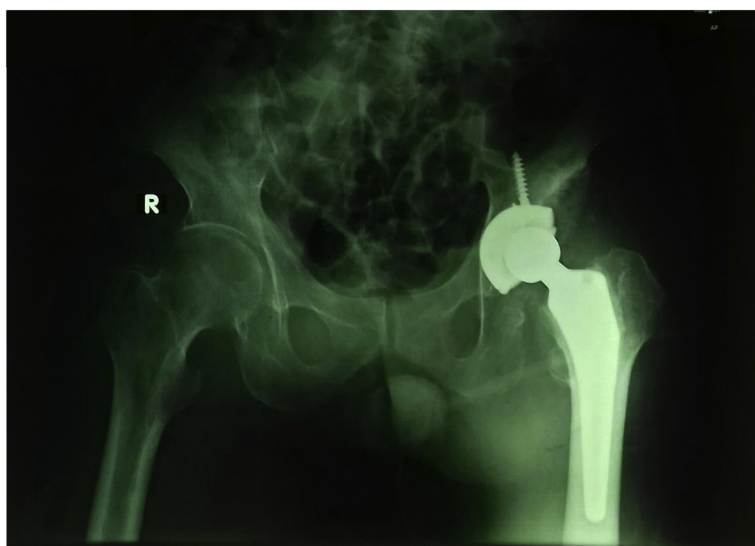


Fig. 2. Radiographic image after total hip arthroscopy surgery.

Discussion

THA is challenging to be done in neglected posterior dislocation of the hip with posterior wall and column fracture of the acetabulum with altered anatomy. When a dislocation has been neglected for a long time, compensatory and adaptive changes take place in and around the hip joint. Neglected dislocations of the hip are rare, and open reduction leads to avascular necrosis and subsequent arthritis of the hip joint [4]. Poor bone stock and a high riding femoral head make it difficult to reduce the head in the acetabulum. Furthermore, capsular and muscular contractures make exposure becomes troublesome. It results the acetabular wall fragments unite with fibrous/bony unions [5].

Osteonecrosis of the femoral head can occur after a hip dislocation and is a poor prognostic indicator of clinical outcomes. Previous studies have documented an osteonecrosis rate of 4.8% in patients which was reduced in less than 6 h after the injury took place, whereas a 52.9% rate was seen in hips reduced after 6 h from injury. Weight bearing was not shown to have a significant effect on osteonecrosis in this study. Patients should be followed with imaging to monitor for signs of osteonecrosis. Osteonecrosis usually appears within 2 years following the injury, but it has to be observed for as long as 5 years after injury [6].

Arthritis is the most common complication in patients who have sustained a traumatic hip dislocation. Posttraumatic arthrosis has been shown to occur in up to 24% of patients; those who have a sedentary lifestyle have lower rates after 14 years of follow-up. Those involved in heavy manual labor after traumatic accidents were shown to have up to 37.5% incidence rate of posttraumatic arthritis. The damage to the chondrocytes at the time of the injury has been hypothesized to be responsible for the incidence of late arthritis after dislocation. It is important to counsel patients about the long-term sequelae of these injuries [7].

Several months before the surgery, the pain became worse, specifically identified as groin and buttock pain. The patient was unable to mobilize except sitting, due to the pain. The presence of groin and buttock pain, associated with hip dysfunction, is strongly related to osteoarthritis.

The ongoing discussion of the best treatment option for the management of neglected dislocation hip remains a controversy. Various studies reported different methods for operative treatment of neglected fracture–dislocations including the use of a sub-trochanteric osteotomy, the Girdlestone procedure, hip arthrodesis, hemiarthroplasty and THA [8]. Recently, THA is deemed to be very successful since it has been suggested as “the operation of the century”. It is a main orthopaedics surgical procedure and cost-effective to restore pain-free mobility in patients with degenerative bone and joint diseases. Pain and loss of mobility are the most common preoperative complaints of patients prior to a THA [2].

In advanced cases, despite the patient had received full conservative management, persistent pain, limited mobility and night pain is occasionally present. Pre-existing hip disease is a valid indication for primary THA. When there are complications with the internal fixation of a femoral neck fracture, such as the loss of articular cartilage in the acetabulum, or when endoprosthesis has failed in acute fractures, a THA is a good solution [9]. Common indications are osteoarthritis, post-traumatic arthritis, rheumatoid arthritis including juvenile rheumatoid arthritis, avascular necrosis, hardware failure after internal fixation of hip fractures, congenital hip dislocations and dysplasia [10]. THA is recommended for hip dislocations which lasts more than 3 months [9]. Based on this statement, hip replacement is seen as the best solution.

Primary cementless THA needs well press-fit acetabular component. Therefore, medialization and new acetabular farming using small size reamer is crucial for gaining the stability of cementless acetabular cup. Small size acetabular ream and cup was a good option to provide good implant bone coverage. Soft tissue release is also an important procedure that patients need to undergo to provide more hip flexibility during post-operative rehabilitation procedure. After all, a good pre-operative planning and surgical technique were of crucial factors, and must be followed by proper rehabilitation for achieving the best result.

Osteoarthritis of the hip with acetabular dysplasia is a challenging case to be treated. In some cases they can be treated by primary hip replacement, instead of using revision implant. Acetabular component and soft tissue balance are the trickiest problems to manage. After all, this case is managed well, raising the Harris Hip Score of 11 (pre-operative) to 79 in 6 months after the treatment.

Declaration of Competing Interest

The authors declare no potential conflicts of interest with respect to the authorship, and/or publication of this article.

Acknowledgement

This research did not receive any specific grant from funding agencies in the public, commercial or not-for-profit sectors.

References

- [1] J. Sanchez-Sotelo, R.T. Trousdale, D.J. Berry, M.E. Cabanela, Surgical treatment of developmental dysplasia of the hip in adults: I. Nonarthroplasty options, *J Am Acad Orthop Surg* 10 (5) (2002) 321–333 Sep-Oct.
- [2] I.D. Learmonth, C. Young, C. Rorabeck, The operation of the century: total hip replacement, *Lancet* 370 (2007) 1508–1519.
- [3] J.-P. Courpied, J. Caton, Total hip arthroplasty, state of the art for the 21st century, *Int. Orthop.* 35 (2011) 149–150.
- [4] A. Pankaj, M. Sharma, V. Kochar, V. A. Naik. (2011): Neglected, locked, obturator type of inferior hip dislocation treated by total hip arthroplasty. *Arch. Orthop. Trauma Surg.*;131(4):443–6. doi: <https://doi.org/10.1007/s00402-010-1141-0>. [PubMed: (20567838)].
- [5] D.C. Sundaresh, S.K. Ramanath, A. Grover, D. Gadi, Uncemented total hip replacement after two years of neglected hip dislocation with fracture of posterior column and wall of the acetabulum, *Trauma Mon.* 21 (2016), <https://doi.org/10.5812/traumamon.25301>.
- [6] K. Hougaard, P.B. Thompson, Traumatic posterior dislocation of the hip—prognostic factors influencing the incidence of avascular necrosis of the femoral head, *Arch. Orthop. Trauma Surg.* 106 (1) (1986) 32–35.

- [7] S. Sanders, N. Tejawani, K.A. Egol, Traumatic hip dislocation: a review, *Bull. NYU Hosp. Jt. Dis.* 68 (2010) 91–96.
- [8] A.K. Banskota, D.A. Spiegel, S. Shrestha, O.P. Shrestha, T. Rajbhandary, Pen reduction for neglected traumatic hip dislocation in children and adolescents, *J. Pediatr. Orthop.* 27 (2) (2007) 187–191.
- [9] J.C. Garrett, H.C. Epstein, W.H. Harris, J.P. Harvey Jr., V.L. Nickel, Treatment of unreduced traumatic posterior dislocations of the hip, *J. Bone Joint Surg. Am.* 61 (1979) 2–6.
- [10] S. Affatato, *Perspectives in Total Hip Arthroplasty: Advances in Biomaterials and Their Tribological Interactions*, Woodhead Publishing, London, 2014.