

“Owl’s eyes” sign in acute spinal cord infarction in newborn submitted to aortoplasty

Sinal dos “olhos de coruja” em infarto espinal agudo em recém-nascido submetido a aortoplastia

Arthur Cesario de Holanda¹ Mayllin Freitas Nunes² Fabiola Lys de Medeiros²
Eduardo Sousa de Melo^{1,3}

¹ Universidade Federal de Pernambuco, Hospital das Clínicas, Unidade de Neurologia e Neurocirurgia, Recife PE, Brazil.

² Universidade de Pernambuco, Hospital Universitário Oswaldo Cruz, Recife PE, Brazil.

³ Universidade Federal de Pernambuco, Centro de Ciências Médicas, Recife PE, Brazil.

Address for correspondence Eduardo Sousa de Melo (e-mail: eduardosoumelo@gmail.com).

Arq. Neuropsiquiatr. 2022;80(11):1184.

A 12-day-old male patient underwent aortoplasty for aortic arch coarctation with patent ductus arteriosus and ventricular septal defect. On the 5th postoperative day, he presented with acute hyporeflexia, tetraparesis, and urinary retention. On spinal magnetic resonance imaging (MRI), sagittal T2-weighted image (T2WI) indicated abnormal hyperintensity extending from D1 and D2 to the conus medullaris, affecting the anterior two thirds of the spinal cord (→**Figure 1A**).

Additionally, axial T2WI showed the “owl’s eyes” sign involving the anterior-central cord (→**Figures 1B-C**) and sagittal T1WI unremarkable (→**Figure 1D**).

Pediatric acute spinal cord infarction is rare, and the “owl’s eyes” sign on neuroimaging is highly suggestive of vascular etiology. This case is the youngest of the few ever reported in which an “owl’s sign” could be observed.¹⁻³

Authors’ Contributions

ACH: study design, patient data collection and interpretation, and manuscript writing; MFN: patient data collection and manuscript writing; FLM, ESM: data interpretation and manuscript critical review.

Conflict of Interest

The authors have no conflict of interests to declare.

References

- Morshid A, Jadiry HA, Chaudhry U, Raghuram K. Pediatric spinal cord infarction following a minor trauma: a case report. *Spinal Cord Ser Cases* 2020;6(01):95
- Sheikh A, Warren D, Childs A-M, et al. Paediatric spinal cord infarction—a review of the literature and two case reports. *Childs Nerv Syst* 2017;33(04):671–676
- Nance JR, Golomb MR. Ischemic spinal cord infarction in children without vertebral fracture. *Pediatr Neurol* 2007;36(04):209–216

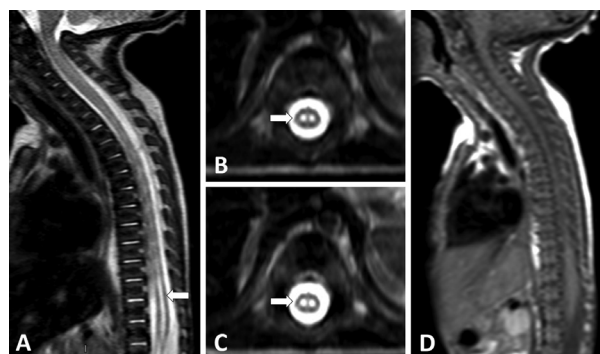


Figure 1 Spinal cord magnetic resonance imaging (MRI) performed at 17 days of age. Sagittal T2-weighted imaging (T2WI) shows a diffuse pencil-like hyperintense signal from D1 to the conus medullaris ((A)), and axial T2WI shows symmetric circular-ovoid foci of high signals located at the anterior horns ((B) and (C)), consistent with an “owl’s eye” pattern. In its turn, sagittal T1WI ((D)) was unremarkable.

received
April 10, 2022
accepted
July 5, 2022

DOI <https://doi.org/10.1055/s-0042-1758392>.
ISSN 0004-282X.

© 2022. Academia Brasileira de Neurologia. All rights reserved. This is an open access article published by Thieme under the terms of the Creative Commons Attribution-NonDerivative-NonCommercial-License, permitting copying and reproduction so long as the original work is given appropriate credit. Contents may not be used for commercial purposes, or adapted, remixed, transformed or built upon. (<https://creativecommons.org/licenses/by-nc-nd/4.0/>)
Thieme Revinter Publicações Ltda., Rua do Matoso 170, Rio de Janeiro, RJ, CEP 20270-135, Brazil