



Since January 2020 Elsevier has created a COVID-19 resource centre with free information in English and Mandarin on the novel coronavirus COVID-19. The COVID-19 resource centre is hosted on Elsevier Connect, the company's public news and information website.

Elsevier hereby grants permission to make all its COVID-19-related research that is available on the COVID-19 resource centre - including this research content - immediately available in PubMed Central and other publicly funded repositories, such as the WHO COVID database with rights for unrestricted research re-use and analyses in any form or by any means with acknowledgement of the original source. These permissions are granted for free by Elsevier for as long as the COVID-19 resource centre remains active.



IMAGE IN CARDIOLOGY

Diagnosis of Takotsubo syndrome in the COVID-19 era

Diagnóstico da síndrome de Takotsubo na era da COVID-19



Kristian Rivera*, Diego Fernández-Rodríguez, Marta Zielonka, Juan Casanova-Sandoval

University Hospital Arnau de Vilanova, Institut de Recerca Biomèdica de Lleida (IRBLleida), Lleida, Spain

Received 12 August 2020; accepted 28 September 2020
 Available online 8 September 2021

A 94-year-old female, with hypertension, paroxysmal atrial fibrillation, ischemic stroke and an echocardiogram without wall motion abnormalities performed the previous month, presented to the emergency department with a two-day history of dyspnea and dry cough without fever. The patient had had contact with a COVID-19 patient, PCR was positive for SARS-CoV-2 and the chest radiography documented bilateral basal pneumonia. The baseline electrocardiogram showed sinus rhythm without significant repolarization alterations (Figure 1A). The patient was hospitalized for treatment.

On the fifth day of hospitalization, the patient reported chest pain and the electrocardiogram showed atrial fibrillation with rapid ventricular response and ST-segment elevation in the anterolateral leads (Figure 1B). Emergent coronary angiography demonstrated absence of obstructive coronary lesions (Figure 2A-C; Videos 1-3) and

ventriculography showed severe ventricular dysfunction with anterolateral, apical, and inferior dyskinesia and hypercontractility of the basal segments, compatible with Takotsubo syndrome (TTS) (Figure 2D and E; Video 4). At two-month follow-up, the patient remains asymptomatic and the echocardiogram demonstrated recovery of ventricular contractility.

The TTS consensus documents recommend coronary angiography and ventriculography to confirm the diagnosis. There are few reported cases of TTS triggered by COVID-19, with a non-negligible proportion diagnosed by echocardiography. The lack of invasive methods to confirm the diagnosis of TTS in COVID-19 patients could be related to the unavailability or the inherent risk of invasive tests. However, failure to perform coronary angiography and ventriculography can lead to false diagnoses. In this case, we show through

* Corresponding author.

E-mail address: psrivera.lleida.ics@gencat.cat (K. Rivera).

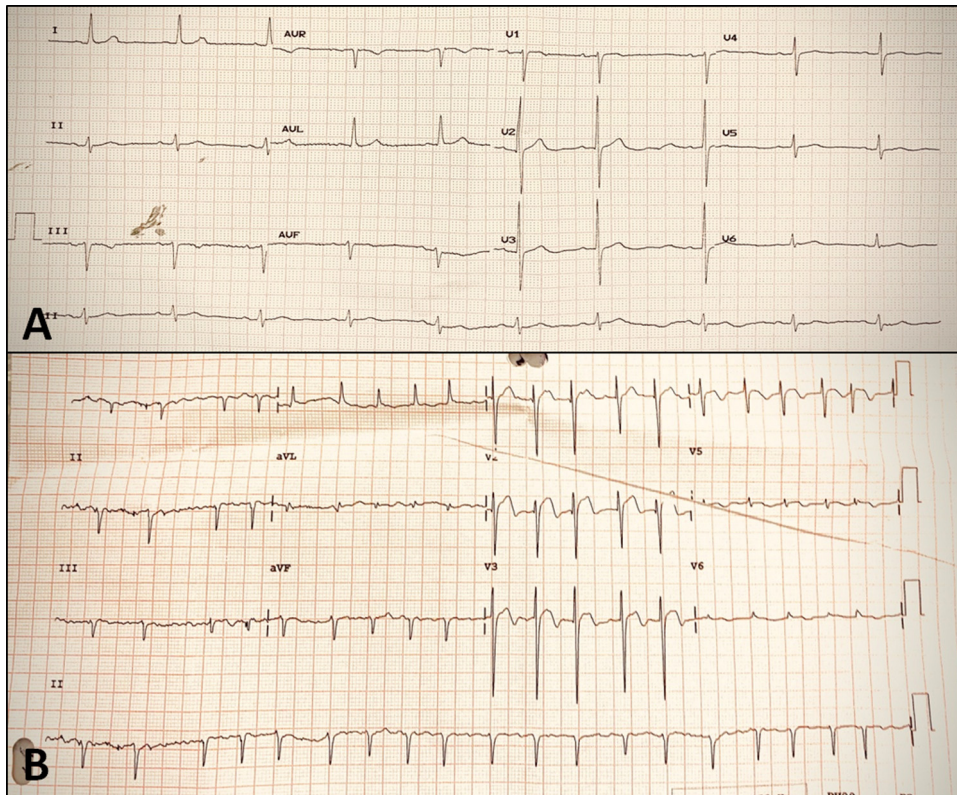

Figure 1 Baseline and follow-up electrocardiograms. (A) Baseline electrocardiogram with sinus rhythm and no ischemic or necrotic changes; (B) electrocardiogram during chest pain on the fifth day of hospitalization, showing atrial fibrillation and ST-segment elevation in leads V1-V4.

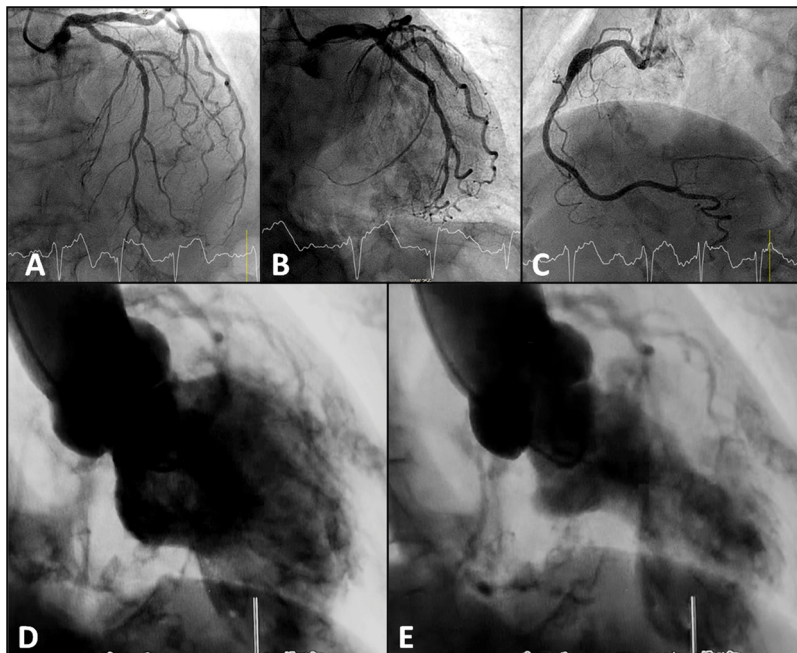


Figure 2 Cardiac catheterization during primary percutaneous coronary intervention. (A-C) Coronary angiography with non-obstructive coronary artery disease; (D-E) ventriculography showing wall motion abnormalities in apical segments of the anterolateral and inferior walls, compatible with Takotsubo wall motion abnormality pattern.

invasive methods, following the recommended criteria, the development of TTS in a patient with COVID-19.

Conflicts of interest

The authors have no conflicts of interest to declare.

Appendix A. Supplementary material

Supplementary material associated with this article can be found in the online version at [doi:10.1016/j.repc.2020.09.016](https://doi.org/10.1016/j.repc.2020.09.016).