

# Range of Hip Joint Motion Is Correlated With MRI-Verified Cam Deformity in Adolescent Elite Skiers

Cecilia Agnvall,\* PT, Anna Swärd Aminoff,<sup>†‡</sup> MD, Carl Todd,<sup>§</sup> MSc, DO, Pall Jonasson,<sup>†</sup> MD, PhD, Olof Thoreson,<sup>†</sup> MD, PhD, Leif Swärd,<sup>†</sup> MD, PhD, Jon Karlsson,<sup>†</sup> MD, PhD, and Adad Baranto,<sup>†</sup> MD, PhD

*Investigation performed at Åre Ski Academy, Åre, Sweden, and Östersunds Hospital, Östersund, Sweden*

**Background:** Radiologically verified cam-type femoroacetabular impingement (FAI) has been shown to correlate with reduced internal rotation, reduced passive hip flexion, and a positive anterior impingement test.

**Purpose:** To validate how a clinical examination of the hip joint correlates with magnetic resonance imaging (MRI)-verified cam deformity in adolescents.

**Study Design:** Cross-sectional study; Level of evidence, 3.

**Methods:** The sample group consisted of 102 adolescents with the mean age  $17.7 \pm 1.4$  years. The hip joints were examined using MRI for measurements of the presence of cam ( $\alpha$ -angle  $\geq 55^\circ$ ) and clinically for range of motion (ROM) in both supine and sitting positions. The participants were divided into a cam and a noncam group based on the results of the MRI examination. Passive hip flexion, internal rotation, anterior impingement, and the FABER (flexion, abduction, and external rotation) test were used to test both hips in the supine position. With the participant sitting, the internal/external rotation of the hip joint was measured in 3 different positions of the pelvis (neutral, maximum anteversion, and retroversion) and lumbar spine (neutral, maximum extension, and flexion).

**Results:** Differences were found between the cam and noncam groups in terms of the anterior impingement test (right,  $P = .010$ ; left,  $P = .006$ ), passive supine hip flexion (right: mean,  $5^\circ$ ; cam,  $117^\circ$ ; noncam,  $122^\circ$  [ $P = .05$ ]; and left: mean,  $8.5^\circ$ ; cam,  $116^\circ$ ; noncam,  $124.5^\circ$  [ $P = .001$ ]), supine internal rotation (right: mean,  $4.9^\circ$ ; cam,  $24^\circ$ ; noncam,  $29^\circ$  [ $P = .022$ ]; and left: mean,  $4.8^\circ$ ; cam,  $26^\circ$ ; noncam,  $31^\circ$  [ $P = .028$ ]), sitting internal rotation with the pelvis and lumbar spine in neutral (right: mean,  $7.95^\circ$ ; cam,  $29^\circ$ ; noncam,  $37^\circ$  [ $P = .001$ ]; and left: mean,  $6.5^\circ$ ; cam,  $31.5^\circ$ ; noncam,  $38^\circ$  [ $P = .006$ ]), maximum anteversion of the pelvis and extension of the lumbar spine (right: mean,  $5.2^\circ$ ; cam,  $20^\circ$ ; noncam,  $25^\circ$  [ $P = .004$ ]; and left: mean,  $5.85^\circ$ ; cam,  $20.5^\circ$ ; noncam,  $26.4^\circ$  [ $P = .004$ ]), and maximum retroversion of the pelvis and flexion of the spine (right: mean,  $8.4^\circ$ ; cam,  $32.5^\circ$ ; noncam,  $41^\circ$  [ $P = .001$ ]; and left: mean,  $6.2^\circ$ ; cam,  $36^\circ$ ; noncam,  $42.3^\circ$  [ $P = .012$ ]). The cam group had reduced ROM compared with the noncam group in all clinical ROM measures.

**Conclusion:** The presence of cam deformity on MRI correlates with reduced internal rotation in the supine and sitting positions, passive supine hip flexion, and the impingement test in adolescents.

**Keywords:** cam-type FAI; skiers; range of motion; hip joint

Femoroacetabular impingement (FAI) is caused by an abnormal morphology of the hips and can be divided into 2 categories: cam (femoral based) and pincer (acetabular based).<sup>5,13,16,24</sup> These 2 pathologies may occur alone or together.<sup>5</sup>

The mechanism of cam-type impingement is a collision between the abnormally formed femoral neck/head (cam) and the acetabular margin during flexion and internal

rotation of the hip joint.<sup>16</sup> This type of collision may lead to cartilage damage, primarily to the anterosuperior area of the acetabulum, and less frequently to labral damage.<sup>5,9,13,16,21</sup> Cam impingement is regarded by some researchers as a cause of early hip joint osteoarthritis (OA), while pincer impingement is not believed to cause hip OA but rather labral damage.<sup>1-3,18,29,33</sup>

FAI can be diagnosed by a history of hip symptoms and by a combination of clinical examinations and confirmatory radiology, on plain radiographs or magnetic resonance imaging (MRI).<sup>20,35</sup> Symptoms that have been associated with FAI syndrome are motion-related or position-related pain

The Orthopaedic Journal of Sports Medicine, 5(6), 2325967117711890

DOI: 10.1177/2325967117711890

© The Author(s) 2017

This open-access article is published and distributed under the Creative Commons Attribution - NonCommercial - No Derivatives License (<http://creativecommons.org/licenses/by-nc-nd/3.0/>), which permits the noncommercial use, distribution, and reproduction of the article in any medium, provided the original author and source are credited. You may not alter, transform, or build upon this article without the permission of the Author(s). For reprints and permission queries, please visit SAGE's website at <http://www.sagepub.com/journalsPermissions.nav>.

TABLE 1  
Baseline Characteristics for All Participants Stratified by Group<sup>a</sup>

	All Participants (N =102) <sup>b</sup>	Cam (n = 36)	Noncam (n = 53)	P Value
Age, y	17.7 (1.4)	18.0 (1.2)	17.4 (1.3)	.021
Female sex, n [%]	53 [52]	10 [28]	36 [68]	<.001
Height, cm	173 (8.3)	177 (7.6)	171 (7.5)	<.001
Weight, kg	69 (12.2)	71 (9.9)	68 (13.8)	.143
Body mass index, kg/m <sup>2</sup>	22.9 (3.3)	22.7 (2.5)	23.1 (3.9)	.556

<sup>a</sup>Values are presented as mean (SD) unless indicated otherwise.

<sup>b</sup>Magnetic resonance imaging data from 13 participants and physical examination data from 15 participants were unavailable.

in the hip, groin, back, buttocks, or thigh. Clicking, catching, locking, stiffness, restricted range of motion (ROM), or giving way are other frequently reported symptoms.<sup>14</sup>

There are several studies that have evaluated the clinical examination findings in the hip in patients with FAI.<sup>10,13,32</sup> Radiologically verified cam impingement has previously been shown to be associated with reduced internal rotation of the hip in 90° of flexion, reduced passive hip flexion, and a positive anterior impingement test/FADIR (flexion, adduction, and internal rotation) test.<sup>10,13,32</sup> Reiman et al<sup>26</sup> concluded that only an anterior impingement test and supine flexion-internal rotation are valuable screening tests for FAI, and they suggested that more high-quality studies are needed to evaluate the validity of clinical tests. It may therefore be of importance to investigate and evaluate clinical tests that may help diagnose cam-type FAI and thereby minimize the need for radiological examinations.

To our knowledge, this is the first study to evaluate the relationship between an MRI-verified cam deformity and clinical ROM in a healthy population with no prior diagnosis of cam-type FAI. Furthermore, there are no prior studies that we are aware of that have examined internal and external rotation of the hip when the patient is sitting with the pelvis and spine in 3 different positions. The purpose of this study was to investigate and validate how ROM in a clinical examination correlates to MRI-verified cam deformity in young patients.

## METHODS

### Study Population

The sample group consisted of young athletic elite skiers from the Åre Ski Academy high school (n = 75) and a nonathletic population (n = 27) from 3 high schools in

Östersund and Järpen. All students attending the Åre Ski Academy (76 grade 1-4, professional, skiers aged between 16 and 20 years) were invited to participate in this prospective study. Seventy-five of the skiers, 35 females and 40 males, volunteered to participate.

The inclusion criterion for the nonathletic group was first-year high school students who had previously not participated and at present did not participate in any organized sports or physical activity for more than 2 hours per week. The exclusion criteria for both groups were individuals with previously diagnosed hip, spine, or pelvic disease or growth disturbance and previous surgery on the hips, spine, or pelvis.

The MRI examinations were performed at the Radiographic Department, Östersund Hospital, Östersund, and the clinical examination was carried out at the Åre Ski Academy and at the Orthopaedic Department, Östersund.

All the participants were informed about the study both orally and in writing. Participation was totally voluntary. Written consent was given by all individuals and, for participants younger than 18 years, written consent was obtained from their parents. The present study was approved by the Regional Ethical Review Board, Gothenburg.

A total of 53 females and 49 males volunteered to participate in the study. One skier had to withdraw due to diagnosed cam-type FAI that was treated with arthroscopic surgery before the examinations had been carried out. Two of the nonathletes were excluded because of previous high-level training in skiing and ice hockey. In addition, failure to attend investigations meant that only MRI data from 89 participants and physical examination data from 87 participants were available for the final analysis. The cam group consisted of 10 females and 26 males, whereas the noncam group consisted of 36 females and 17 males. Table 1 summarizes the demographic characteristics of the study population (N = 102).

†Address correspondence to Anna Swärd Aminoff, MD, Åre Hälsocentral, Box 25 830 14 Åre, Sweden (email: a.m.k.sward@gmail.com).

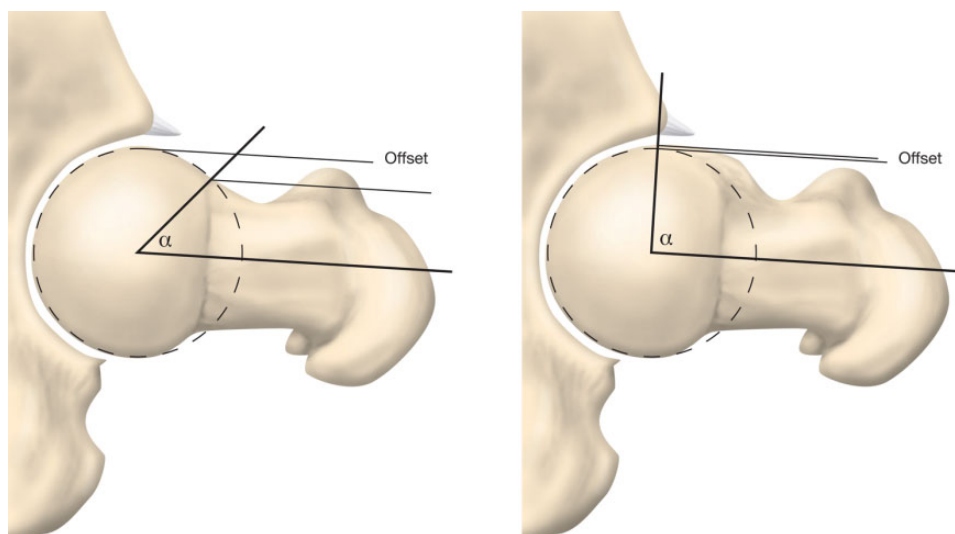
\*Sportsmedicine Åre and Åre Ski High School, Åre, Sweden.

†Department of Orthopaedics, Institute of Clinical Sciences at Sahlgrenska Academy, University of Gothenburg, and Sahlgrenska University Hospital, Gothenburg, Sweden.

§The Carl Todd Clinic, Corsham, United Kingdom.

One or more of the authors has declared the following potential conflict of interest or source of funding: This study was supported by research grants from the Medical Society of Gothenburg, Sweden; governmental grants under the ALF agreement; Handlanden Hjalmar Svenssons Research Foundation and Doktor Felix Neuberghs Foundation; Carl Bennett AB; Swedish National Centre for Research in Sports; and the Research and Development Unit, Jämtland Härjedalen County Council, Sweden.

Ethical approval for this study was obtained from Regionala etikprövningsnämnden i Göteborg.



**Figure 1.** Measurement of the  $\alpha$ -angle, between the femoral neck axis and a line from the center of the femoral head to a point where the contour of the femoral head-neck junction exceeds the radius of the femoral head.

### MRI Examination

All participants underwent MRI of both hips without contrast. The MRI that was used was a GE Optima 450 Wide 1.5 T, at Hospital Östersund. Coronal T2 fat-saturated and axial 3D Cube sequences were obtained angled on the femoral neck using a coil surface of HD 8-channel Cardiac Array by GE. The  $\alpha$ -angle was measured on the superior half of the femoral head. Seven measurements, from the 9 o'clock to 3 o'clock positions ( $180^\circ$ ), were performed to determine the morphological features of the femoral head-neck junction.<sup>16</sup> Measurement of the  $\alpha$ -angle was performed according to Nötzli et al.<sup>21</sup> The  $\alpha$ -angle was measured between the femoral neck axis and a line from the center of the femoral head to a point where the contour of the femoral head-neck junction exceeds the radius of the femoral head (Figure 1). The  $\alpha$ -angle is used to define the presence of a cam deformity, and in previous studies a threshold of  $55^\circ$  has been considered pathological.<sup>4,25,30,31</sup> In the present study, an  $\alpha$ -angle  $\geq 55^\circ$  was considered pathological. In the 89 study participants, 178 hips were analyzed. A total of 54 hips had cam changes, 26 hips on the right side and 28 on the left.

The MRI images were evaluated and measured by an experienced radiologist, together with a resident radiologist. All participants had been deidentified and given a random number, and the MRI examinations were mixed and evaluated randomly in a blinded manner. The images were evaluated according to a standardized protocol, including assessment of the  $\alpha$ -angle. To test the interobserver reliability, MRI images were selected randomly from 10 participants and were re-examined by another experienced radiologist. The result of the interobserver test, intraclass correlation coefficient (ICC) analysis for the  $\alpha$ -angle, epiphyseal extension, and diameter of the femoral head, indicated a good to excellent level of agreement ( $\alpha$ -angle ICC, 0.75; epiphyseal extension ICC, 0.92; diameter of caput femur ICC, 0.97).

### Clinical Examination

In the present study, the sitting position was selected, as it best replicates the sports specificity of skiing, but more importantly because it enabled us to investigate the relationship between the position of the pelvis and lumbar spine with the hip ROM.

A specially constructed chair was used to allow participants to sit with their legs hanging freely over the edge. With the use of 4 wooden bolsters, the chair fortified the isolation of movement in the hip by preventing any adduction or abduction of the femurs (Figure 2).

All examinations were performed by the coauthors (C.A. and A.S.A.) in a specific order to optimize the accuracy of the measurements. While one examiner examined a participant, the other examiner stabilized, read, and recorded the results. Both C.A. and A.S.A. performed the intraobserver tests. Four months passed between the first and second examination. Interobserver tests were performed comparing C.A. and A.S.A. The interobserver test was performed on the same day, and the examiners were blinded to each other's measurements. Both the intra- and interobserver tests included 10 of the skiers. The result of the intraobserver test (ICC analysis) for all physical examinations indicated good to very good agreement (passive hip flexion ICC, 0.77; supine internal rotation ICC, 0.78). The interobserver test (ICC) indicated a good to excellent level of agreement (passive hip flexion ICC, 0.83; supine internal rotation ICC, 0.94).

### Digital Goniometer Measurements

The goniometer has been used in previous studies of cam-type deformity in athletes.<sup>12,15,31</sup> In the present study, a digital goniometer was used (HALO Medical Devices), combined with a universal goniometer with prolonged arms to measure ROM.<sup>8,11,12,15</sup> A few times, when held



**Figure 2.** Sitting in a neutral position, both hips and knees at a 90° angle and the thighs held in position by 4 wooden bolsters to prevent hip abduction/adduction translation.

horizontally, the digital goniometer was shown to measure angles higher than the universal goniometer. The measurements of hip internal rotation in the supine position were therefore made using both the digital goniometer and a universal goniometer. When the angles differed, the angles measured by the universal goniometer were used because the universal goniometer is more widely used and acknowledged.

### Functional Tests


In this study, we defined the standing leg as the leg that felt most natural for the participant to stand on when performing a 1-leg activity. To identify the standing leg, the participant was asked to kick a football the way that felt the most natural (Figure 3). The participant was then asked to do a pirouette the way that felt the most natural and comfortable (Figure 4). If a participant used different legs in the 2 tests ( $n = 28$  of 89), we were not able to register the standing leg.

### Supine Examination

To standardize the supine examination, verbal instructions were given to the participant in the following order: bend



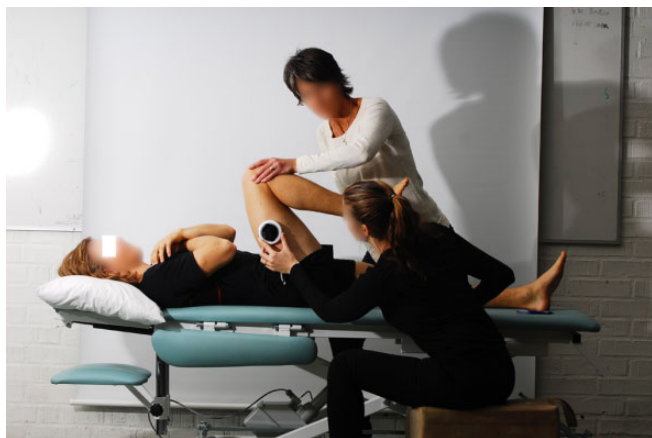**Figure 3.** Kicking a football the way that feels most natural.



**Figure 4.** Performing a pirouette the way that feels most natural and comfortable.

your knees, place your feet flat on the bed, raise your pelvis from the bed, lower your hips onto the bed, and then straighten your legs. This helped place the participant in a neutral, aligned position prior to the measurements.





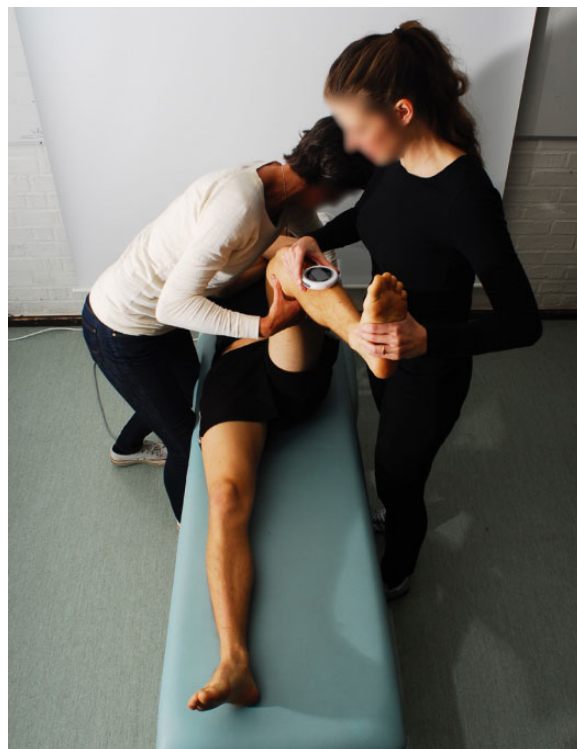
**Figure 5.** Passive hip joint flexion.

*Passive Hip Joint Flexion.* A reference line was drawn from the middle of the lateral femoral condyle and the greater trochanter by one examiner (Figure 5). The digital goniometer was initially calibrated and zeroed. It was then held in place by the same examiner, with its laser beams set along the previously marked line of reference. The other examiner flexed the hip and knee joints. The leg was raised in a sagittal plane, avoiding abduction or adduction of the hip. This examiner also maintained pressure on the contralateral thigh to limit pelvic rotation. Passive hip flexion was recorded in degrees. This process was then repeated for the opposite hip.

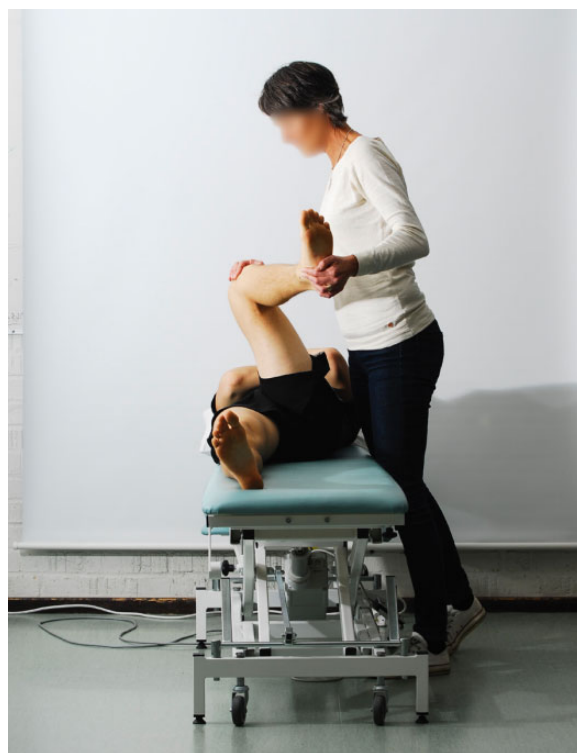*Passive Internal Rotation of the Hip.* Passive flexion in the sagittal plane was introduced to the hip and knee joint to  $90^\circ$  by one examiner. The other examiner marked a line of reference from the apex of the patella to midway between the lateral and medial malleolus (Figure 6). With the knee and hip held at  $90^\circ$  of flexion, the goniometer was calibrated, zeroed, and handheld with its laser beams set on the previously marked reference line. The hand of one examiner was placed around the participant's iliac crest to prevent any accessory lumbopelvic translation, while the other hand held the thigh manually in a vertical position. The other examiner held the leg in a horizontal position and internally rotated the hip until the point of initial resistance. The examiner who stabilized the pelvis also noted the first movement of the pelvis, which matched the endpoint of internal rotation felt by the other examiner. In this way, the accuracy of the measured internal rotation was double-checked by both examiners.

*Hip Anterior Impingement Test.* With the hip and knee flexed at  $90^\circ$  and maximally internally rotated (Figure 7), the examiner adducted the hip until resistance, according to Klaue et al.<sup>17</sup> The examiner held this position for a few seconds. This examination was graded with 3 possible options: no pain, discomfort, or pain.

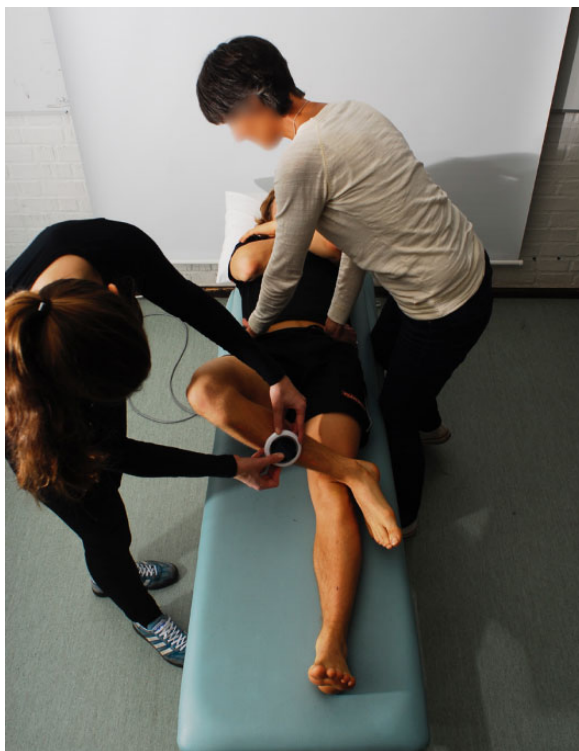*Patrick's or FABER (Flexion, Abduction, and External Rotation) Test.* This examination was performed as previously described by Ross et al.<sup>28</sup> and Byrd,<sup>7</sup> but it included the use of a digital goniometer for quantitative measurements.<sup>19</sup> The digital goniometer was calibrated and zeroed



**Figure 6.** Passive internal rotation of the hip.



**Figure 7.** Hip anterior impingement test.



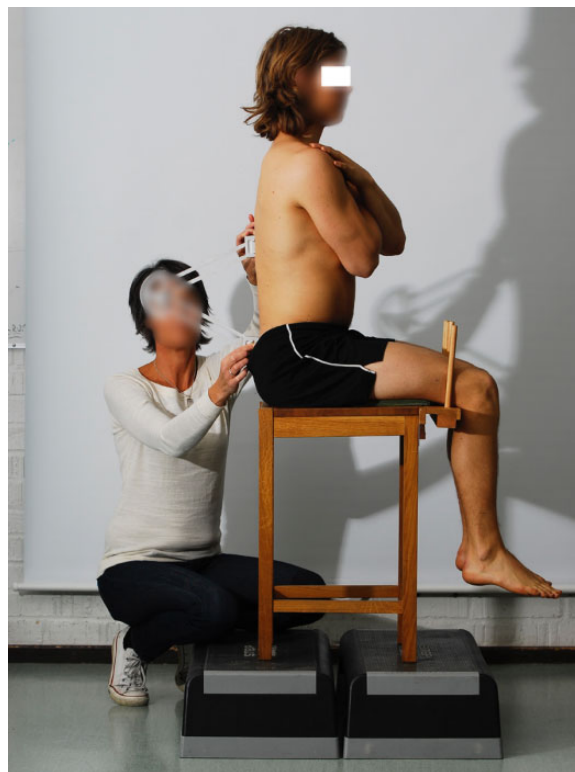
**Figure 8.** Patrick's or FABER (flexion, abduction, and external rotation) test.

and held in place by one examiner, with the laser beams set on the reference line previously marked along the tibia. One examiner stabilized the pelvis to prevent any accessory lumbo-pelvic rotation and to keep the pelvis in a neutral stabilized position. The other examiner raised one of the participant's legs and placed the participant's ankle superior and lateral to the contralateral knee (Figure 8). This motion created the hip joint flexion, abduction, and external rotation. The participant was instructed to relax and lower the tested leg, either to the point of pain or to the endpoint of motion. The angle was recorded in degrees. This process was then repeated for the opposite hip.

### Seated Examination

For these examinations, the participant was seated with both hips and knees placed at a 90° angle and the thighs held in position. Because of the anatomic differences in the thigh circumference distally, a 1-cm thick pad was placed under the distal femurs to ascertain that the femurs were in a horizontal position. To standardize the sitting position, participants were instructed to focus on a point straight ahead on the wall and have their arms folded across their chest, hands on opposite shoulders.

*Hip Joint Internal and External Rotation Range of Motion Testing.* Measurements of the internal and external rotations of the hip joints were performed using a digital goniometer, calibrated, zeroed, and handheld along the previously marked reference line along the tibia. The reference

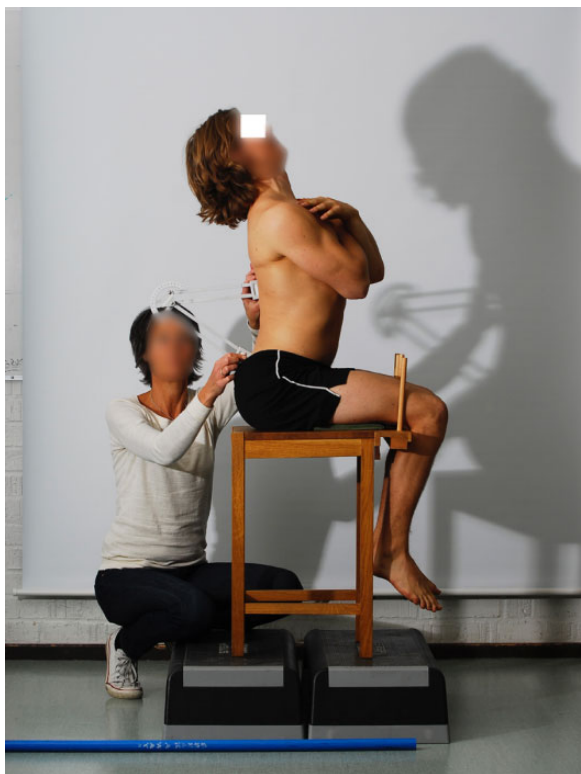

**Figure 9.** Neutral lumbar position in sitting.

line made it possible to set the goniometer laser beams during the measurement, to optimize the accuracy.

Internal and external rotations were measured in 3 different pelvic and lumbar spine positions as follows.

*Neutral Lumbar Position.* To measure the lumbar position when sitting in a neutral position, the participant was instructed to sit in a straight position, thus creating a vertical line from the participant's shoulder to the hip (Figure 9). Measurements of the 3 pelvic positions (neutral, maximum anteversion, and maximum retroversion) using the PALM palpation meter (Performance Attainment Associates) and the lumbar spinal sagittal positions (neutral, maximum extension, and maximum flexion) using the Debrunner Kyphometer (Protek AG).<sup>22,23</sup> were recorded, as described by Todd et al.<sup>34</sup> The angle of pelvic incline was measured on both sides and recorded. When measuring the internal and external rotation of the hips, the lumbar spine position was re-evaluated with the Kyphometer before changing sides, to ensure the same lumbar position when measuring both hips. One examiner stabilized the thigh and pelvis on the examined side, and passive internal rotation was then performed, to the point of initial resistance, by the other examiner. The examiner stabilizing the thigh and pelvis also observed the initial movement of the pelvis, which matched the endpoint of internal rotation palpated by the other examiner. In this way, the accuracy of the internal rotation was double-checked. The rotation was recorded in degrees. This process was repeated for the opposite hip, and the same procedure was then repeated for passive external rotation.



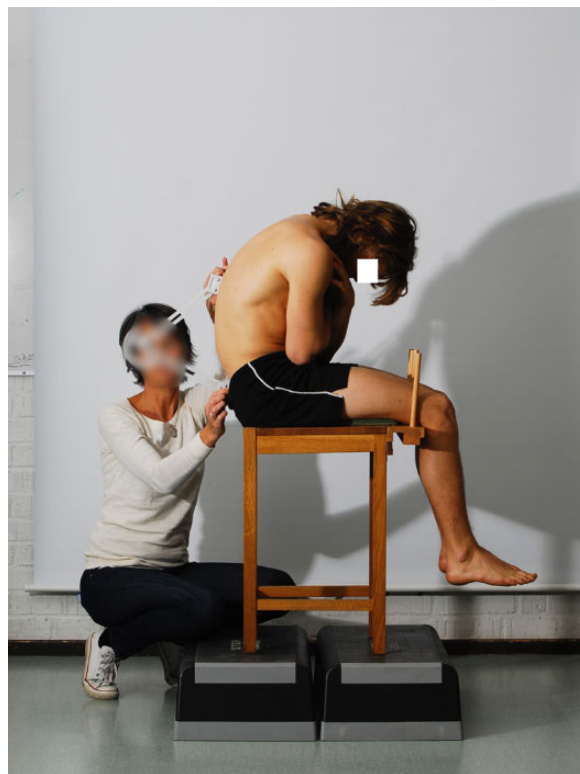
**Figure 10.** Lumbar spine in maximum extension.

*Lumbar Spine in Maximum Extension.* The participants were instructed to arch their lumbar spine and tilt their pelvis forward, thereby increasing the anteversion of the pelvis and lumbar lordosis (Figure 10). The lumbar spine position and the angle of pelvic anteversion were measured as previously described. In this position, passive internal and external rotations were measured in degrees; the participant was instructed to adopt the neutral position between each test for a short rest, and the lumbar spine position was remeasured before measuring the other hip.

*Lumbar Spine in Maximum Flexion (SLUMP Position).* The participant was instructed to flex his or her lumbar spine and tilt his or her pelvis backward to the endpoint, essentially increasing the retroversion of the pelvis and lumbar kyphosis (Figure 11). The lumbar spine position and the angle of pelvic retroversion were measured as previously described. In this position, passive internal and external rotations were measured in degrees; the participant was instructed to adopt the neutral position between each test for a short rest, and the SLUMP position was remeasured before measuring the other hip.

### Statistical Analysis

The data were analyzed using IBM SPSS Statistics for Windows, version 22.0 (IBM Corp). The description of data was expressed in terms of the mean and standard deviation. An independent *t* test and Pearson chi-square test



**Figure 11.** Lumbar spine in maximum flexion (SLUMP position).

were performed to compare variables (cam vs noncam). A chi-square test for association was conducted between pain/discomfort of the anterior impingement test and cam/noncam. All tests were 2-sided and significance was set at  $P < .05$  for each test. An ICC analysis was made for the intra- and interobserver tests.

### RESULTS

Participants in the cam and noncam groups were similar in terms of body mass index (cam, 22.7 [SD, 2.5] and noncam 23.1 [SD, 3.9]), but a significant age difference was found between groups. The mean age for the enrolled population was 17.7 (SD, 1.4) years: cam group 18.0 years (SD, 1.2) and the noncam group 17.4 years (SD, 1.3) ( $P = .02$ ) (Table 1).

The values for and distribution of clinical and radiological measurements are presented in Tables 2 and 3. The mean values for comparison of the clinical examination between the cam and noncam groups are presented for the right leg in Table 2 and for the left leg in Table 3.

For both the right and the left legs, there was a significantly reduced ROM in the cam group compared with the noncam group for the anterior impingement test, passive supine hip flexion, supine internal rotation, and sitting internal rotation with the pelvis and lumbar spine in all 3 different positions.

TABLE 2  
Range of Motion Versus MRI Cam Findings: Right Hip<sup>a</sup>

Test	Cam (n = 26)	Noncam (n = 63)	Difference	95% CI		P Value <sup>b</sup>
				Lower	Upper	
Supine hip flexion	116.89 (10.45)	121.92 (11.33)	5.03	-0.008	10.08	<b>.050</b>
Supine, internal rotation	24.15 (7.91)	29.03 (9.36)	4.88	0.71	9.05	<b>.022</b>
Supine, FABER test	66.77 (6.68)	68.18 (9.27)	1.41	-2.59	5.41	.485
Sitting neutral, internal rotation	29.00 (9.56)	36.95 (9.71)	7.95	3.45	12.45	<b>.001</b>
Sitting neutral, external rotation	36.04 (8.17)	37.93 (8.48)	1.90	-2.01	5.80	.337
Sitting extension, internal rotation	20.27 (7.43)	25.45 (7.38)	5.18	1.73	8.63	<b>.004</b>
Sitting extension, external rotation	29.31 (7.38)	32.13 (8.24)	2.83	-0.91	6.56	.136
Sitting flexion, internal rotation	32.46 (11.05)	40.90 (9.82)	8.44	3.69	13.19	<b>.001</b>
Sitting flexion, external rotation	34.73 (7.54)	37.61 (7.91)	2.88	-0.76	6.51	.119

<sup>a</sup>Values are presented in degrees as mean (SD). FABER, flexion, abduction, and external rotation; MRI, magnetic resonance imaging.

<sup>b</sup>P values in boldface indicate statistical significance.

TABLE 3  
Range of Motion Versus MRI CAM Findings: Left Hip<sup>a</sup>

Test	Cam (n = 28)	Noncam (n = 61)	Difference	95% CI		P Value <sup>b</sup>
				Lower	Upper	
Supine hip flexion	116.00 (9.19)	124.47 (9.19)	8.47	4.24	12.69	<b>.001</b>
Supine, internal rotation	25.78 (8.50)	30.60 (9.62)	4.82	0.54	9.10	<b>.028</b>
Supine, FABER test	62.30 (6.48)	65.3 (11.07)	2.97	-1.59	7.53	.199
Sitting neutral, internal rotation	31.56 (8.64)	38.02 (10.34)	6.46	1.92	11.00	<b>.006</b>
Sitting neutral, external rotation	35.93 (6.89)	36.02 (6.93)	0.09	-3.10	3.28	.955
Sitting extension, internal rotation	20.56 (6.44)	26.41 (9.16)	5.85	1.96	9.74	<b>.004</b>
Sitting extension, external rotation	29.56 (7.93)	29.56 (7.20)	0.004	-3.43	3.44	.998
Sitting flexion, internal rotation	36.07 (10.31)	42.32 (10.53)	6.24	1.42	11.06	<b>.012</b>
Sitting flexion, external rotation	35.30 (6.06)	36.17 (6.69)	0.87	-2.13	3.87	.565

<sup>a</sup>Values are presented in degrees as mean (SD). FABER, flexion, abduction, and external rotation; MRI, magnetic resonance imaging.

<sup>b</sup>P values in boldface indicate statistical significance.

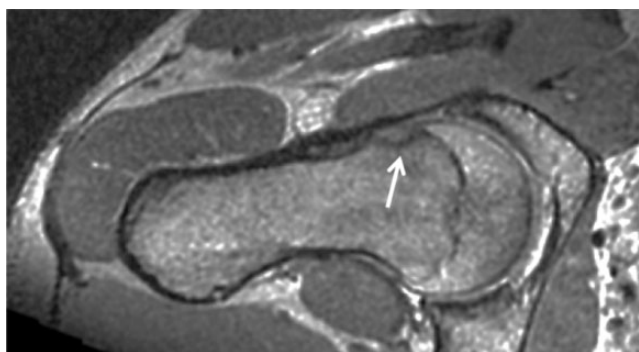


Figure 12. Magnetic resonance image of the right hip of a 20-year-old female alpine skier with a cam lesion (arrow).

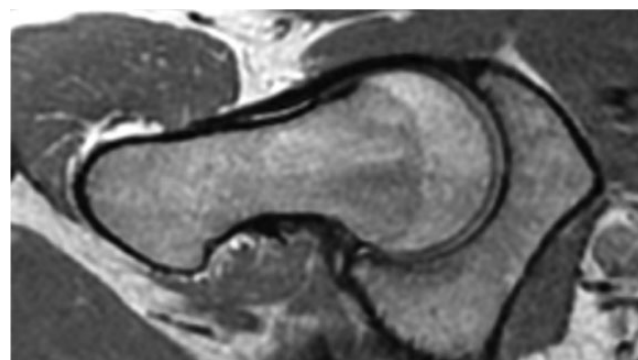


Figure 13. Magnetic resonance image of the right hip of a 19-year-old female control without any cam lesion.

### Magnetic Resonance Imaging

The cam group consisted of those with an  $\alpha$ -angle of  $\geq 55^\circ$  (Figure 12), while the noncam group's  $\alpha$ -angle was  $< 55^\circ$  (Figure 13). Eighteen percent had bilateral cam. There were 26 hips (29%) with cam on the right side and 28 hips (31%) with cam on the left side, leading to a total of 54 hips

(30%) with cam-type morphology. At an individual level, 40% of the 89 participants who underwent MRI had cam (22% of the females, 61% of the males).

### Clinical Examination

The correlation between an MRI-verified cam and a specific clinical examination is presented below.



## Supine Examinations

*Standing Leg.* No significant association was found between the standing leg and MRI-verified cam.

*Passive Hip Joint Flexion.* There was a significant difference between the MRI-verified cam and noncam groups for supine hip flexion, with a mean difference of 5° ( $P = .05$ ) for the right hip and 8.5° ( $P = .001$ ) for the left hip.

*Passive Internal Rotation of the Hip.* Supine internal rotation was also significant, with a mean difference of 4.9° ( $P = .02$ ) on the right leg and 4.8° ( $P = .03$ ) on the left leg.

*Anterior Impingement Test.* There was a significant association between pain/discomfort in the anterior impingement test and cam:  $\chi^2(1) = 6.628$  ( $P = .01$ ) for the right hip and  $\chi^2(1) = 7.675$  ( $P = .006$ ) for the left hip.

*FABER Test.* No significant differences were found for FABER test.

## Seated Examination

*Internal Rotation.* There was a significant association between all 3 examinations of internal rotation and cam. When the participant was sitting with the pelvis and lumbar spine in a neutral position, there was a mean difference between the cam and noncam groups of 8° ( $P = .001$ ) for the right hip and 6.5° ( $P = .006$ ) for the left hip, respectively. Internal rotation when sitting with the pelvis maximally anteverted and the lumbar spine maximally extended showed a mean between-group difference of 5.2° ( $P = .004$ ) for the right hip and 5.8° ( $P = .004$ ) the left hip, and internal rotation with the pelvis maximally retroverted and the lumbar spine in a SLUMP position (maximally flexed) showed a between-group mean difference of 8.4° ( $P = .001$ ) for the right hip and 6.2° ( $P = .012$ ) for the left hip.

*External Rotation.* No significant differences were found between the cam and noncam groups in terms of external rotation when sitting.

## DISCUSSION

The main findings in the present study show that reduced hip joint internal rotation in the supine and sitting positions, with the pelvis and lumbar spine in all 3 positions, is associated with MRI-verified cam deformity. No significant differences were shown between the validity of the 3 different lumbar and pelvic positions and for the diagnosis of hip joint cam-type FAI.

Moreover, passive supine hip flexion and the anterior impingement test were shown to be associated with MRI-verified cam. This correlates well with what previous studies have shown: that reduced internal rotation in 90° of hip flexion, reduced passive flexion of the hip, and a positive anterior impingement test are associated with radiologically verified FAI.<sup>10,13,32</sup> Clohisy et al<sup>10</sup> found a mean 97° of hip flexion and 9° of internal rotation among participants with symptomatic FAI and 101° of hip flexion and 12° of internal rotation among those with asymptomatic FAI. The tendency in the present study appears similar to that of Clohisy et al,<sup>10</sup> but the mean values for both flexion and

internal rotation are higher. However, the groups in these studies are not entirely comparable, as the participants in the present study were from a healthy population sample without diagnosed FAI. Sink et al<sup>32</sup> found that 100% of the participants with FAI had a positive impingement test, and Clohisy et al<sup>10</sup> found that 88% of the symptomatic FAI hips had a positive impingement test. This correlates well with the present study, where 82% of the participants with cam on the left hip had a positive impingement test and 85% on the right. Moreover, the findings in the current study also suggest that the degree of internal hip rotation is associated with the position of the pelvis (neutral, anteversion, or retroversion) and the lumbar spine (neutral, extension, or flexion). By testing the internal and external rotation in sitting, it was possible to control and minimize any increased movement in the lumbar spine, pelvis, and hip joints, making the results more reliable. In the position with maximum pelvic anteversion and lumbar spine extension, the rotation of the hip joint was shown to be decreased. With pelvic retroversion and lumbar spine flexion, hip joint rotation was shown to be increased. This correlates with a study by Ross et al<sup>27</sup> that was able to show, with 3-dimensional models, that dynamic changes in pelvic tilt significantly influence hip joint ROM. The clinical findings in the present study support the findings of Ross et al.<sup>27</sup>

Although the present study was able to show a statistically significant difference between the 2 groups analyzed, these results must be interpreted with caution, as the mean differences between the cam group and noncam group appear to be small. Moreover, these results emphasize that for the diagnosis of FAI impingement, a combination of symptoms, positive clinical tests, and imaging findings should all be used.<sup>14</sup> The cohort that was examined in the present study were all healthy adolescents, and this may therefore differ from a study involving a symptomatic population with hip/groin problems or patients waiting for FAI surgery. One reason for the modest difference in ROM between the cam and noncam groups could be the relatively late fusion of the separate centers of ossification that form the bones of the pelvis. Partial fusion of the iliac crest can occur from 15 to 22 years of age, with complete union in all individuals by the age of 23 years.<sup>6</sup> The ischial epiphysis appears between 13 and 16 years of age, begins to fuse at the superior rim of the epiphyseal surface, and continues to develop into the ramal epiphysis, which will continue to fuse toward the pubic body with complete union by 20 and 21 years of age.<sup>6</sup> It is therefore tempting to speculate that the acetabulum permits slight movement before fusion, making it harder clinically to diagnose a cam-type lesion of the hip. It would be interesting to examine the same cohort after their pelvic physes have fused and study whether the difference in the clinical examination between the cam and noncam groups is greater compared with the findings in the present study.

## Limitations

There are some limitations to the present study. A larger sample group might have revealed a greater difference between the cam and noncam groups. The inclusion criteria

in the present study selected only a healthy population, but this may have limited the ability to identify greater differences in ROM in the presence of cam compared with a symptomatic group. Other limitations include the accuracy and interpretation of the radiological measurements. Physical examination is always dependent on the examiner, and we attempted to limit the variation in results by limiting the examiners to only 2. Finally, it was difficult to recruit young nonathletes, especially males. An equally large number of nonathletes, with equal sex distribution, would have been desirable.

## Clinical Relevance

The clinical relevance of this study is based on the results of an evaluation of a range of clinical tests for diagnosing hip joint cam impingement, facilitating the diagnosis of the condition, and passing the right patients through to radiology. The statistically significant findings highlight that the reduction in internal hip joint rotation is associated with the position of the pelvis (neutral, anteversion, or retroversion) and that the position of the lumbar spine (neutral, extension, or flexion) is relevant when examining a patient with hip symptoms. A greater awareness of the lumbar spine and pelvic positions while examining hip joint ROM clinically may prevent the clinician from misinterpreting results.

## CONCLUSION

The presence of a cam deformity on MRI correlates with reduced internal rotation of the hip in both the supine and sitting positions, passive supine hip flexion, and the anterior impingement test.

## ACKNOWLEDGMENT

The authors thank Flemming Pedersen, MD, and Zaid Obady, MD, at the Department of Radiology at Östersunds Hospital, Sweden, for their help with the radiological examination and Christer Johansson, OrigoVerus AB, Gothenburg, Sweden, for statistical assistance. The authors also thank Åke Hamberg, MD, at the Department of Orthopaedics at Östersund Hospital, Sweden, for helping with the recruitment of young nonathletes.

## REFERENCES

1. Agricola R, Heijboer MP, Bierma-Zeinstra SM, Verhaar JA, Weinans H, Waarsing JH. Cam impingement causes osteoarthritis of the hip: a nationwide prospective cohort study (CHECK). *Ann Rheum Dis*. 2013;72:918-923.
2. Agricola R, Heijboer MP, Roze RH, et al. Pincer deformity does not lead to osteoarthritis of the hip whereas acetabular dysplasia does: acetabular coverage and development of osteoarthritis in a nationwide prospective cohort study (CHECK). *Osteoarthritis Cartilage*. 2013;21:1514-1521.
3. Agricola R, Waarsing JH, Arden NK, et al. Cam impingement of the hip: a risk factor for hip osteoarthritis. *Nat Rev Rheumatol*. 2013;9:630-634.
4. Agricola R, Waarsing JH, Thomas GE, et al. Cam impingement: defining the presence of a cam deformity by the alpha angle: data from the CHECK cohort and Chingford cohort. *Osteoarthritis Cartilage*. 2014;22:218-225.
5. Beck M, Kalhor M, Leunig M, Ganz R. Hip morphology influences the pattern of damage to the acetabular cartilage: femoroacetabular impingement as a cause of early osteoarthritis of the hip. *J Bone Joint Surg Br*. 2005;87:1012-1018.
6. Berge C. Heterochronic processes in human evolution: an ontogenetic analysis of the hominid pelvis. *Am J Phys Anthropol*. 1998;105:441-459.
7. Byrd JW. Evaluation of the hip: history and physical examination. *N Am J Sports Phys Ther*. 2007;2:231-240.
8. Carey MA, Laird DE, Murray KA, Stevenson JR. Reliability, validity, and clinical usability of a digital goniometer. *Work*. 2010;36:55-66.
9. Clohisy JC, Baca G, Beaulé PE, et al; for ANCHOR Study Group. Descriptive epidemiology of femoroacetabular impingement: a North American cohort of patients undergoing surgery. *Am J Sports Med*. 2013;41:1348-1356.
10. Clohisy JC, Knaus ER, Hunt DM, Leshner JM, Harris-Hayes M, Prather H. Clinical presentation of patients with symptomatic anterior hip impingement. *Clin Orthop Relat Res*. 2009;467:638-644.
11. Furness J, Johnstone S, Hing W, Abbott A, Climstein M. Assessment of shoulder active range of motion in prone versus supine: a reliability and concurrent validity study. *Physiother Theory Pract*. 2015;31:489-495.
12. Gajdosik RL, Bohannon RW. Clinical measurement of range of motion. Review of goniometry emphasizing reliability and validity. *Phys Ther*. 1987;67:1867-1872.
13. Ganz R, Parvizi J, Beck M, Leunig M, Nötzli H, Siebenrock KA. Femoroacetabular impingement: a cause for osteoarthritis of the hip. *Clin Orthop Relat Res*. 2003;417:112-120.
14. Griffin DR, Dickenson EJ, O'Donnell J, et al. The Warwick Agreement on femoroacetabular impingement syndrome (FAI syndrome): an international consensus statement. *Br J Sports Med*. 2016;50:1169-1176.
15. Holm I, Bolstad B, Lütken T, Ervik A, Røkkum M, Steen H. Reliability of goniometric measurements and visual estimates of hip ROM in patients with osteoarthritis. *Physiother Res Int*. 2000;5:241-248.
16. Ito K, Minka MA 2nd, Leunig M, Werlen S, Ganz R. Femoroacetabular impingement and the cam-effect. A MRI-based quantitative anatomical study of the femoral head-neck offset. *J Bone Joint Surg Br*. 2001;83:171-176.
17. Klaue K, Durnin CW, Ganz R. The acetabular rim syndrome. A clinical presentation of dysplasia of the hip. *J Bone Joint Surg Br*. 1991;73:423-429.
18. Leunig M, Casillas MM, Hamlet M, et al. Slipped capital femoral epiphysis: early mechanical damage to the acetabular cartilage by a prominent femoral metaphysis. *Acta Orthop Scand*. 2000;71:370-375.
19. Martin HD, Kelly BT, Leunig M, et al. The pattern and technique in the clinical evaluation of the adult hip: the common physical examination tests of hip specialists. *Arthroscopy*. 2010;26:161-172.
20. Martin HD, Shears SA, Palmer IJ. Evaluation of the hip. *Sports Med Arthrosc*. 2010;18:63-75.
21. Nötzli HP, Wyss TF, Stoecklin CH, Schmid MR, Treiber K, Hodler J. The contour of the femoral head-neck junction as a predictor for the risk of anterior impingement. *J Bone Joint Surg Br*. 2002;84:556-560.
22. Ohlen G, Aaro S, Bylund P. The sagittal configuration and mobility of the spine in idiopathic scoliosis. *Spine (Phila Pa 1976)*. 1988;13:413-416.
23. Ohlen G, Spangfort E, Tingvall C. Measurement of spinal sagittal configuration and mobility with Debrunner's kyphometer. *Spine (Phila Pa 1976)*. 1989;14:580-583.
24. Pfirrmann CW, Mengiardi B, Dora C, Kalberer F, Zanetti M, Hodler J. Cam and pincer femoroacetabular impingement: characteristic MR arthrographic findings in 50 patients. *Radiology*. 2006;240:778-785.
25. Philippon MJ, Ho CP, Briggs KK, Stull J, LaPrade RF. Prevalence of increased alpha angles as a measure of cam-type femoroacetabular

- impingement in youth ice hockey players. *Am J Sports Med.* 2013;41:1357-1362.
26. Reiman MP, Goode AP, Cook CE, Hölmich P, Thorborg K. Diagnostic accuracy of clinical tests for the diagnosis of hip femoroacetabular impingement/labral tear: a systematic review with meta-analysis. *Br J Sports Med.* 2015;49:811.
27. Ross JR, Nepple JJ, Philippon MJ, Kelly BT, Larson CM, Bedi A. Effect of changes in pelvic tilt on range of motion to impingement and radiographic parameters of acetabular morphologic characteristics. *Am J Sports Med.* 2014;42:2402-2409.
28. Ross MD, Nordeen MH, Barido M. Test-retest reliability of Patrick's hip range of motion test in healthy college-aged men. *J Strength Cond Res.* 2003;17:156-161.
29. Sankar WN, Nevitt M, Parvizi J, Felson DT, Agricola R, Leunig M. Femoroacetabular impingement: defining the condition and its role in the pathophysiology of osteoarthritis. *J Am Acad Orthop Surg.* 2013;21(suppl 1):S7-S15.
30. Siebenrock KA, Ferner F, Noble PC, Santore RF, Werlen S, Mamisch TC. The cam-type deformity of the proximal femur arises in childhood in response to vigorous sporting activity. *Clin Orthop Relat Res.* 2011;469:3229-3240.
31. Siebenrock KA, Kaschka I, Frauchiger L, Werlen S, Schwab JM. Prevalence of cam-type deformity and hip pain in elite ice hockey players before and after the end of growth. *Am J Sports Med.* 2013;41:2308-2313.
32. Sink EL, Gralla J, Ryba A, Dayton M. Clinical presentation of femoroacetabular impingement in adolescents. *J Pediatr Orthop.* 2008;28:806-811.
33. Thomas GE, Palmer AJ, Batra RN, et al. Subclinical deformities of the hip are significant predictors of radiographic osteoarthritis and joint replacement in women. A 20 year longitudinal cohort study. *Osteoarthritis Cartilage.* 2014;22:1504-1510.
34. Todd C, Swärd A, Agnvall C, Swärd L, Karlsson J, Baranto A. Clinical spino-pelvic parameters in skiers and non-athletes. *J J Sport Med.* 2016;3(3):022.
35. Yuan BJ, Bartelt RB, Levy BA, Bond JR, Trousdale RT, Sierra RJ. Decreased range of motion is associated with structural hip deformity in asymptomatic adolescent athletes. *Am J Sports Med.* 2013;41:1519-1525.