

Original Paper

A Novel Intraoperative Laser Light Imaging System to Simultaneously Visualize Visible Light and Near-Infrared Fluorescence for Indocyanine Green Videoangiography

Taku Sato^{a, b} Mudathir Bakhit^a Kyouichi Suzuki^c Jun Sakuma^a
Masazumi Fujii^a Yuta Murakami^a Yuhei Ito^a Ulrich Sure^b
Kiyoshi Saito^a

^aDepartment of Neurosurgery, Fukushima Medical University, Fukushima, Japan;

^bDepartment of Neurosurgery, University Hospital Essen, Essen, Germany; ^cDepartment of Neurosurgery, Fukushima Red Cross Hospital, Fukushima, Japan

Keywords

Laser light · Indocyanine green videoangiography · Dual-image videoangiography

Abstract

Background: Intraoperative indocyanine green videoangiography (ICG-VA) has been reported to be utilized in various cerebrovascular surgeries, wherein the blood flow is noticeably shown in white with a black background. ICG flow alone, but not other structures, can be observed using ICG-VA. We developed a novel high-resolution intraoperative imaging system using laser light source for simultaneously visualizing both visible light and near-infrared (NIR) fluorescence images of ICG-VA. **Methods:** We used a novel system for 14 cerebrovascular cases. The operative field was illuminated via an operating microscope using a novel laser light source with four bands at 464 (blue), 532 (green), 640 (red), and 785 nm (NIR region). The observed light from the operative field was split using a beam splitter cube into visible (420–660 nm) and NIR fluorescence emission light (832–900 nm). Images from the color video and NIR fluorescence emission windows were merged for visualization on a monitor screen simultaneously. Laser light was compared with xenon light, and both setups were tested for cerebrovascular surgeries. **Results:** Laser light has numerous advantages over xenon light. The present setup clearly visualized the color operative field with enhanced blood flow. Complete clipping or incomplete clipping with neck remnant or remnant flow into an aneurysm was confirmed in aneurysm surgeries. Feeding arteries and draining veins were easily distinguished in case of arteriovenous malformation. **Conclusions:** Using the present setup, we can observe the color operative field and enhanced blood flow using ICG in real time. This setup could facilitate various cerebrovascular surgeries.

© 2018 The Author(s)

Published by S. Karger AG, Basel

Taku Sato, MD, PhD
Department of Neurosurgery, Fukushima Medical University
1 Hikarigaoka
Fukushima-shi, Fukushima 960-1295 (Japan)
E-Mail tak-s@fmu.ac.jp

Introduction

The usefulness of indocyanine green videoangiography (ICG-VA) has been reported in various cerebrovascular surgeries [1, 2]. Vessels are visibly demonstrated in white with a black background; however, other structures, such as occluded vessels, brain structures, and clips cannot be observed during ICG-VA.

We developed a high-resolution intraoperative imaging system (dual-image VA [DIVA]) for simultaneously visualizing both light and near-infrared (NIR) fluorescence images from ICG-VA [3]. The system enables the simultaneous observation of the operative field and enhanced blood flow by ICG [3, 4]. We also developed a novel laser light source for surgical microscopes [5]. The effectiveness of DIVA integrated with laser light was evaluated.

Methods

We developed a novel laser light source (MML-01; Mizuho Co. Ltd., Tokyo, Japan) for surgical microscopes. The operative field was illuminated via an operating microscope using four bands at 464 (blue), 532 (green), 640 (red), and 785 nm (NIR region). The novel laser light has several advantages over conventional sources, such as the lack of harmful ultraviolet waves, longer lifespan, lower focal temperature, a wide range of brightness and color production, and improved safety for the user's vision. It was integrated using a surgical microscope (Leica OH6; Leica Microsystems GmbH, Wetzlar, Germany) with DIVA, allowing the simultaneous visualization of both light and NIR fluorescence images from ICG-VA. ICG was injected via a peripheral vein. The DIVA (MNIRC-200K; Mizuho Co. Ltd., Tokyo, Japan) was split by beam splitter cube into visible (420–660 nm) and NIR fluorescence emission light (832–900 nm), and images of the color video window and NIR fluorescence emission window were merged for visualization on a monitor screen simultaneously.

The novel system was used in 14 cerebrovascular cases between October 2014 and March 2017, and the effectiveness of DIVA integrated with laser light was evaluated.

Results

Compared with xenon light, the laser light was bright, precise, and efficient in the observation of the deep part of the brain parenchyma, particularly at high magnification. All 14 cases showed a clearly visualized operative field, including both fluorescence-enhanced blood vessels and other structures. We confirmed complete clipping and preserved blood flow in the parent and perforating arteries in patients with aneurysm. Feeding vessels, passing arteries, and draining veins were visualized and detected in arteriovenous malformation surgery.

Surgeons can switch between a white-light binocular view to a simultaneous right monocular DIVA image and a left monocular white-light image. Thus, performing surgery while simultaneously observing both the light and DIVA-processed images was possible.

Illustrative Case

A 74-year-old woman with an anterior communicating artery aneurysm, which was incidentally found after evaluating dizziness, was referred to our hospital (Fig. 1). Aneurysm clipping via bifrontal craniotomy was performed under the monitoring of motor-evoked

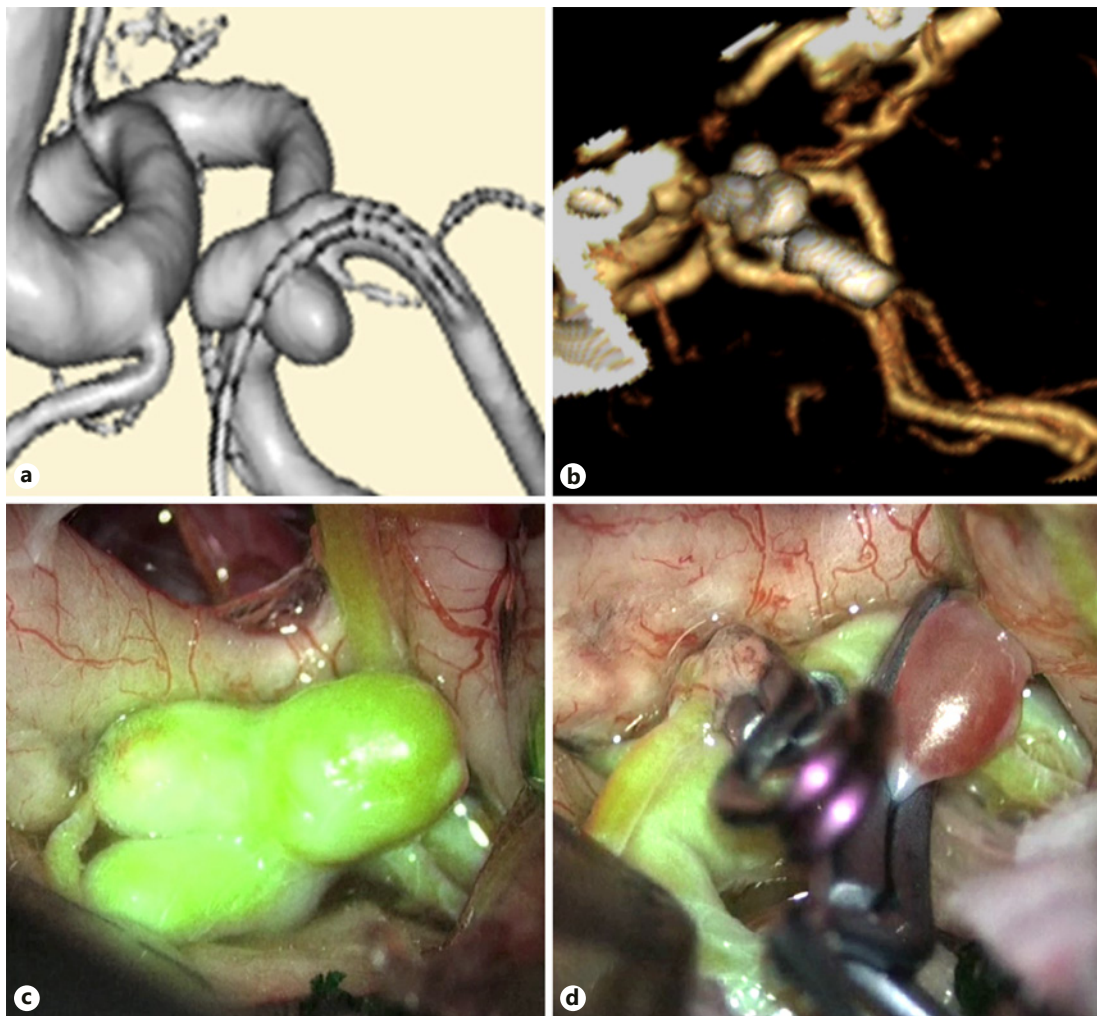


Fig. 1. **a** Preoperative magnetic resonance angiography showing an anterior communicating artery aneurysm. **b** Postoperative three-dimensional computed tomography angiography showing no aneurysm remnant after clipping. **c** Dual-image videoangiography showing the anatomical relationship between the anterior cerebral artery, median artery of the corpus callosum, and recurrent artery of Heubner with the surrounding brain structures. **d** Dual-image videoangiography noticeably revealed the preservation of blood flow in the anterior cerebral artery and obliteration of the aneurysm with surrounding brain structures and clip positions.

potentials. Two clips were applied to the aneurysm neck. After clipping, the DIVA clearly revealed blood flow preservation in the anterior cerebral artery, median artery of the corpus callosum, recurrent artery of Heubner, obliteration of the aneurysm with the surrounding brain structures, and clip positions. The postoperative course was uneventful.

Discussion

Fluorescence angiography using ICG or fluorescein has been widely applied for visualizing blood flow in cerebrovascular surgeries [6–10]. We developed a high-resolution intraoperative imaging system for simultaneously visualizing both light and NIR fluorescence images from ICG-VA and a novel laser light source for surgical microscopes.

In the present study, laser light could be superbly utilized for observation under the microscope because it had a wider range of color coordinates and brightness compared with xenon light. The DIVA integrated with laser light enabled us to better visualize visual and fluorescence images compared with xenon light because of the high absorption intensity of the NIR spectrum [5].

Xenon light is the most frequently used light source in neurosurgical microscopes. However, it increases the focal temperature of the tissues, causing focal thermal injury. We compared the temperature between the laser light and xenon light sources [5]. The focal temperature on the surface illuminated by laser light had a significantly lower temperature than that illuminated by xenon light. This was primarily attributed to the lack of the high-energy wavelengths of ultraviolet rays and possibly to the ability to illuminate the surgical field with a lower level of illuminance than required for xenon light. Further examinations are necessary for the evaluation of the effectiveness of this novel light source in clinical cases.

The safety of laser light is essential in clinical cases. The laser light source has directivity, and coherence poses a risk to the human body. A novel laser light source diffuser panel that reduces the coherence to safe levels for surgeons' eyes and patients' neural tissues was developed for avoiding such light coherence. The photochemical and heat influence based on a Monte Carlo modeling was simulated, and safety was theoretically proven [5].

Conclusion

We developed a novel high-resolution intraoperative imaging system using laser light source for the simultaneous visualization of both visible light and NIR fluorescence images of ICG-VA. Using this setup, we can observe the color operative field and enhanced blood flow by ICG in real time. For establishing the effectiveness of this setup, we will accumulate data from several cerebrovascular surgeries.

Statement of Ethics

The clinical trial protocol was reviewed and approved by a local independent ethics committee of Fukushima Medical University (No. 1479). Written informed consent was obtained from all patients or their legal representatives before enrollment in the study.

Disclosure Statement

All authors declare no conflicts of interest.

Funding Sources

This study was supported by grants for the Development of Medical & Welfare Devices in Fukushima Prefecture (24-829).

Author Contributions

Conceptualization: T. Sato, K. Suzuki, J. Sakuma, K. Saito. Drafting of the work: T. Sato, M. Fujii, Y. Murakami, Y. Ito. Final approval of the version: T. Sato, M. Bakhit, U. Sure, K. Saito. Agreement: T. Sato, M. Bakhit, K. Suzuki, J. Sakuma, M. Fujii, Y. Murakami, Y. Ito, U. Sure, K. Saito.

References

- 1 Raabe A, Nakaji P, Beck J, Kim LJ, Hsu FP, Kamerman JD, Seifert V, Spetzler RF: Prospective evaluation of surgical microscope-integrated intraoperative near-infrared indocyanine green videoangiography during aneurysm surgery. *J Neurosurg* 2005;103:982–989.
- 2 Roessler K, Krawagna M, Dorfler A, Buchfelder M, Ganslandt O: Essentials in intraoperative indocyanine green videoangiography assessment for intracranial aneurysm surgery: conclusions from 295 consecutively clipped aneurysms and review of the literature. *Neurosurg Focus* 2014;36:E7.
- 3 Sato T, Suzuki K, Sakuma J, Takatsu N, Kojima Y, Sugano T, Saito K: Development of a new high-resolution intraoperative imaging system (dual-image videoangiography, DIVA) to simultaneously visualize light and near-infrared fluorescence images of indocyanine green angiography. *Acta Neurochir (Wien)* 2015;157:1295–1301.
- 4 Feletti A, Wang X, Tanaka R, Yamada Y, Suyama D, Kawase T, Sano H, Kato Y: Dual-image videoangiography during intracranial microvascular surgery. *World Neurosurg* 2017;99:572–579.
- 5 Sato T, Bakhit MS, Suzuki K, Sakuma J, Fujii M, Murakami Y, Ito Y, Sugano T, Saito K: Utility and safety of a novel surgical microscope laser light source. *PLoS One* 2018;13:e0192112.
- 6 Ichikawa T, Suzuki K, Watanabe Y: Intra-arterial fluorescence angiography with injection of fluorescein sodium from the superficial temporal artery during aneurysm surgery: technical notes. *Neurol Med Chir (Tokyo)* 2014;54:490–496.
- 7 Ichikawa T, Suzuki K, Watanabe Y, Sato T, Sakuma J, Saito K: Development of and clinical experience with a simple device for performing intraoperative fluorescein fluorescence cerebral angiography: technical notes. *Neurol Med Chir (Tokyo)* 2016;56:141–149.
- 8 Sasaki T, Kodama N, Matsumoto M, Suzuki K, Konno Y, Sakuma J, Endo Y, Oinuma M: Blood flow disturbance in perforating arteries attributable to aneurysm surgery. *J Neurosurg* 2007;107:60–67.
- 9 Suzuki K, Kodama N, Sasaki T, Matsumoto M, Ichikawa T, Munakata R, Muramatsu H, Kasuya H: Confirmation of blood flow in perforating arteries using fluorescein cerebral angiography during aneurysm surgery. *J Neurosurg* 2007;107:68–73.
- 10 Ito Y, Suzuki K, Ichikawa T, Watanabe Y, Sato T, Sakuma J, Saito K: Intraoperative fluorescence cerebral angiography by laser surgical microscopy: comparison with xenon microscopy and simultaneous observation of cerebral blood flow and surrounding structures. *Oper Neurosurg (Hagerstown)*, Epub ahead of print.