



Original Article

Safety and efficacy of epicardial approach to catheter ablation of ventricular tachycardia – An institutional experience



Jayapandian Pandian, Daljeet Kaur, Sachin Yalagudri, Soumen Devidutta, Gomathi Sundar, Sridevi Chennapragada, Calambur Narasimhan*

CARE Hospital, Road No.1, Banjara Hills, Hyderabad 500 034, India

ARTICLE INFO

Article history:

Received 28 March 2016

Accepted 24 October 2016

Available online 5 November 2016

Keywords:

Epicardial ventricular tachycardia
Epicardial ventricular tachycardia ablation
Non-ischaemic cardiomyopathy
Ischaemic cardiomyopathy

ABSTRACT

Background and aim: Epicardial approach to VT ablation increases the success rate of ablation but is not without complications. We studied the safety and efficacy of epicardial VT ablations performed at our institute.

Methods: All patients who underwent epicardial VT ablation at our institute were studied retrospectively. The outcome of VT ablation was among three groups: ischaemic cardiomyopathy (ICM), non-ischaemic cardiomyopathy (NICM) and granulomatous myocarditis (GM). Safety outcomes assessed included all complications considered to be due to pericardial access or epicardial mapping/ablation.

Results: A total of 54 patients (total 119 VTs, mean 2.2 (0.9)) were taken up for ablation procedure through epicardial access. Mean age: 47 (10) years, males: 83%. All patients had drug resistant recurrent VTs. The epicardial procedure was abandoned in three patients due to access issues; percutaneous sub-xiphoid access was employed in 48 and surgical approach in four patients. Complete success was achieved in 59% and partial success in 76%. The outcomes were poor in ICM patients as compared to those with GM and NICM. Overall success rates for all clinical VTs were 89% in GM, 90% in NICM and 67% in ICM. Success rates for epicardial VT ablation were 94%, 85% and 78% respectively for GM, NICM and ICM. Procedure related complications occurred in six patients.

Conclusion: Epicardial ablation for VT offers good immediate outcomes with acceptable safety profile.

© 2016 Published by Elsevier B.V. on behalf of Cardiological Society of India. This is an open access article under the CC BY-NC-ND license (<http://creativecommons.org/licenses/by-nc-nd/4.0/>).

1. Introduction

Ablation of ventricular tachycardia (VT) is associated with variable success rates. Despite advancements in technology and improved understanding of arrhythmia mechanisms, acute and long-term success rates of endocardial ablation remains modest.^{1–3} An important reason cited for the failure is the presence of the re-entry circuits deep within the endocardium or on the epicardium.

Epicardial location of VT is observed in about 70% of patients with Chaga's disease.⁴ Presence of epicardial substrates, its density and distribution is increasingly being recognized in other forms of scar-related cardiomyopathies^{4–13} too. In patients undergoing endocardial ablation of VT, about 15–30% of failures are being attributed to the epicardial location of re-entry circuits.¹⁴ Failure

rates vary with different etiologies ranging from 50 to 80%.^{6,11,12,15–17} With high prevalence of epicardial location of re-entry circuits and high rate of recurrence of VT after endocardial ablations, the epicardial approach in tackling these conditions is increasingly being recognized.

Epicardial approach to VT ablation is being performed routinely in some institutions with variations in patient selection, approach and strategies related to mapping and ablation.^{5,7,8,10,18,19} We studied the acute safety and efficacy of epicardial VT ablations done at our Institute.

2. Materials and methods

This is a retrospective study of all patients who underwent epicardial access for ablation of VT at our Institution from August 2008 till November 2015. It includes both first line (direct epicardial) and second-line approach. In the second line approach, mapping was performed initially using the endocardial approach. Based on the mapping information we decided to access the

* Corresponding author at: Arrhythmia and Electrophysiology Services, CARE Hospital, Road No.1, Banjara Hills, Hyderabad 500 034, India.
E-mail address: Calambur@hotmail.com (C. Narasimhan).

epicardium. Direct epicardial approach was performed when ECG recording during an episode of VT revealed features of epicardial origin or scar confined to the epicardium was observed on cardiac magnetic resonance (CMR) imaging. Procedure was performed after obtaining informed consent from all patients. Beta-blockers were stopped five half-lives and amiodarone three weeks before an elective procedure. Mexiletine was stopped three days prior to the procedure.

All procedures were performed under local anaesthesia and conscious sedation.²⁰ General anaesthesia was mainly reserved for patients who underwent surgical access to the pericardium. Sedation was initiated with intravenous bolus of midazolam hydrochloride (1 mg). The doses were repeated depending on the level of consciousness of the patients. In addition, intravenous fentanyl citrate 20 mcg was used followed by 2–3 mcg/min of infusion for short-term analgesia.

2.1. Mapping, induction and ablation procedure

All procedures were done under intravenous anticoagulation using intravenous heparin with initial bolus of 50–100 IU/kg followed by a 1000 IU/h perfusion. The maintenance dose was titrated to maintain the activated clotting time above 250/300 s.

Vascular access was obtained via right femoral vein and artery. Quadripolar catheters were positioned in the region of His bundle, right ventricle and right atrium through femoral venous access. Mapping and ablation was performed with 3.5 mm open irrigated tip ThermoCool, Navistar, catheter (Biosense Webster, Diamond Bar, California). Three dimensional electroanatomic mapping was done with CARTO (Biosense Webster, Diamond Bar, CA) or NavX system (St Jude Medical, Minneapolis, MN).

Ventricular tachycardia induction was performed with programmed electrical stimulation (PES) with up to two basic drive cycle length (CL) of 600 and 400 milliseconds (ms) and 1–3 extra stimuli from right ventricular apex and outflow tract. If VT was not induced at baseline, isoprenaline was infused for facilitation.

Unstable VTs were mapped during sinus rhythm and substrate mapping. Channels and entry and exit sites were further defined by pace mapping. Bipolar pace-mapping was performed at 10 mA and a pulse width 2 ms. During activation mapping, mid-diastolic or pre-systolic potentials were sought, entrainment was performed and critical isthmus of the VT re-entrant circuit defined. Radiofrequency (RF) energy was delivered at sites where there was concealed entrainment with stimulus to QRS (S-QRS) nearly equal to electrogram to QRS duration and post pacing interval nearly identical to tachycardia cycle length (TCL). If the tachycardia could not be entrained, the earliest local ventricular electrograms were targeted. During substrate mapping, areas of low voltage, isolated late potentials and fractionated potentials were tagged. Following this, stimuli were given to the tagged area and S-QRS duration was measured to identify the critical isthmus.

During the procedure, where suggestion of epicardial substrates surfaced, anticoagulation was reversed with intravenous protamine sulphate and epicardial access was attempted.

2.2. Pericardial access

Percutaneous epicardial access was obtained through the sub-xiphoid approach using an epidural needle as described previously. In patients where the percutaneous access failed, the surgical approach to create a sub-xiphoid window or limited lateral thoracotomy under general anaesthesia was performed the following day. The site of surgical access was chosen according to the area of interest in the epicardium.

2.3. Safety measures during epicardial ablation

A coronary angiogram was performed after mapping if ablation was planned on the left ventricular epicardial wall to ensure the absence of coronary artery at the site of target. Ablation was avoided at sites close to a major coronary artery. Injury to the left phrenic nerve was avoided using the technique as described by Fan et al.²¹ In short, a high output pacing (>10 mA) along the left lateral wall was given to assess phrenic nerve capture during energy delivery. In case of phrenic nerve capture, manoeuvres to separate the epicardium from the parietal pericardium were attempted. The ablation of the target site was avoided if the manoeuvres failed.

After performing ablations for targeted VTs, programmed stimulation was repeated as pre-ablation. Re-ablations were attempted for any inducible VTs. In case of repeated inducibility, the procedure was terminated after 2–3 attempts of ablation. Post procedure, beta blockers were continued for life and amiodarone was given on low dose following which it was tapered and stopped if there was no VT recurrence.

2.4. Acute procedural outcomes: definition of terms

Complete success: The total elimination of all inducible VT at the end of the procedure.

Partial success: The elimination of all inducible clinical VTs but the persistence of non-clinical VT (s).

Failure: The inability to render clinical VT non inducible at the end of the procedure.

2.5. Procedural complications

Any complication that happened during hospital stay and deemed to be due to pericardial access or ablation procedure were considered procedural complications.

2.6. Post-procedural patient care

Following the procedure, excess fluid within the pericardium was drained and a pig tail catheter was left within the pericardium after administering intra-pericardial methylprednisolone. A trans-thoracic echocardiogram was performed three hours and 24 h following the procedure. The pericardial drain was removed after 24 h if the collection was ≤ 50 ml. The clinical course of all patients until discharge was traced and recorded.

2.7. Statistical analysis

Continuous variables are represented as mean and standard deviation where data follows normal distribution, otherwise as median with range. Data was analyzed using STATA 13.

3. Results

Between August 2008 till December 2015, a total of 54 patients (total 119 VTs, mean 2.2 (0.9)) were taken up for ablation procedure through epicardial access. The mean age was 47 (10) years with 45 (83%) males. Table 1 gives baseline demographics and clinical profile of all patients.

3.1. Indications for radiofrequency ablation

Twenty-eight patients (52%) had implantable cardioverter defibrillator (ICD). Recurrent, appropriate shocks were the indication of RFA in all these patients. Eighteen patients had either VT storm or incessant VT and the remaining eight patients had recurrent haemodynamically unstable VT.

Table 1
Baseline demographics and clinical profile of patients.

Variables	Number (%) or mean (SD)
Hypertension	23 (43%)
Diabetes mellitus	15 (28%)
Previous cardiac surgery	3 ^a
Mean LVEF	40% (10)
Severe LV dysfunction ^b	6 (11%)
Renal dysfunction ^c	5 (9%)
Underlying aetiology	
Granulomatous myocarditis ^d	19 (35%)
Ischaemic cardiomyopathy	17 (32%)
Non-ischaemic cardiomyopathy + others ^e	18 (33%)

^a Coronary artery bypass grafting in two patients and valvular surgery in one patient.

^b Left ventricular ejection fraction $\leq 30\%$.

^c Includes patients with Serum Creatinine ≥ 1.5 mg/dl.

^d Includes patients with sarcoidosis, tuberculosis and tubercular sarcoidosis.

^e Others include Arrhythmogenic right ventricular cardiomyopathy (2 patients) and hypertrophic cardiomyopathy (2 patients).

LVEF, left ventricular ejection fraction.

3.2. Access

Pericardial access: Pericardial access was achieved in 48 patients through percutaneous approach and in four patients through surgical approach. Pericardial access was abandoned in two patients due to significant bleeding during sub-xiphoid puncture (Fig. 1).

Access to epicardium: Pericardial adhesions precluded access to the epicardial targets in three patients who had undergone previous cardiac surgery. In two patients, we were successfully able to access the epicardium by performing manual separation of the adhesions with the mapping catheter. In one patient, the catheter based separation of adhesions was unsuccessful. Surgical access was considered high risk in this patient as it required

Table 2
Characteristics of the induced ventricular tachycardias.

Variables		Number (%) or mean (SD)
QRS axis	Right axis deviation	65 (55%)
	Left axis deviation	29 (24%)
	Extreme right axis	25 (21%)
VT morphology	Right bundle block morphology	76 (64%)
	Left bundle block morphology	43 (36%)
Total no. of VTs		119
Clinical VTs	Clinical VT	84 (71%)
Epicardial VT	Epicardial VT	79 (66%)

VT, ventricular tachycardia.

sternotomy and cardiopulmonary bypass. Hence, the procedure was abandoned.

The results given below are of 51 patients, excluding the four in which epicardial procedure was abandoned.

3.3. Mapping

We performed substrate mapping in 15 patients (29%), pace mapping in 12 patients and activation mapping in one. In the remaining 23 patients, a combination of strategies was used. All procedures were performed under three-dimensional electroanatomic guidance mapping (CARTO in 49 and NavX in 1). The characteristics of the induced VTs are given in Table 2.

3.4. Ablation and outcomes

Overall, in 51 patients, 113 VTs were induced of which 74% were ablated successfully. Eighty of 113 VTs (71%) were clinical VTs. Ventricular tachycardias from epicardial substrate constituted 65% of the total VTs. Complete success was achieved in 30 patients

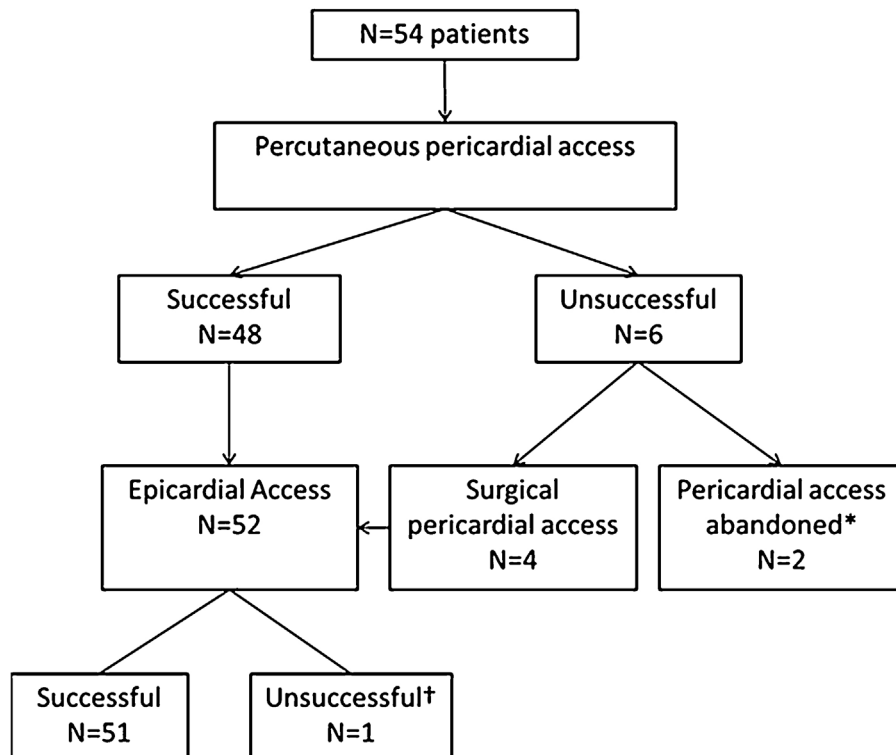


Fig. 1. Flow diagram of patients undergoing pericardial and epicardial access. Legend: * Pericardial access abandoned due to severe bleeding; † Extensive adhesions precluded epicardial access.

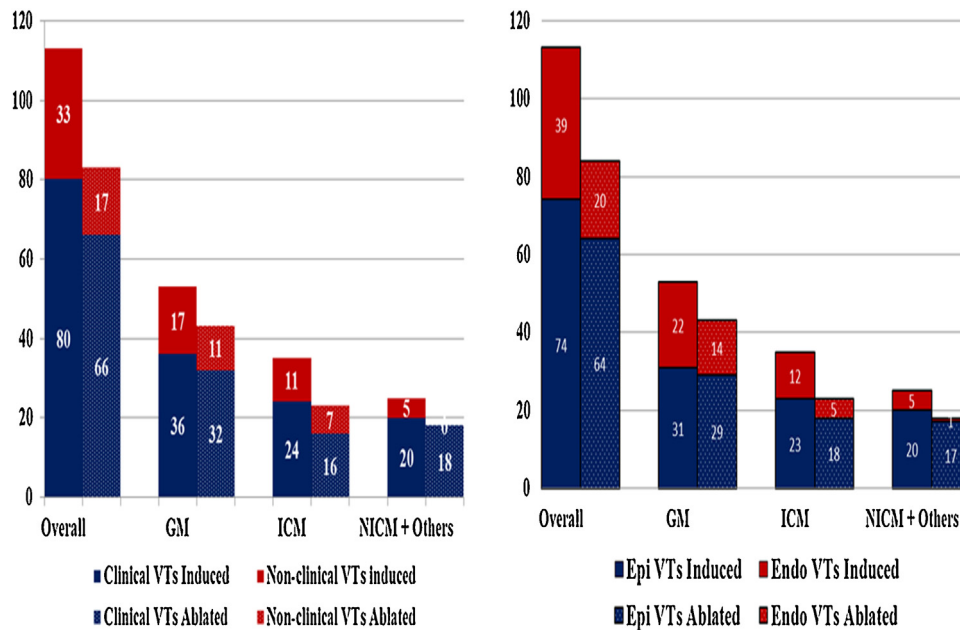


Fig. 2. Proportion of VTs ablated in all patients and in different categorized etiologies compared to the number of VTs induced. Legend: Y Axis in panel A shows the proportion of clinical and non-clinical VTs ablated to the total no. of VTs induced and panel B shows the proportion of epicardial VTs and endocardial VTs ablated to the total no. of VTs induced. GM, granulomatous myocarditis; NICM, non-ischaemic cardiomyopathy; ICM, ischaemic cardiomyopathy; Epi, epicardial; Endo, endocardial.

(59%) and partial success in 39 patients (76%). Eighty six percent of the VTs from epicardial substrates were ablated. Reasons for failure to ablated VTs from epicardial substrate include: repeated inducibility (4 VTs), phrenic nerve capture (3 VTs), adhesions at target site (2 VTs), and target site proximal to coronary artery (1 VT). There was no recurrence of VT in any patient until discharge from hospital. Fig. 2 shows clinical VTs and epicardial VTs ablated in proportion to the number of VT induced.

3.5. Support and special manoeuvres

Seven patients required endotracheal intubation and mechanical ventilation in which five were elective: for surgical epicardial access in four patients and for creating deliberate transient apnoea in one patient who had phrenic nerve capture. Mechanical ventilation was required in one patient for completion of the procedure in whom haemodynamically unstable VT was induced.

For the epicardial targets, in one of the patients who had a surgical approach, we did a cryoablation as this patient had to be ablated in close proximity to the crux region.

Phrenic nerve capture was observed in five patients. As mentioned above, we used mechanical ventilation to induce transient apnoea for ablation in one. By preventing respiratory movements, apnoea transiently displaces the phrenic nerve from the epicardium during which time the ablation was performed. In another patient, we introduced the Tyshak balloon catheter and positioned it in the epicardial site requiring ablation. The balloon was then inflated to create a space between the epicardium and the phrenic nerve during ablation. Ablation of the VT was avoided in three patients as the damage to phrenic nerve seemed inevitable.

3.6. Complications

Complications occurred in seven (12.9%) out of 54 patients. Six patients had pericardial effusion leading to tamponade in three. The tamponade was managed effectively in all three patients by use of pig tail catheter. There was one death in the post procedural period. This elderly patient had pre-existing renal dysfunction and had a prolonged procedure under general anaesthesia. Post

procedure, he developed hyperkalemia due to worsening renal dysfunction and died due to electromechanical dissociation.

4. Discussion

The results from our centre build on to the evidence on the favourable safety and efficacy profile of the epicardial ablation of VT. Successful ablation was possible in the majority of patients. The procedure served as a bail out for most patients as they presented with drug resistant VT.

The success of the epicardial ablation procedure depends on many factors such as feasibility of approach, complications and the underlying aetiology.

4.1. Feasibility

The feasibility of the procedure depends both on accessibility to the pericardial space and access to the ablation site. Access to the pericardial site by the percutaneous approach may be limited due to adhesions as seen in few of our patients. In such cases, the pericardial space could be approached with dissecting manoeuvres using an ablation catheter. Surgical approach also helps access to the pericardial space.

Critical structures like the presence of coronary artery or the phrenic nerve at the target site may also prevent ablation. While it is best to avoid ablations at targets near epicardial arteries, there are different manoeuvres described by various operators in dealing with substrates close to phrenic nerve. The techniques aim to creating a space between the epicardium and parietal pericardium to allow for ablations without injuring the phrenic nerve. We used deliberate transient apnoeic period by mechanical ventilation in one patient and Tyshak balloon inflation in one patient to avoid phrenic nerve injury. When injury to phrenic nerve appears inevitable, it is better to avoid ablation at the particular site. The decision to manoeuvre needs to be decided on case to case basis. The presence of epicardial fat over the target site may also interfere and reduce the effectiveness of ablation. However, we did not experience this limitation in our group of patients.

4.2. Complications

Acute, major complications include bleeding from epicardium due to damage caused during sub-xiphoidal puncture or epicardial ablation. The initial reported incidence of this complication was very high. Recent reports from experienced centres show a significant decline in this complication (3.5–9%).^{10,18,19,22} In our series, six of the seven complications that occurred were due to pericardial bleeding. In case of post procedural pericardial bleeding, tamponade can be avoided by leaving the pig tail catheter in situ as is done as a protocol in our centre. Owing to the risk of serious complications associated with the procedure, the current consensus guidelines⁴ advocate epicardial approach only after a failed endocardial ablation. However, institutional preferences vary in the approaches. We preferred the second line approach as endocardial VTs are present in many of patients concomitantly. When the need for an epicardial approach was felt during endocardial mapping, reversal of anticoagulation by intravenous protamine sulphate helped in epicardial puncture without any major bleeding complications in all but two patients in whom we abandoned epicardial access.

Damage to coronary artery, diaphragm or abdominal organs, severe pericarditis apart from injury to phrenic nerve are some of the other complications that have been reported.^{23,24} Though serious complications are a concern with epicardial ablation, proper precautions could help prevent them in majority of the cases. Coronary angiogram before ablation helps in avoiding injury to major coronary arteries as seen in a patient in our group.

4.3. Efficacy

Acute procedural success was comparable to the results from other centres. In our series of patients, we were able to ablate 74% of the VTs with complete success achievable in 59% of the patients. Complete elimination of all inducible VTs is difficult to achieve. Attempts should be made to ablate all inducible clinical VTs to provide symptomatic relief to the patients. We were successful in eliminating 76% of clinical VTs. As the indications for ablation in our patients were incessant VT/recurrent VT or VT storm in the majority, even partial success with the elimination of dominant clinical VTs resulted in substantial palliation of the VT burden in majority of our patients.

When analyzed according to the type of underlying aetiology, the procedure was most successful in patients with VT due to GM followed by those with NICM+ (81% and 72% respectively) compared to 66% in patients with ICM. The reasons for the differential outcomes is however not easily discernable. We assigned a separate category for patients with granulomatous myocarditis as they were in comparable numbers to the other groups. Septal intramural circuits/extensive right ventricular (RV) scars were the reason for failure to abolish all VTs in this group. Each aetiology may have different target locations, substrate morphologies with variability in behaviour. We feel that mapping and ablation strategies should be highly individualized based on the underlying substrate and the clinical condition of the patient.

4.4. Limitations

The major limitation of the study is that we assessed only the acute outcomes. Therefore, the efficacy of the procedure in preventing VT recurrences in long term is not known. Being a single-centre study and majority of the procedures largely performed by a single-operator prevents the generalizability of the study results.

5. Conclusion

Catheter ablation of VT can be performed safely via percutaneous epicardial approach for patients with epicardial circuits with good immediate outcome. The outcomes are better in patients with granulomatous myocarditis, which accounted for a third of our patient population. Proximity to a major coronary artery, pericardial adhesions and phrenic nerve stimulation precludes routine use of this approach.

Conflicts of interest

The authors have none to declare.

References

- Sacher F, Tedrow UB, Field ME, et al. Ventricular tachycardia ablation: evolution of patients and procedures over 8 years. *Circ Arrhythm Electrophysiol.* 2008;1(3):153–161. <http://dx.doi.org/10.1161/CIRCEP.108.769471>.
- Stevenson WG, Khan H, Sager P, et al. Identification of reentry circuit sites during catheter mapping and radiofrequency ablation of ventricular tachycardia late after myocardial infarction. *Circulation.* 1993;88(4 Pt 1):1647–1670. <http://www.ncbi.nlm.nih.gov/pubmed/8403311> Accessed 17.05.16
- Calkins H, Epstein A, Packer D, et al. Catheter ablation of ventricular tachycardia in patients with structural heart disease using cooled radiofrequency energy: results of a prospective multicenter study. Cooled RF Multi Center Investigators Group. *J Am Coll Cardiol.* 2000;35(7):1905–1914. [http://dx.doi.org/10.1016/S0735-1097\(00\)00615-X](http://dx.doi.org/10.1016/S0735-1097(00)00615-X).
- Sosa E, Scanavacca M, D'Avila A, et al. Endocardial and epicardial ablation guided by nonsurgical transthoracic epicardial mapping to treat recurrent ventricular tachycardia. *J Cardiovasc Electrophysiol.* 1998;9(3):229–239. <http://www.ncbi.nlm.nih.gov/pubmed/9580377> Accessed 17.05.16
- Schweikert RA, Saliba WJ, Tomassoni G, et al. Percutaneous pericardial instrumentation for endo-epicardial mapping of previously failed ablations. *Circulation.* 2003;108(11):1329–1335. <http://dx.doi.org/10.1161/01.CIR.0000087407.53326.31>.
- Soejima K, Stevenson WG, Sapp JL, Selwyn AP, Couper G, Epstein LM. Endocardial and epicardial radiofrequency ablation of ventricular tachycardia associated with dilated cardiomyopathy: the importance of low-voltage scars. *J Am Coll Cardiol.* 2004;43(10):1834–1842. <http://dx.doi.org/10.1016/j.jacc.2004.01.029>.
- Cesario DA, Vaseghi M, Boyle NG, et al. Value of high-density endocardial and epicardial mapping for catheter ablation of hemodynamically unstable ventricular tachycardia. *Heart Rhythm.* 2006;3(1):1–10. <http://dx.doi.org/10.1016/j.hrthm.2005.10.015>.
- Daniels DV, Lu Y-Y, Morton JB, et al. Idiopathic epicardial left ventricular tachycardia originating remote from the sinus of Valsalva: electrophysiological characteristics, catheter ablation, and identification from the 12-lead electrocardiogram. *Circulation.* 2006;113(13):1659–1666. <http://dx.doi.org/10.1161/CIRCULATIONAHA.105.611640>.
- Cano O, Hutchinson M, Lin D, et al. Electroanatomic substrate and ablation outcome for suspected epicardial ventricular tachycardia in left ventricular non-ischemic cardiomyopathy. *J Am Coll Cardiol.* 2009;54(9):799–808. <http://dx.doi.org/10.1016/j.jacc.2009.05.032>.
- Garcia FC, Bazan V, Zado ES, Ren J-F, Marchlinski FE. Epicardial substrate and outcome with epicardial ablation of ventricular tachycardia in arrhythmogenic right ventricular cardiomyopathy/dysplasia. *Circulation.* 2009;120(5):366–375. <http://dx.doi.org/10.1161/CIRCULATIONAHA.108.834903>.
- Dalal D, Jain R, Tandri H, et al. Long-term efficacy of catheter ablation of ventricular tachycardia in patients with arrhythmogenic right ventricular dysplasia/cardiomyopathy. *J Am Coll Cardiol.* 2007;50(5):432–440. <http://dx.doi.org/10.1016/j.jacc.2007.03.049>.
- Verma A, Kilicaslan F, Schweikert RA, et al. Short- and long-term success of substrate-based mapping and ablation of ventricular tachycardia in arrhythmogenic right ventricular dysplasia. *Circulation.* 2005;111(24):3209–3216. <http://dx.doi.org/10.1161/CIRCULATIONAHA.104.510503>.
- Kumar S, Barbhuiya C, Nagashima K, et al. Ventricular tachycardia in cardiac sarcoidosis: characterization of ventricular substrate and outcomes of catheter ablation. *Circ Arrhythm Electrophysiol.* 2015;8(1):87–93. <http://dx.doi.org/10.1161/CIRCEP.114.002145>.
- Stevenson WG, Wilber DJ, Natale A, et al. Irrigated radiofrequency catheter ablation guided by electroanatomic mapping for recurrent ventricular tachycardia after myocardial infarction: the multicenter thermocool ventricular tachycardia ablation trial. *Circulation.* 2008;118(25):2773–2782. <http://dx.doi.org/10.1161/CIRCULATIONAHA.108.788604>.
- Delacretaz E, Stevenson WG, Ellison KE, Maisel WH, Friedman PL. Mapping and radiofrequency catheter ablation of the three types of sustained monomorphic ventricular tachycardia in nonischemic heart disease. *J Cardiovasc Electrophysiol.* 2000;11(1):11–17. <http://www.ncbi.nlm.nih.gov/pubmed/10695454> Accessed 17.05.16
- Schmidt B, Chun KRJ, Baensch D, et al. Catheter ablation for ventricular tachycardia after failed endocardial ablation: epicardial substrate or inappropriate endocardial

- ablation? *Heart Rhythm*. 2010;7(12):1746–1752. <http://dx.doi.org/10.1016/j.hrthm.2010.08.010>.
17. Tanner H, Hindricks G, Volkmer M, et al. Catheter ablation of recurrent scar-related ventricular tachycardia using electroanatomical mapping and irrigated ablation technology: results of the prospective multicenter Euro-VT-study. *J Cardiovasc Electrophysiol*. 2010;21(1):47–53. <http://dx.doi.org/10.1111/j.1540-8167.2009.01563.x>.
 18. Tung R, Michowitz Y, Yu R, et al. Epicardial ablation of ventricular tachycardia: an institutional experience of safety and efficacy. *Heart Rhythm*. 2013;10(4):490–498. <http://dx.doi.org/10.1016/j.hrthm.2012.12.013>.
 19. Della Bella P, Brugada J, Zeppenfeld K, et al. Epicardial ablation for ventricular tachycardia: a European multicenter study. *Circ Arrhythm Electrophysiol*. 2011;4(5):653–659. <http://dx.doi.org/10.1161/CIRCEP.111.962217>.
 20. Ramoul K, Tafer N, Dé F, et al. *Conscious Sedation with Sufentanil and Midazolam for Epicardial VT Ablation*. 2012.
 21. Fan R, Cano O, Ho SY, et al. Characterization of the phrenic nerve course within the epicardial substrate of patients with nonischemic cardiomyopathy and ventricular tachycardia. *Heart Rhythm*. 2009;6(1):59–64. <http://dx.doi.org/10.1016/j.hrthm.2008.09.033>.
 22. Sacher F. Epicardial ventricular tachycardia ablation a multicenter safety study. *J Am Coll Cardiol*. 2010;7(12):1746.
 23. Killu AM, Ebrille E, Asirvatham SJ, et al. Percutaneous epicardial access for mapping and ablation is feasible in patients with prior cardiac surgery, including coronary bypass surgery. *Circ Arrhythm Electrophysiol*. 2015;8(1):94–101. <http://dx.doi.org/10.1161/CIRCEP.114.002349>.
 24. Killu AM, Friedman PA, Mulpuru SK, Munger TM, Packer DL, Asirvatham SJ. Atypical complications encountered with epicardial electrophysiological procedures. *Heart Rhythm*. 2013;10(11):1613–1621. <http://dx.doi.org/10.1016/j.hrthm.2013.08.019>.