



Case report

Two cases of splenic neoplasms with differing imaging findings that required laparoscopic resection for a definitive diagnosis

Kazuhiro Hiyama^{*}, Izumi Kirino, Yasuo Fukui, Hideo Terashima

Department of Surgery, Atago Hospital, Kochi, Japan

ARTICLE INFO

Keywords:

Splenic hemangioma
 Splenic incidentaloma
 Laparoscopic splenectomy

ABSTRACT

Introduction and importance: Splenic tumors are rare and are sometimes found incidentally. In such cases, laboratory tests and imaging studies should be performed based on the diagnostic algorithm to determine whether the tumor is benign or malignant. However, we clinicians sometimes encounter challenging cases. Herein we experienced two challenging cases of splenic tumor which we could not correctly diagnosis preoperatively.

Case presentation: Case 1: A female in her 80s presented to our surgical department to undergo follow-up examinations for Stage IIIa ascending colon cancer. A follow-up CT scan showed marked enlargement of the splenic tumor which suggested metastatic cancer. We performed laparoscopic splenectomy.

Case 2: A healthy female in her 50s presented to our internal medicine department to undergo a workup after multiple splenic tumors. A follow-up CT scan showed that the tumors had grown slightly. We could not completely rule out a malignant tumor. She rejected further follow-up study and chose splenectomy.

Clinical discussion: We experienced two cases of splenic hemangioma with different clinical presentations and imaging findings. Although some studies have reported that biopsying a splenic tumor is a safe and effective way of distinguishing among splenic tumors, in our country splenic biopsies are seldom performed due to fears of causing intraabdominal bleeding or tumor dissemination. Clinicians should consider whether it would be better to perform follow up with a biopsy or splenectomy as a definitive treatment on a case-by-case basis.

Conclusion: Laparoscopic splenectomy can be used for definitive management in cases involving malignancy or an uncertain etiology.

1. Introduction

Splenic tumors include benign primary tumors, such as lymphangioma and hemangioma, and malignant primary tumors, such as malignant lymphoma and angioblastoma. Also, solid cancers, such as gastric, colon, and ovarian cancer sometimes metastasize to the spleen. In 2013, Heller suggested a diagnostic and follow-up strategy for splenic tumors [1], however, it is currently not easy to differentiate between the various histological types of splenic tumors and choose an appropriate treatment plan. Herein, we report two cases of splenic hemangioma with different imaging findings. The tumors mimicked malignant tumors, which led us to perform laparoscopic splenectomy.

2. Presentation of case [2]

2.1. Case 1

A female in her 80s presented to our surgical department to undergo follow-up examinations for ascending colon cancer, which had been resected one year earlier. She complained of mild discomfort in the left upper quadrant. She did not have a fever. She had undergone laparoscopic right hemicolectomy for advanced ascending colon cancer (pT4a N1 M0, Stage IIIa, according to the Japanese Classification of Colorectal, Appendiceal, and Anal Carcinoma, Ninth English Edition) one year ago. According to her wishes, she had not received adjuvant chemotherapy. Otherwise, her medical history was unremarkable and did not include hypertension or hyperlipidemia. On physical examination, her spleen was not palpable, and she did not have lymphadenopathy.

A contrast-enhanced computed tomography (CT) scan performed 6 months after the colon surgery showed a solitary splenic tumor

^{*} Corresponding author at: Department of Surgery, Atago Hospital, 1-1-13 Atago-machi, Kochi, Japan.

E-mail address: hiyama@atago-hp.or.jp (K. Hiyama).

(maximum diameter: 1.5 cm) without any other organ metastasis or dissemination. The tumor was homogenous and well-demarcated (Fig. 1a, b). Six months later, a follow-up contrast-enhanced CT scan showed marked enlargement of the splenic tumor (maximum diameter: 3.0 cm), without any other organ metastasis or dissemination. Moreover, the tumor had two components; one (center lesion) is relatively high-intensity area, the other (peripheral area) is low-density area which suggested malignancy such as cancer metastasis (Fig. 1c, d). Retrospectively, we found a tiny splenic low-density area in the CT scan before colon surgery. A laboratory workup demonstrated normal tumor marker levels (carcinoembryonic antigen (CEA): 5.2 ng/mL, cancer antigen 19-9 (CA19-9): <0.5 U/mL). Since we had experienced a case of solitary splenic metastasis of colon cancer in past, we suspected metastatic cancer due to the rapid progression of the disease. We performed laparoscopic splenectomy (Fig. 2).

Intraoperatively, we didn't find any metastatic lesions other than the splenic tumor. The operation was performed without any postoperative complications. Histopathologically, a cystic nodule was found in the spleen (Fig. 3), which microscopically consisted of proliferating blood vessels without epithelial abnormalities. The tumor was diagnosed as a hemangioma (Fig. 4). She was alive 12 months after the surgery without any recurrent lesion.

2.2. Case 2

A healthy female in her 50s presented to our internal medicine department to undergo a workup after multiple splenic tumors had been detected by ultrasound during a health check-up. She did not have a fever or abdominal pain. Her past medical history was not specific without panic disorder and appendicitis in childhood. She was taking clonazepam for a while. She was not in acute distress, and her vital signs

were non-specific. On physical examination, her spleen was not palpable, and she did not have lymphadenopathy.

A contrast-enhanced CT scan (Fig. 5a, b) showed innumerable splenic tumors, which were homogeneous, but poorly demarcated. The maximum diameter of the largest tumor was 3 cm. The tumors were not enhanced. The attending physician decided to perform a follow-up CT scan 6 months later.

The patient was referred to our surgical department to undergo a more detailed consultation at that time. A laboratory workup demonstrated a normal complete blood count, an elevated lactate dehydrogenase level (404 IU/L), and a slightly elevated CA19-9 level (58.1 U/mL), but a normal CEA level (2.3 ng/mL). A follow-up contrast-enhanced CT scan showed that the tumors had grown slightly (maximum diameter: 3.5 cm), but there were no findings that were indicative of diseases affecting other organs, such as solid cancer (Fig. 5c, d). No specific findings were noted during upper or lower endoscopy. We could not completely rule out a malignant tumor (primary splenic malignant neoplasm or metastatic splenic neoplasm of unknown origin) because of the following: 1. The tumors exhibited poor demarcation. 2. The tumors grew slightly over 6 months. 3. The patient's CA19-9 level was slightly elevated. We carefully explained both of further follow-up study (repeated CT scan 3–6 months later or tumor biopsy) and splenectomy as the “definitive treatment”. The patient rejected further follow-up study and chose splenectomy.

The operation was performed without any postoperative complications. Histopathologically, multiple nodules were found in the spleen, which microscopically consisted of proliferating blood vessels without epithelial abnormalities. The tumors were diagnosed as hemangiomas. She didn't show at the follow up visit.

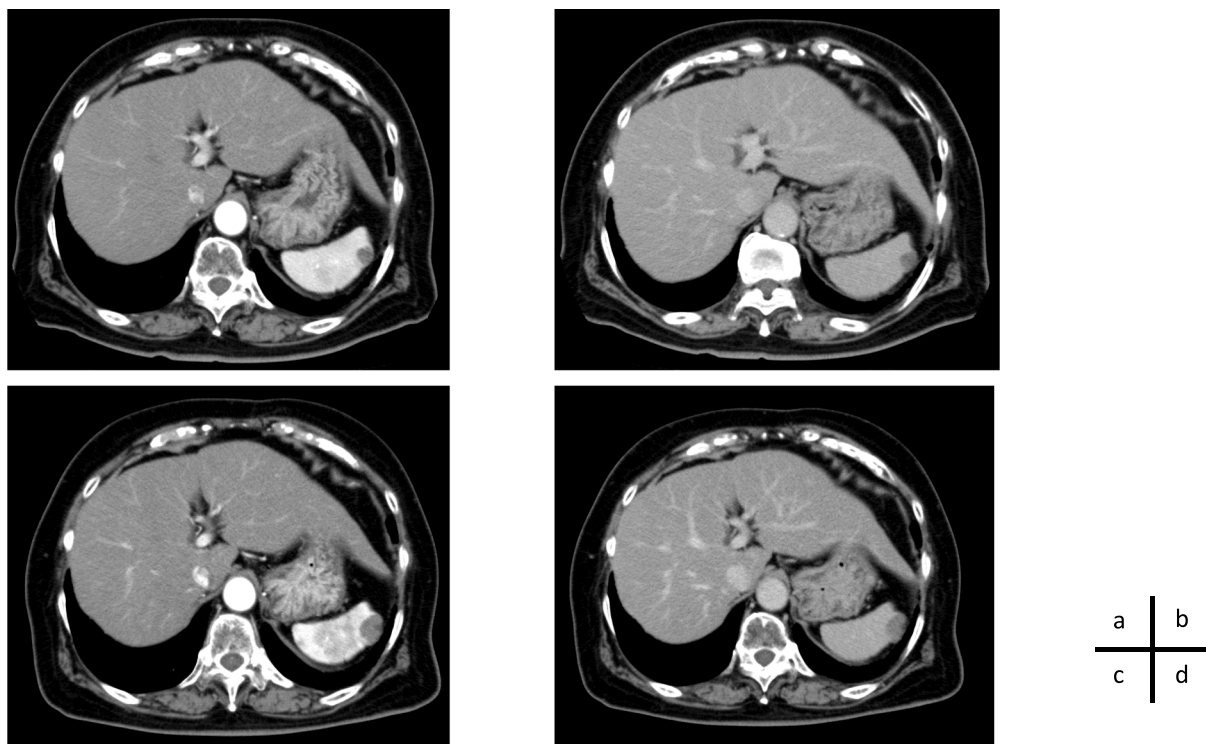


Fig. 1. Contrast-enhanced CT scans obtained in case 1

Initial visit: (a) arterial phase; (b) delayed phase

A solitary splenic tumor (maximum diameter: 1.5 cm) was seen.

Six months later: (c) arterial phase; (d) delayed phase

The tumor had enlarged (maximum diameter: 3.0 cm) with two components; one (center lesion) is relatively high-intensity area, the other (peripheral area) is low-density area.

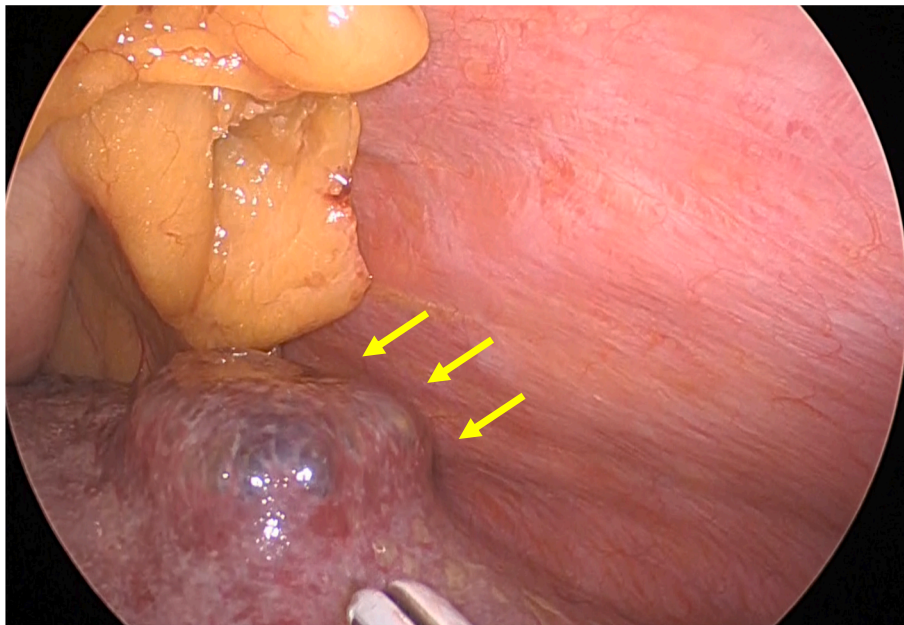


Fig. 2. Laparoscopic image of the tumor in case 1. A solitary, slightly hard tumor was seen (arrow).



Fig. 3. Resected spleen (case 1). A cystic nodule (3.0 × 3.0 cm) was found in the spleen.

3. Discussion

Splenic tumors are relatively rare. In fact, Bostick WL only encountered 10 cases among 80,527 people [3]. There are various histological types, including benign primary tumors, such as lymphangioma, hamartoma, and hemangioma; malignant primary tumors, such as malignant lymphoma and angiosarcoma; and metastatic tumors [4–6]. The most common type of primary benign splenic tumor is hemangioma, almost all of which occur as solitary lesions [7]. However, there have been a few reports about cases involving multiple splenic tumors [8,9]. On the other hand, malignant primary splenic tumors, such as angiosarcoma, are very rare. However, their prognosis is quite poor [7]. The

clinical presentation including imaging findings of splenic tumors is highly variable [10]; therefore, we must learn how to differentiate among them. Although Heller suggested a diagnostic and follow-up strategy for splenic tumors [1], we clinicians sometimes encountered challenging cases.

We experienced two cases of splenic hemangioma with different clinical presentations and imaging findings.

Especially in case 1, we suspected a metastatic tumor derived from adenocarcinoma of the ascending colon because of the patient's medical history and the rapid enlargement of the tumor. Solitary splenic metastases are rare, but they can occur in some cases [11], also we had experienced a case in past. Since some studies have reported that

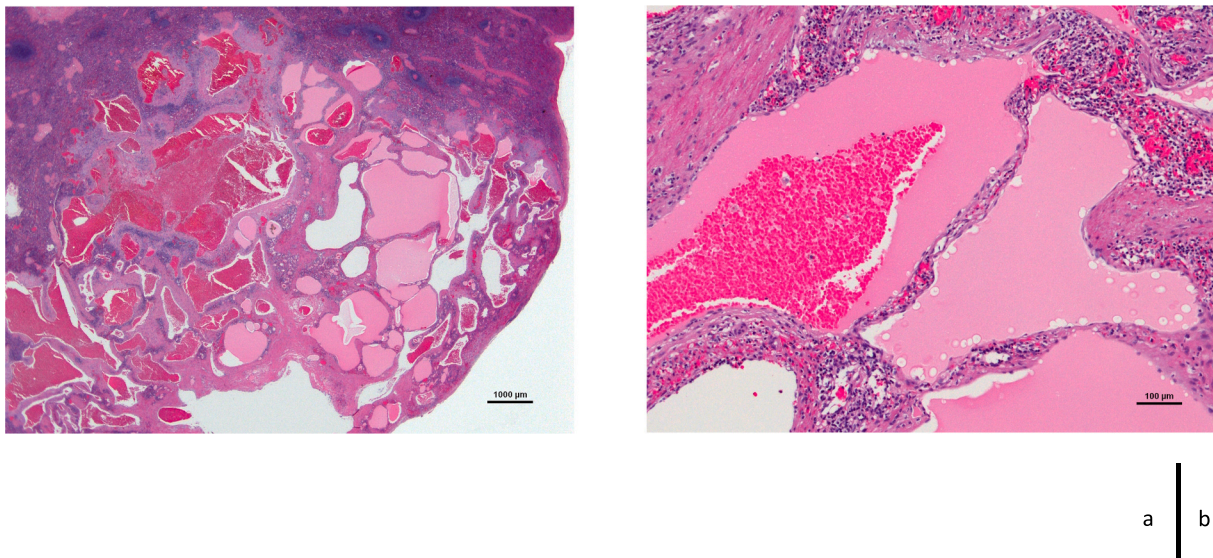


Fig. 4. Histopathological findings of the resected spleen (case 1)
The tumor consisted of proliferating blood vessels without any epithelial abnormalities. These findings were consistent with hemangioma.

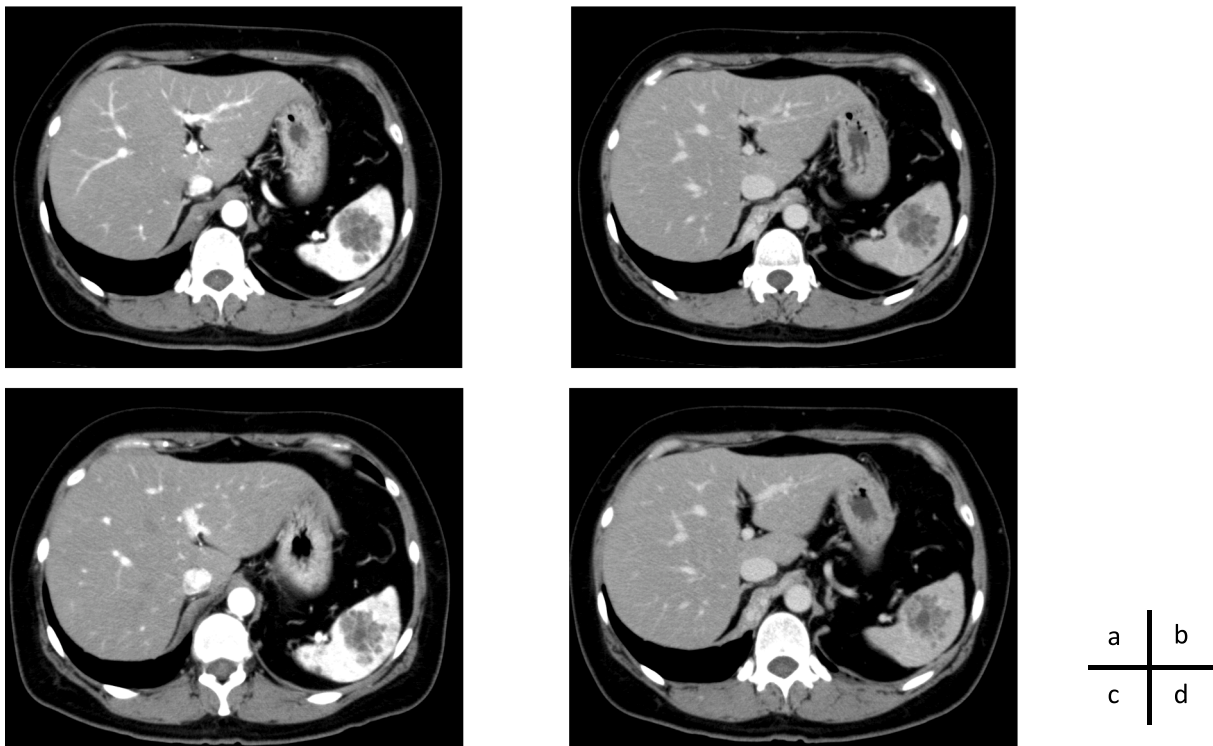


Fig. 5. Contrast-enhanced computed tomography (CT) scans obtained in case 2
Initial visit: (a) arterial phase; (b) delayed phase
Innumerable splenic tumors were seen.
Six months later: (c) arterial phase; (d) delayed phase
The tumors had enlarged.

biopsying a splenic tumor is a safe and effective way of distinguishing among splenic tumors [12–16], firstly we had considered biopsying the tumor as well. However, in Japan splenic biopsies are seldom performed due to fears of causing intraabdominal bleeding or tumor dissemination. Moreover, a case report described severe complications that occurred after a biopsy of a splenic tumor [17]. In addition, there is insufficient evidence about biopsy-induced tumor dissemination. All things

considered, biopsying splenic tumors might be effective; however, clinicians should consider whether it would be better to perform follow up with a biopsy or splenectomy as a definitive treatment on a case-by-case basis, while taking account of the potential complications. In case 1, since we strongly suspected splenic metastasis, performing splenectomy without a biopsy after obtaining detailed informed consent was acceptable.

Laparoscopic splenectomy for splenic tumor was first performed by Hodge in 1895 [9]. The main benefits of laparoscopic splenectomy are that it results in greater visualization of the tumor, improved post-operative outcomes, and a low complications rate. It was particularly useful in our case 1, as we initially suspected that the tumor was a metastatic lesion, and hence, it was important to rule out other types of metastases, such as dissemination.

4. Conclusion

Splenic tumors are rare and are often found incidentally. Heller's diagnostic guidelines for splenic masses are useful for clinically evaluating these lesions. Such evaluations should include clinical laboratory studies; imaging (ultrasonography, CT, and/or MRI); and, if required, interventions (a biopsy or surgical procedure). Laparoscopic splenectomy should be considered in cases involving diagnostic uncertainty or a growing mass.

Abbreviations

CA19-9	cancer antigen 19-9
CEA	carcinoembryonic antigen
CT	computed tomography
MRI	magnetic resonance imaging

Sources of funding

None.

Ethical approval

N/A.

Consent

Written informed consent was obtained from the patient for publication of this case report and accompanying images. A copy of the written consent is available for review by the Editor-in-Chief of this journal on request.

Research registration

N/A.

Guarantor

Kazuhiro Hiyama.

Provenance and peer review

Not commissioned, externally peer-reviewed.

CRediT authorship contribution statement

Kazuhiro Hiyama performed both surgeries and made substantial

contributions to conception, design, data acquisition and interpretation of the study and was involved in initial drafting of the manuscript and critically revised the final manuscript.

Other authors were involved in revision of the final manuscript.

All authors reviewed the final manuscript and give approval of the version to be published and agree to be accountable for all aspects of the work in ensuring that questions related to the accuracy or integrity of any part of the work are appropriately investigated and resolved.

Declaration of competing interest

The authors declare that they have no conflicts of interest and that there are no relevant financial disclosures to report.

References

- [1] M.T. Heller, M. Harisinghani, J.D. Neitlich, P. Yeghiyan, L.L. Berland, Managing incidental findings on abdominal and pelvic CT and MRI, part 3: white paper of the ACR incidental findings committee II on splenic and nodal findings, *J. Am. Coll. Radiol.* 10 (11) (2013) 833–839.
- [2] R.A. Agha, T. Franchi, C. Sohrabi, G. Mathew, A. Kerwan, The SCARE 2020 guideline: updating consensus surgical CASE REport (SCARE) guidelines, *Int. J. Surg.* 84 (2020) 226–230.
- [3] W.L. Bostick, Primary splenic neoplasms, *Am. J. Pathol.* 21 (6) (1945) 1143–1165.
- [4] R.K. Kaza, S. Azar, M.M. Al-Hawary, I.R. Francis, Primary and secondary neoplasms of the spleen, *Cancer Imaging* 10 (1) (2010) 173–182.
- [5] T. Vancauwenberghe, A. Snoeckx, D. Vanbeckevoort, S. Dymarkowski, F. M. Vanhoenacker, Imaging of the spleen: what the clinician needs to know, *Singap. Med. J.* 56 (3) (2015) 133–144.
- [6] Z.J. Ricci, F.S. Mazzariol, M. Flusberg, V. Chernyak, S.K. Oh, B. Kaul, et al., Improving diagnosis of atraumatic splenic lesions, part II: benign neoplasms/nonneoplastic mass-like lesions, *Clin. Imaging* 40 (4) (2016) 691–704.
- [7] R.M. Abbott, A.D. Levy, N.S. Aguilera, L. Gorospe, W.M. Thompson, From the archives of the AFIP: primary vascular neoplasms of the spleen: radiologic-pathologic correlation, *Radiographics* 24 (4) (2004) 1137–1163.
- [8] H. Steininger, D. Pfofe, L. Marquardt, H. Sauer, R. Markwat, Isolated diffuse hemangiomatosis of the spleen: case report and review of literature, *Pathol. Res. Pract.* 200 (6) (2004) 479–485.
- [9] J. Shinde, S. Pandit, S. Kolte, S.P. Singh, Laparoscopic splenectomy for haemangioma of the spleen, *J. Minim. Access Surg.* 10 (1) (2014) 42–44.
- [10] A. Abrishami, N. Khalili, S. Kooraki, Y. Abrishami, L. Grenacher, H.U. Kauczor, Evaluation of cross-sectional imaging features that aid in the differentiation of benign and malignant splenic lesions, *Eur. J. Radiol.* 136 (2021), 109549.
- [11] A. Obana, N. Komatsu, K. Aiba, S. Nakanishi, M. Abe, T. Yamaguchi, et al., A case of long-term survival after splenectomy for solitary splenic metastasis from gastric cancer, *World J. Surg. Oncol.* 18 (1) (2020) 250.
- [12] M.T. Keogan, K.S. Freed, E.K. Paulson, R.C. Nelson, L.G. Dodd, Imaging-guided percutaneous biopsy of focal splenic lesions: update on safety and effectiveness, *AJR Am. J. Roentgenol.* 172 (4) (1999) 933–937.
- [13] B.C. Lucey, G.W. Boland, M.M. Maher, P.F. Hahn, D.A. Gervais, P.R. Mueller, Percutaneous nonvascular splenic intervention: a 10-year review, *AJR Am. J. Roentgenol.* 179 (6) (2002) 1591–1596.
- [14] M.D. McInnes, A.Z. Kielar, D.B. Macdonald, Percutaneous image-guided biopsy of the spleen: systematic review and meta-analysis of the complication rate and diagnostic accuracy, *Radiology* 260 (3) (2011) 699–708.
- [15] A.K. Singh, S. Shankar, D.A. Gervais, P.F. Hahn, P.R. Mueller, Image-guided percutaneous splenic interventions, *Radiographics* 32 (2) (2012) 523–534.
- [16] N. Patel, G. Dawe, K. Tung, Ultrasound-guided percutaneous splenic biopsy using an 18-G core biopsy needle: our experience with 52 cases, *Br. J. Radiol.* 88 (1055) (2015), 20150400.
- [17] S.Y. Cho, E. Cho, C.H. Park, H.J. Kim, J.Y. Koo, Septic shock due to granulocytella adiacens after endoscopic ultrasound-guided biopsy of a splenic mass: a case report, *World J. Gastroenterol.* 27 (8) (2021) 751–759.