

# Arthroscopic management of mucoid degeneration of anterior cruciate ligament

Chirag H Chudasama, Vyoma C Chudasama<sup>1</sup>, Mukund M Prabhakar<sup>2</sup>

## ABSTRACT

**Background:** Mucoid degeneration of the anterior cruciate ligament (ACL) is a less understood entity. The purpose of this study was to diagnose mucoid degeneration of anterior cruciate ligament and to assess the effectiveness of arthroscopic treatment in these patients.

**Materials and Methods:** Between December 2007 and November 2011, 20 patients were diagnosed to be suffering from mucoid degeneration of anterior cruciate ligament (ACL) on the basis of magnetic resonance imaging (MRI), histopathology, and arthroscopy findings. 12 patients were males and 8 patients were females, with mean age of 42.2 years for males (range 28-52 years) and 39.4 years for females (range 30-54 years). They presented with pain on terminal extension (n=10) and on terminal flexion (n=2) without history of significant preceding trauma. MRI showed an increased signal in the substance of the ACL both in the T1- and T2-weighted images, with a mass-like configuration that was reported as a partial or complete tear of the ACL by the radiologist. At arthroscopy, the ACL was homogenous, bulbous, hypertrophied, and taut, occupying the entire intercondylar notch. A debulking of the ACL was performed by a judicious excision of the degenerated mucoid tissue, taking care to leave behind as much of the intact ACL as possible. Releasing it and performing a notchplasty treated impingement of the ACL to the roof and lateral wall. In one patient, we had to replace ACL due to insufficient tissue left behind to support the knee.

**Results:** Good to excellent pain relief on terminal flexion-extension was obtained in 19 of 20 knees. The extension deficit was normalized in all knees. Lachman and anterior drawer test showed a firm endpoint in all, and 85% (n=17) showed good to excellent subjective satisfaction.

**Conclusions:** Mucoid hypertrophy of the ACL should be suspected in elderly persons presenting pain on terminal extension or flexion without preceding trauma, especially when there is no associated meniscal lesion or ligamentous insufficiency. They respond well to a judicious arthroscopic release of the ACL with notchplasty.

**Key words:** Anterior cruciate ligament, arthroscopic debridement, mucoid degeneration, notchplasty

## INTRODUCTION

Unlike tears and ganglion cysts of the anterior cruciate ligament (ACL), mucoid degeneration is a less-understood entity. The injury or loss of functional synovial lining protecting the ACL is the primary lesion

causing mucoid degeneration of ACL though there was no significant preceding trauma that patients can relate to current symptoms.<sup>1</sup> But the symptomatology, MRI findings, and arthroscopy appearance are consistent.<sup>2</sup> The excision of the degenerated ACL has been the treatment of the choice, the authors believe that if the taut and hypertrophied ACL were to be debulked and notchplasty done, full extension could be achieved without having to excise the entire ACL. The purpose of this study was to describe the clinical characteristics and diagnosis of mucoid degeneration of the ACL and to assess the outcomes of arthroscopic treatment in a series of 20 patients.

Departments of Orthopedics, <sup>1</sup>Microbiology, B.J. Medical College, Civil Hospital, F-5, Payas Flats, Near Navrojee Hall, Dafnalna Road, Shahibaug, <sup>2</sup>Department of Orthopedics, B.J. Medical College, Director of Paraplegia Hospital and Physiotherapy College, Medical Superintendent of Civil Hospital, Asarva, Ahmedabad, India

**Address for correspondence:** Dr. Chirag Chudasama, F-5, Payas Flats, Near Navrojee Hall, Dafnalna Road, Shahibaug, AT: Ahmedabad – 380 004, India. E-mail: chiragortho@gmail.com

## MATERIALS AND METHODS

In this prospective study, 20 patients were included. The mean age was 42.2 years (range 28-52 years) in males and 39.4 years (range 30-54 years) in females. There were 12 males and 8 females. All the patients had clinical symptoms of central knee pain behind patella without any prior trauma (18 patients on terminal extension and

Access this article online	
Quick Response Code:	Website: www.ijonline.com
	DOI: 10.4103/0019-5413.101037

2 patients on terminal flexion). In four patients, there was mean flexion deformity of 6°. The type of activity performed was: physically active like running, sports, and army training (n=6, 30%); moderately active doing routine work (n=12, 60%); and sedentary (n=2, 10%). The mean follow up was 24 months (range 12–36 months).

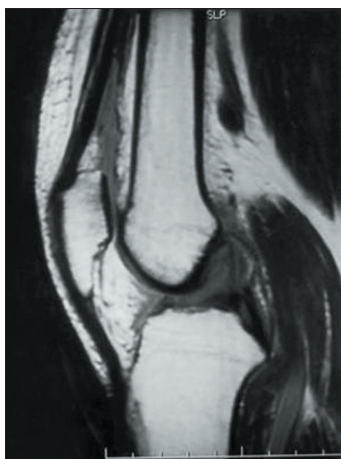
All patients presented with identical symptoms, but the duration of symptoms varied. The symptoms started insidiously, had a mean duration of 21 months (range 12–47 months) without preceding significant trauma. Eighteen patients had extension deficit and two patients had limited flexion.<sup>3,4</sup> There was medial joint pain in two patients. There was no complaint of instability. Anterior Lachman and anterior drawer test showed firm endpoint in all patients, with +1 laxity in three patients. All patients were treated with nonsteroidal anti-inflammatory drugs and physiotherapy for a minimum of 2 months before contemplating magnetic resonance imaging (MRI) and treatment.

Plain roentgenograph of both the knees was done with anteroposterior weight bearing, lateral and skyline views. MRI was performed with 1.5 T machines. Radiographic diagnosis was made only when all three key criteria<sup>5,6</sup> were met: (1) abnormally thickened and ill-defined ACL, (2) maintenance of normal orientation and continuity, and (3) increased intraligamentous signals (intermediate signal intensity on T1-weighted images and high signal intensity on T2-weighted and Proton Density Weighted images [Figure 1]). Preoperative diagnosis was established by the MRI findings based on clinical manifestations.

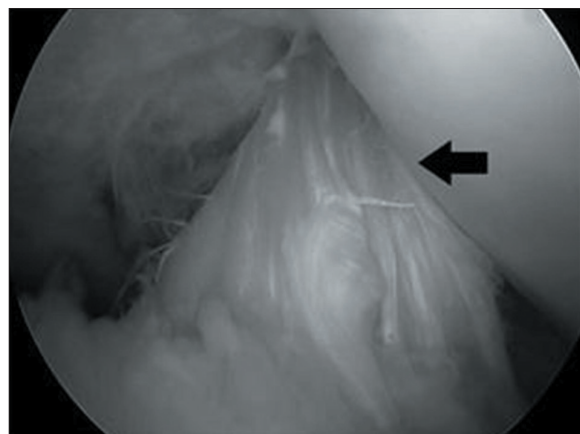
Arthroscopy was performed by use of a 30° lens through standard anterolateral and anteromedial portals. All compartments were explored to evaluate the state of menisci, ligaments, and cartilage. The chondral lesion of each patient was described according to the Outerbridge

classification.<sup>7</sup> The locations of the lesions on the articular surfaces of the patella, trochlea, medial femoral condyle, lateral femoral condyle, medial tibial plateau, and lateral tibial plateau were recorded. Meniscus lesions were assessed with probe and recorded. Bulk specific to anteromedial (AM)–posterolateral (PL) bundles of ACL, its color, and its tautness hooked with probe were recorded. Impingement of ACL fibers to lateral wall of intercondylar notch, and lateral compartment during flexion–extension maneuver were recorded [Figure 2].

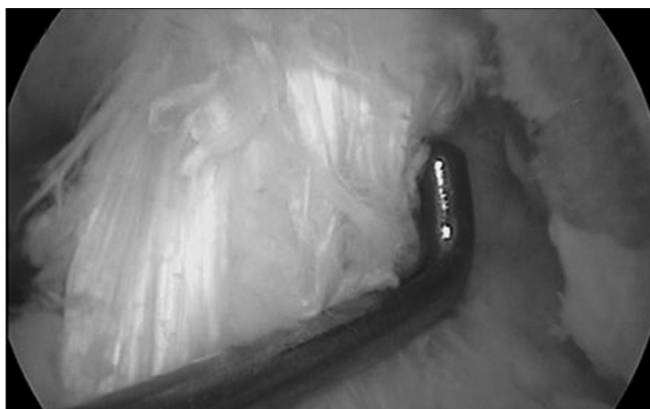The aim of surgery was to remove as much of the degenerative mass as possible without having to sacrifice the entire ACL. Thus, the remaining ACL consisted of some intact anteromedial or posterolateral portion of the ACL interspersed with degenerate ACL tissue. Care was taken to see that this remaining ACL had intact attachment to the femoral condyle and did not impinge on the roof or lateral wall of the notch [Figure 3]. By use of basket forceps, three biopsy specimens were taken from yellowish degenerative lesions and submitted for histopathologic examination. The materials were stained with H and E and then with mucoid tissue-specific Alcian blue [Figure 4]. In knees without notch narrowing, debridement of the hypertrophied ACL was performed first beginning with the removal of small osteocartilaginous fragments from the upper portion of the lateral wall and roof by use of a 6.4-mm curved osteotome. This allowed easier inspection of the inner space between the ACL and the lateral wall, and accurate removal of impinging structures. We decompressed the lateral wall and roof from anterior to posterior while performing a flexion–extension maneuver with a 4.5-mm motorized bur and curette. Care was taken to remove all visible impinging structures in the posterior portion of the notch. Copious debridement of mucoid hypertrophied lesions of the ACL was performed by use of basket forceps as well as a 4.2-mm motorized shaver. Some of the mass was removed by first



**Figure 1:** Proton density show increasing intraligamentous signal intensity of the Anterior cruciate ligament over the left knee



**Figure 2:** Arthroscopic examination of a left knee, showing impingement (arrow) of hypertrophied posterolateral portion of ACL to lateral wall and roof of intercondylar notch during extension



**Figure 3:** Arthroscopic examination of a left knee, showing impingement of hypertrophied posterolateral portion of ACL to lateral wall and roof of intercondylar notch during extension

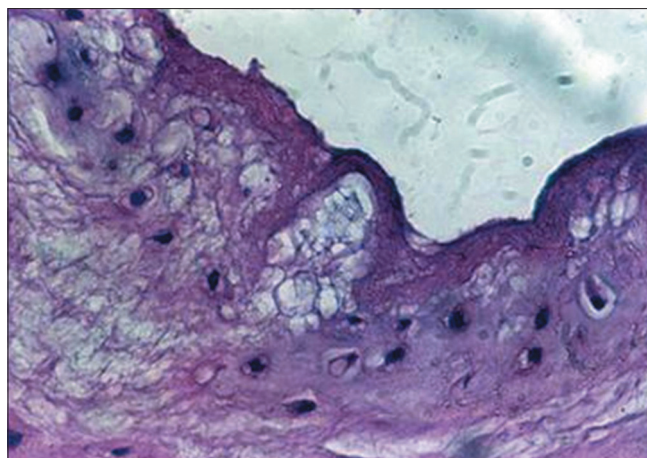
teasing between the anterior fibers of the ACL using a probe and then removing it with an arthroscopy grabber. The major posterior portion of the mass was removed using the basket punch (Acuflex) introduced through the anteromedial portal, with the arthroscope through the anterolateral portal. The probe was used to assess the tension and the clearance of the remaining ACL and the notch.

During the followup, no immobilizer or brace was used except in one patient who had undergone ACL reconstruction. All other patients were encouraged to perform daily active range of motion exercises with quadriceps strengthening and allowed to carry full weight bearing loads immediately. Continuous passive motion devices were not used. Knee laxity was checked clinically with Lachman test.

## RESULTS

Preoperative central knee pain on terminal extension was moderate in 10 knees and severe in 8 knees. Postoperatively, 12 knees showed complete pain relief and 7 showed pain improvement by at least 3 Visual Analogue Scale (VAS) grades, for a total of 16 had well to excellent results regarding pain on terminal extension. Preoperative average International Knee Documentation Committee (IKDC) score<sup>8</sup> was 33.6 which improved postoperatively to the average 73.2. The flexion deformity was found in four patients, with a mean angle of 6°. Postoperatively, it improved significantly with no deformity.

MRIs of all 20 patients showed an ACL that appeared bulky, occupying almost the entire intercondylar notch, with a marked increased signal, particularly in the T2-weighted images, and with a mass-like configuration intertwined with its fibers with “celery stalk” sign.<sup>9,10</sup> On MRI, 6 patients had medial compartment arthritis, 4 patients had torn medial meniscus grade III, and 1 patient had grade II tear in posterior horn of lateral meniscus.



**Figure 4:** Photomicrograph showing distorted collagen fibers with scanty myxomatous degeneration (H and E stain, x40)

Arthroscopy showed osteoarthritic changes in 9 knees and concomitant degenerative pathologies in 4 knees; these included meniscal tears and synovitis. Six (30%) degenerative lesions of the medial meniscus and 1 (0.5%) degenerative lesion of lateral meniscus were noted. Three medial and one lateral meniscectomies were done at the same time. Three femoropatellar cartilaginous lesions (15%), 4 (20%) medial femorotibial lesions (two grade 1, one grade 2, one grade 3), and 1 (0.5%) lateral femorotibial lesion grade 1 were observed. Nine knees (45%) did not present any cartilaginous lesion. Three knees had protruding notch osteophytes. At arthroscopy, the ACL appeared homogenous, bulbous, and hypertrophied in all patients. It filled the entire intercondylar notch and was unusually taut, toward 90° of flexion in 2 patients with hypertrophied AM bundle of ACL, and taut in extension in rest of the patients with hypertrophied PL bundle of ACL. The ACL fibers were interspersed with a yellowish homogenous mass. The posterolateral portion of the ACL bulged into the lateral compartment in extension impinging in the notch. By flexion–extension maneuver, impingements were reproduced under direct vision. When each knee was brought into full extension, impingement of the hypertrophied ACL to the lateral wall and roof of the intercondylar notch was observed.<sup>11,12</sup> Impingement was particularly apparent in knees with a severely hypertrophied ACL or narrowed notch, as well as limited knee joint extension.

Arthroscopic treatment consisted of debridement of the afflicted portion of the ACL in all cases. In six knees with evident notch narrowing, notchplasty was performed first. Because yellowish degenerative hypertrophied lesions were entangled around the posterolateral ACL fibers, the anteromedial portion was retained in 18 patients. In 2 patients, posterolateral portion of ACL was retained because of hypertrophied degenerated AM bundle of ACL.



Although in one patient after debridement, the remaining portion of the ACL was not enough to stabilize the knee, so we had to reconstruct the ACL with hamstring graft which is comparable with the study by Lintz *et al.* (7%).<sup>1</sup>

At an average followup time of 24 months (range 12-36 months), all except two patients had a full range of painless motion. The Lachman test was performed in all patients. It was 1 grade higher as compared with the opposite knee in 14 knees and the same as the opposite knee in 6 knees. All patients had a firm endpoint on Lachman test without any symptoms of instability, inferring some intact portion of the ACL between the tibia and the femur. Two patients had pivot shift positive +1 with glide and 18 patients had negative pivot shift. A soft endpoint on anterior translation would imply no intact ACL tissue in the intercondylar area. The histopathologic appearance and reports of the biopsy specimens were consistent with mucoid degeneration of the ACL. Postoperative MRI was performed in five patients. Regression of the size and bulkiness of the treated ACL was seen, with the T2-weighted images showing decreased signal with some intact ACL fibers between the tibia and femur.

## DISCUSSION

The mucoid hypertrophy of the ACL is a rare condition found in middle-aged individuals. Mucoid degeneration of Anterior Cruciate Ligament is not an uncommon pathology, but is often unknown. According to Bergin *et al.*<sup>6</sup> and Salvati *et al.*,<sup>13</sup> reported its occurrence as 2 and 5%, respectively, of knee where MRI was done. Our findings were incidental in initial 4 cases where clinical and radiological findings were not correlated as radiologist reported partial rupture of ACL only. In practice and in the literature, it is often confused with a diagnosis of partial ACL rupture. It becomes apparent in two subpopulations of patients. The first group is younger, active, athletic, in whom we can assume an ACL mechanism affected by real trauma or repeated microtraumas causing an early lesion.<sup>14</sup> The second group is older and presents with progressive degenerative ACL lesions, with frequent concomitant degenerative meniscal lesions. The pathogenesis of mucoid degeneration is unclear, but injury, ganglion cysts, and degenerative process leading to loss of synovial lining have been implicated as the most likely etiologic factors in the production of this change. In younger group the possible cause of repetitive minor trauma is impingement of the ACL to the lateral wall and roof of the narrow notch, which has been reported to be more common in female patients.<sup>15</sup> In second group there is subtle alterations in joint kinematics due to osteoarthritis, meniscal tears, and other degenerative changes, leading to stretching of cruciate ligaments. Fealy *et al.*<sup>16</sup> suggested

that knee pain on flexion might be caused by tensioning of the diseased AM bundle of the ACL. Narvekar and Gajjar<sup>17</sup> explained knee pain through increased volume and tension within the ligament. For Kumar *et al.*<sup>18</sup> the pain is attributable to the effect of the ACL mass in the posterior notch. Hsu *et al.*<sup>19</sup> and Kim *et al.*<sup>11</sup> attribute it to incarceration of the pathological ACL in the posterior femoro-tibial compartment. However, we found that the hypertrophied ACL bulged into the lateral compartment, impinged on the lateral tibiofemoral joint, and caused an extension or flexion block, depending on the position of the impingement in the lateral tibiofemoral joint. We believe the most important source of pain is mechanical impingement, associated with unique function of the ACL in providing nociceptive sensory signals.

Another notion addressed by this work is that of secondary instability. It is mentioned elsewhere only by McIntyre *et al.*<sup>2</sup> who reported one case of atraumatic ACL rupture at 1 postoperative year after partial resection. Our results indicate that postoperative laxity, largely asymptomatic, can increase anterior laxity over time and evoke instability. In one of our patients (5%), ACL reconstruction was later necessary.

## CONCLUSION

Mucoid hypertrophy of the ACL should be clinically suspected in elderly person presenting with persistent knee pain on terminal extension without preceding trauma, especially when associated with extension deficit, which is more common in elderly individual with degenerated knee. The MRI findings are specific for clinical diagnosis before arthroscopy. Arthroscopic debridement of mucoid hypertrophy of the ACL in conjunction with notchplasty can effectively provide symptomatic improvement without instability.

## REFERENCES

1. Lintz F, Pujol N, Dejour D, Boisrenoult P, Beaufile P. Anterior cruciate ligament mucoid degeneration: Selecting the best treatment option. *Orthop Traumatol Surg Res* 2010;96:400-6. Epub 2010 May 8.
2. McIntyre J, Moelleken S, Tirman P. Mucoid degeneration of the anterior cruciate ligament mistaken for ligamentous tears. *Skeletal Radiol* 2001;30:312-5.
3. Makino A, Pascual-Garrido C, Rolón A, Isola M, Muscolo DL. Mucoid degeneration of the anterior cruciate ligament :MRI, clinical, intraoperative, and histological findings. *Knee Surg Sports Traumatol Arthrosc* 2011;19:408-11.
4. Motmans R, Verheyden F. Mucoid degeneration of the anterior cruciate ligament. *Knee Surg Sports Traumatol Arthrosc* 2009;17:737-40.
5. Nishimori M, Sumen Y, Sakaridani K. Mucoid degeneration of the anterior cruciate ligament: A report of two cases. *Magn*

- Reson Imaging 2004;22:1325-8.
6. Bergin D, Morrison WB, Carrino JA, Nallamshetty SN, Bartolozzi AR. Anterior cruciate ligament ganglia and mucoid degeneration: Coexistence and clinical correlation. *AJR Am J Roentgenol* 2004;182:1283-7.
  7. Text book of knee surgery: current practice, In: Aichroth PM, Editor, Edition Outerbridge classification, 1992. p. 392.
  8. Rossi MJ, Lubowitz JH, Guttman D. Development and validation of the international knee documentation committee subjective knee form. *Am J Sports Med* 2002;30:152.
  9. Hensen JJ, Coerkamp EG, Bloem JL, De Schepper AM. Mucoid degeneration of the anterior cruciate ligament *JBR-BTR* 2007; 90:192-3.
  10. Papadopoulou P. The celery stalk sign. *Radiology* 2007;245:916-7.
  11. Kim TH, Lee DH, Lee SH, Kim JM, Kim CW, Bin SI. Arthroscopic treatment of mucoid hypertrophy of the anterior cruciate ligament. *Arthroscopy* 2008;24:642-9.
  12. Melloni P, Valls R, Yuguero M, Saez A. Mucoid degeneration of the anterior cruciate ligament with erosion of the lateral femoral condyle. *Skeletal Radiol* 2004;33:359-62.
  13. Salvati F, Rossi F, Limbucci N, Pistoia ML, Barile A, Masciocchi C. Mucoid metaplastic-degeneration of anterior cruciate ligament. *J Sports Med Phys Fitness* 2008;48:483-7.
  14. Scranton PE Jr, Farrar EL. Mucoid degeneration of the patellar ligament in athletes. *J Bone Joint Surg Am* 1992;74:435-7.
  15. Cha JH, Lee SH, Shin MJ, Choi BK, Bin SI. Relationship between mucoid hypertrophy of the anterior cruciate ligament (ACL) and morphologic change of the intercondylar notch: MRI and arthroscopy correlation. *Skeletal Radiol* 2008;37:821-6.
  16. Fealy S, Kenter K, Dines JS, Warren RF. Mucoid degeneration of the anterior cruciate ligament. *Arthroscopy* 2001;17:E37.
  17. Narvekar A, Gajjar S. Mucoid degeneration of the anterior cruciate ligament. *Arthroscopy* 2004;20:141-6.
  18. Kumar A, Bickerstaff DR, Grimwood JS, Suvana SK. Mucoid degeneration of the cruciate ligament. *J Bone Joint Surg Br* 1999;81:304-5.
  19. Hsu CJ, Wang SC, Fong YC, Huang CY, Chiang IP, Hsu HC. Mucoid degeneration of the anterior cruciate ligament. *J Chin Med Assoc* 2006;69:449-52.

**How to cite this article:** Chudasama CH, Chudasama VC, Prabhakar MM. Arthroscopic management of mucoid degeneration of anterior cruciate ligament. *Indian J Orthop* 2012;46:561-5.

**Source of Support:** Nil, **Conflict of Interest:** None.

## Staying in touch with the journal

### 1) Table of Contents (TOC) email alert

Receive an email alert containing the TOC when a new complete issue of the journal is made available online. To register for TOC alerts go to [www.ijonline.com/signup.asp](http://www.ijonline.com/signup.asp).

### 2) RSS feeds

Really Simple Syndication (RSS) helps you to get alerts on new publication right on your desktop without going to the journal's website. You need a software (e.g. RSSReader, Feed Demon, FeedReader, My Yahoo!, NewsGator and NewzCrawler) to get advantage of this tool. RSS feeds can also be read through FireFox or Microsoft Outlook 2007. Once any of these small (and mostly free) software is installed, add [www.ijonline.com/rssfeed.asp](http://www.ijonline.com/rssfeed.asp) as one of the feeds.