

Combined Conjunctival Autograft and Overlay Amniotic Membrane Transplantation; a Novel Surgical Treatment for Pterygium

Siamak Zarei Ghanavati¹, MD, FICO; Mohamed Abou Shousha², MD; Carolina Betancurt², OD
Victor L. Perez², MD, PhD

¹Department of Ophthalmology, Khatam-al-Anbia Eye Institute, Mashhad University of Medical Sciences, Mashhad, Iran
²Bascom Palmer Eye Institute, Miller School of Medicine, University of Miami, Miami, FL, USA

Abstract

The authors report the long-term results of combined conjunctival autograft and overlay amniotic membrane transplantation (AMT) for treatment of pterygium as a new surgical technique. Nineteen patients including 12 male and 7 female subjects with pterygium (primary, 14 cases; recurrent, 5 cases) underwent combined conjunctival autograft and overlay AMT and were followed from 10 to 26 months. Mean age was 44.21±12.49 (range, 29.0-73.0) years. In one patient with grade T3 primary pterygium, the lesion recurred (5.2%, recurrence rate). No intra- and postoperative complication developed. This procedure seems a safe and effective surgical technique for pterygium treatment. Protection of the ocular surface during the early postoperative period reduces the friction-induced inflammation and might be helpful to prevent the recurrence.

Keywords: Amniotic Membrane Transplantation; Conjunctival Autograft; Primary Pterygium; Recurrent Pterygium

J Ophthalmic Vis Res 2014; 9 (3): 399-403.

INTRODUCTION

Pterygium is a wing-shape fibrovascular lesion of the ocular surface, which is associated with chronic sunlight exposure. Until now, a wide spectrum of treatment strategies have been described for pterygium treatment, including pterygium excision with bare sclera, conjunctival autograft, amniotic membrane transplantation (AMT), adjunctive use of mitomycin-C and beta radiation.^[1-5]

The most common complication after excision of the pterygium is recurrence and despite the reducing rate of recurrence, it is still the most challenging issue in management.^[2]

Although, the results of conjunctival autograft for treatment of pterygium, in terms of cosmetic outcome and lower recurrence rate, seem more ideal,^[6] amniotic membrane (AM) possesses several documented physiologic properties, including reduction of scarring,

inflammation, and vascularization, which might improve conjunctival autograft results for treatment of pterygium.^[7,8] It could also reduce friction over the cornea, conjunctival autograft and wound edge, which might help to reduce inflammation and scar formation.^[9-12]

In the current study, we describe the long-term results of novel surgical technique for treatment of pterygium using both advantages of conjunctival autograft and AMT. To the best of our knowledge, this is the first report on the use of overlay AMT combined with conjunctival autograft for treatment of pterygium.

METHODS

This prospective study was conducted at Bascom Palmer Eye Institute, University of Miami, USA. Institutional

Correspondence to:

Victor L. Perez, MD, PhD. Bascom Palmer Eye Institute, University of Miami, Miller School of Medicine, 900 Northwest, 17th Street, Miami, FL 33136, USA.
E-mail: vperez4@med.miami.edu

Received: 11-09-2013

Accepted: 01-10-2013

Access this article online

Quick Response Code:



Website:

www.jovr.org

DOI:

10.4103/2008-322X.143386

review board approval was obtained and the study followed the tenets of the declaration of Helsinki.

Comprehensive ophthalmic examination was done for all patients including uncorrected and best corrected visual acuity measurement, refraction, tonometry, slitlamp biomicroscopy, and dilated fundus examination. The morphology and fleshiness of pterygium were graded according to Tan et al^[13] classification before surgery. In T1 (atrophic pterygium), episcleral vessels beneath the pterygium are clearly distinguishable, T3 (fleshy pterygium) is a thick pterygium in which episcleral vessels are totally obscured by fibrovascular tissue of the body of pterygium [Figure 1a] and grade T2 (intermediate) is a pterygium between grades T1 and T3 with partially obscured episcleral vessels. All patients who underwent surgery had primary or recurrent pterygia which had invaded the cornea >2 mm from the limbus. As recurrences mostly occur in the first 6 months after surgery,^[14-16] we did not include patients with less than 6 months' follow-up. All data were entered into a standardized computerized database. The analyzed included data demographic characteristics, clinical examination findings prior to and after surgical intervention. Recurrence was defined as an ≥ 1 mm

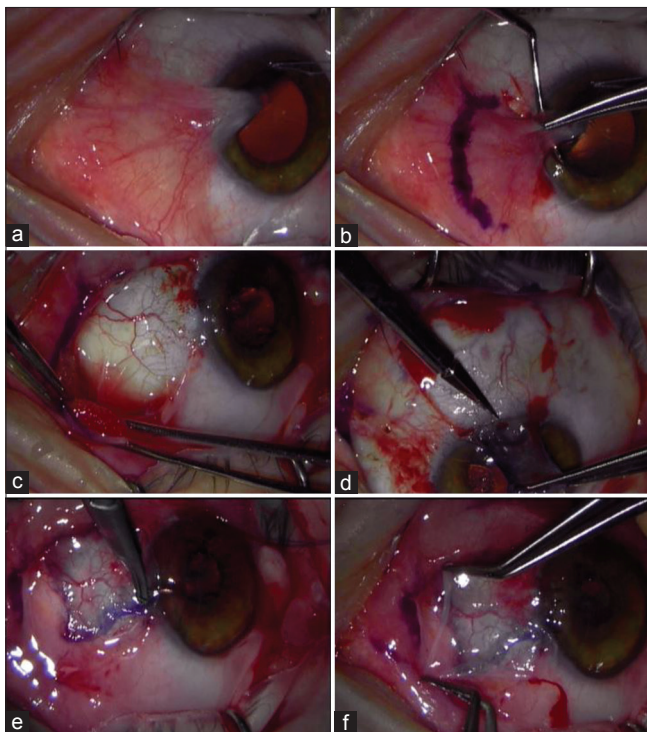


Figure 1. (a) Preoperative slit lamp photo of a case with grade T3, recurrent pterygium. (b) Blunt avulsion of the pterygium head (c) Application of mitomycin-C 0.04% under the conjunctival edges. (d) Meticulous dissection of conjunctival autograft from superotemporal conjunctiva. (e) Conjunctival autograft was attached to the sclera bed with fibrin glue and was secured with three 10-0 nylon sutures at the limbus. (f) Amniotic membrane transplantation was glued and cover the denuded cornea and the conjunctival autograft.

fibrovascular growth over the peripheral cornea. All patients were visited prior to surgery and thereafter on day 1 and 1 week, 1 month, 3 months, 6 months followed by every 6 months after surgery.

Surgical Technique

All surgeries were performed by the same surgeon (VLP). Local anesthesia (subconjunctival injection of 4% lidocaine containing 1:100,000 epinephrine) was used for all patients. For better exposure during surgery, an 8-0 silk double-armed traction suture was placed in the peripheral cornea at 3 and 9 o'clock. The head of pterygium was pulled off by the blunt muscle hook, and then the body was excised 1-2 mm in front of semilunaris fold [Figure 1b]. The subconjunctival fibrovascular tissue over the sclera, just within exposed area, was removed by scissors and the cornea was polished. Minimal cauterization was applied during surgery. In case of recurrence, mitomycin-C 0.04% was applied under the conjunctival edges by using soaked surgical sponge for 2 minutes [Figure 1c]. Thereafter, the eye surface was irrigated thoroughly with 100 ml balance salt solution, the bare sclera was measured with caliper and then, a same sized conjunctival graft was harvested from the superotemporal or infranasal (if superotemporal conjunctiva was scarified due to previous surgery) bulbar conjunctiva after subconjunctival injection of anesthetic. Meticulous dissection was done around the limbus to harvest conjunctiva completely without damaging the limbus [Figure 1d]. This graft was then placed on the bare sclera and was oriented in the way that the limbal side in the graft remained limbal. After the bare scleral area was dried with a cellulose sponge, the graft was attached to the scleral bed using EVICEL fibrin sealant (Johnson and Johnson Wound Management, Ethicon Inc., USA). The gap between the sclera and conjunctival graft was closed carefully and then, the edge of the conjunctival graft and surrounding conjunctiva were fixed together by pinching. In addition, the graft was secured at the limbus using 2-3 interrupted 10-0 nylon sutures which were buried [Figure 1e]. After proper clot formation and attachment, the surface area of the graft and de-epithelialized cornea were dried again and covered with AM patch secured with fibrin glue using the flip-over technique. The fibrin glue underneath the graft was spread with a muscle hook to avoid wrinkling. The excess AM was trimmed to properly cover de-epithelialized cornea and conjunctival graft 1 mm beyond the edge [Figure 1f].

At the end of surgery, a 16 mm Kontur bandage contact lens (Kontur Contact Lens Co., Hercules, USA) was placed. On postoperative day 1, all patients received an identical regimen of Vigamox (moxifloxacin 0.5%, Alcon Laboratories, Inc., Fort Worth, USA) for 1 week and tapering Pred Forte drop (prednisolone acetate 1%, Alergan, Inc., Irvine, USA) for 12 weeks. The contact

lens and sutures were removed 1 month after surgery [Figure 2a and 2b].

RESULTS

A total of 19 eyes of 19 patients including 12 male and 7 female subjects with 14 primary and 5 recurrent pterygia were included in the study. Mean age was 44.21 ± 12.49 (range, 29.0-73.0) years. Eight (42%) cases were Hispanic and 11 patients were Caucasian. Mean follow-up duration was 17.21 ± 6.70 (range, 10.0-35.0; median, 16.0) months. Six pterygia were graded as T3, four cases classified as T2 and the others were in grade T1.

No complication developed during the surgeries. No conjunctival autograft detachment or wound dehiscence was observed after surgery and AMT was completely dissolved 2-4 weeks after operation. Bandage contact lens was well-tolerated in all patients without any complication. We observed delayed epithelial healing in one patient with history of laser-assisted *in situ* keratomileusis on

postoperative-day 7, which healed completely in the second week. One patient developed intraocular pressure rise due to topical steroid, which resolved after stopping the drop. We did not observe any case of pyogenic granuloma formation during the follow-up visits.

We had one case (5.2%) of pterygium recurrence (1 mm fibrovascular growth over the cornea) 13 months after surgery in a 67-year-old lady who was operated for a T3 primary pterygium. Table 1 shows the demographics, grading, complications, and the recurrence of pterygium in our cases.

DISCUSSION

An ideal pterygium surgery has no complication. It is safe and effective with zero recurrence rate and perfect cosmesis. However as recurrence is the main complication, the various technique and strategies for treatment of pterygium have focused on reducing the recurrence rate.

Although several surgical techniques have been described over the decades, conjunctival autograft and AMT have gained worldwide acceptance for treatment of pterygium.^[17] Some studies showed the advantages of conjunctival autograft over AMT in terms of inflammation, cosmesis and recurrence rate.^[4,14,18,19]

The first reported use of fetal membrane, including both amnion and chorion in ophthalmology was by de Rotth in 1940.^[20] He used it as a graft for conjunctival surface

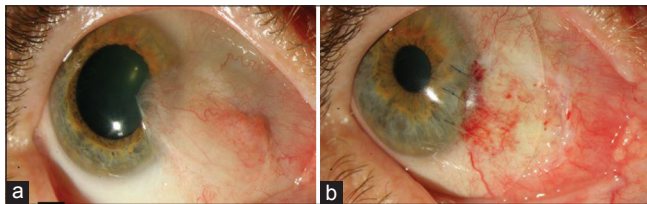


Figure 2. (a) Appearance on the 1st postoperative day, (b) slit photo 1 day after surgery.

Table 1: Clinical description and outcome of the surgery in pterygium cases.

Case	Age	Gender	Grading	Primary/recurrent	MMC	Follow-up (months)	Intraoperatively or postoperative complication	Recurrent
1	49	F	T1	Primary	-	35	-	-
2	33	M	T2	Primary	-	28	IOP rise secondary to steroid	-
3	42	F	T2	Recurrent (2 times)	+	11	-	-
4	47	M	T1	Recurrent (3 times)	+	14	-	-
5	40	F	T1	Primary	-	16	-	-
6	34	F	T2	Primary	-	13	-	-
7	61	M	T3	Primary	-	16	-	-
8	33	M	T1	Primary	-	13	-	-
9	67	F	T3	Primary	-	13	-	+
10	29	F	T3	Primary	-	20	-	-
11	47	M	T2	Primary	-	12	-	-
12	32	M	T2	Primary	-	13	Delayed epithelial healing (resolved on POD 14)	-
13	35	M	T1	Primary	-	21	-	-
14	38	M	T3	Recurrent	+	16	-	-
15	58	M	T3	Recurrent (2 times)	+	26	-	-
16	73	M	T2	Primary	-	23	-	-
17	37	M	T3	Recurrent	+	16	-	-
18	40	F	T1	Primary	-	11	-	-
19	45	M	T2	Primary	-	10	-	-

MMC, mitomycin-C; IOP, intra-ocular pressure; POD, post-operative day

reconstruction. Fifty-five years later, Kim and Tseng^[4] reported the successful use of AMT for ocular surface reconstruction in rabbits with limbal stem cell deficiency.^[21]

AM has several biological properties, including anti-angiogenic, anti-inflammatory and antiscarification.^[4,7,17] It could suppress scar formation by surgically activated conjunctival fibroblasts and promote the growth and differentiation of conjunctival epithelial cell.^[4]

Inflammation, vascularization and scar formation are the main processes involved in recurrence, therefore use of AMT in combination with conjunctival autograft might suppress these processes and reduce recurrence. AMT alone has been used for pterygium treatment for a long time, but in Medline search, we just found one study regarding combined use of conjunctival autograft and AMT by Shimazaki et al^[22] They reported a good result (15% of recurrence rate) for combined inlay AMT with partial conjunctival autograft in patients with recurrent pterygium.

In our study, we use overlay AMT and large-diameter bandage contact lens to cover the postsurgically inflamed ocular surface. Studies documented that sutured or sutureless overlay AMT is a safe and effective method to promote healing, reduce inflammation and improve visual outcomes after ocular surface reconstruction.^[7,23]

In addition to the traditional concept regarding AMT roles and benefits, we think that friction of lids over the cornea and conjunctival wound could simulate healing process which may increase the risk of recurrence. Furthermore, the mechanical-friction between the lid and the edge of the autograft might cause wound dehiscence which may promote inflammatory-healing processes and damage ocular surface and tear film integrity.

In general, wound healing could be considered as an inflammatory process in its earlier phase.^[24,25] Recent advances in cell biology and biomechanics have helped us understand the role of mechanical forces in inflammation and wound healing.

In vitro studies have indicated that mechanical and friction forces can modulate inflammatory processes. It has been proven that friction force induces chronic inflammation and T-cell-regulated fibrogenic pathway is highly responsive to mechanical force.^[9-11] Aarabi et al have shown that mechanical loading early in the wound healing process produces hypertrophic scars by preventing cellular apoptosis.^[12] The association between mechanical-friction force and wound healing process has received considerable attention by the clinicians in the past two decades. Dermatologists use silicon cushion and sheet for treatment of mature keloid scar.^[26] Although this topic is relatively new in the field of ophthalmology, there are some examples for mechanical and friction role in ocular surface inflammation. Wilson and Ostler^[27] have proposed a mechanical hypothesis for superior limbic keratoconjunctivitis (SLK) leading to chronic inflammation and scar formation. Supporting

this hypothesis, The fitting of large-diameter contact lens and injection of Botulinum toxin to the Riolan muscle to reduce the friction, has successfully treated SLK.^[28]

Based on research findings and clinical observations, if we could reduce friction over the ocular surface during early postoperative period, less inflammation and scar formation may occur which both have significant roles in pterygium recurrence. In the current study, to reduce reduce friction-induced inflammation after pterygium surgery, we used AMT which also provides an anti-inflammatory environment and promotes epithelialization. We also used the contact lens to cover the cornea and conjunctiva during the early postoperative period. Several studies showed the therapeutic role of bandage contact lens in the vast range of ocular surface diseases.^[29-33] Recently, the use of large-diameter therapeutic contact lenses is increasing. They are widely used after keratoprosthesis and also for the treatment of some ocular surface diseases in which the anatomical condition does not allow the effective fitting of regular bandage contact lens (e.g. peripheral delen formation and superior limbic keratopathy).^[28,34,35] Based on our friction hypothesis, we used large-diameter contact lens, which could adequately fit over the edematous conjunctival graft and reduce friction force on surgically damaged cornea and conjunctiva.

Although to confirm the advantages of this method over conjunctival autograft or AMT alone, we need a prospective randomized clinical trial, some characteristics of this case series might show the beneficial effects of this combined method. Overall recurrence rates for case series on mixed primary and recurrent pterygium, which were treated with conjunctival autograft had been reported between 5% and 39%, respectively.^[14,16,22,36,37] When recurrent pterygium cases were studied separately, recurrence rates were found to be between 13% and 31%.^[16,38] In a prospective study, Prabhasawat et al, have reported a 37% recurrence rate following excision with AMT, which was almost 4 times higher than the 9% recurrence rate after conjunctival autograft.^[39] We found a low recurrence rate (5.2%) for our technique in an area within the "pterygium belt" in which sun exposure level is high and pterygium is common (South Florida).^[40] It was also documented that lower patient age is associated with significantly high risk of recurrence.^[37] Chen et al^[37] have reported high rate of recurrence (50%) in patients younger than 50 years. In present case series, as the mean and the median of age in our cases were 44.2 and 40 years, we could expect higher recurrence rate. Moreover, 26.3% of our patients had recurrent pterygium increased the risk of recurrence which is consistent with other studies.^[14,16,22,36,37] However, the recurrence rate in this study could compare very favorably with recurrence rates reported in other studies with mixed primary and recurrent pterygium.^[14,16,22,36-38] This might be due to combined autograft and overlay AMT.

In summary, we observed that combined overlay AMT with conjunctival autograft is a safe and effective surgical technique for treatment of pterygium. Reducing wound friction during the postoperative period might decrease recurrence rate after pterygium surgery. We suggest a prospective randomized clinical trial to elucidate the advantages of combined overlay AMT and conjunctival autograft over each of the methods alone.

REFERENCES

- Ang LP, Chua JL, Tan DT. Current concepts and techniques in pterygium treatment. *Curr Opin Ophthalmol* 2007;18:308-313.
- Hirst LW. The treatment of pterygium. *Surv Ophthalmol* 2003;48:145-180.
- Tekin NF, Kaynak S, Saatci AO, Cingil G. Preserved human amniotic membrane transplantation in the treatment of primary pterygium. *Ophthalmic Surg Lasers* 2001;32:464-469.
- Ti SE, Tseng SC. Management of primary and recurrent pterygium using amniotic membrane transplantation. *Curr Opin Ophthalmol* 2002;13:204-212.
- Lewallen S. A randomized trial of conjunctival autografting for pterygium in the tropics. *Ophthalmology* 1989;96:1612-1614.
- Li M, Zhu M, Yu Y, Gong L, Zhao N, Robitaille MJ. Comparison of conjunctival autograft transplantation and amniotic membrane transplantation for pterygium: A meta-analysis. *Graefes Arch Clin Exp Ophthalmol* 2012;250:375-381.
- Dua HS, Gomes JA, King AJ, Maharajan VS. The amniotic membrane in ophthalmology. *Surv Ophthalmol* 2004;49:51-77.
- Meller D, Tseng SC. Conjunctival epithelial cell differentiation on amniotic membrane. *Invest Ophthalmol Vis Sci* 1999;40:878-886.
- Wong VW, Paterno J, Sorkin M, Glotzbach JP, Levi K, Januszyk M, et al. Mechanical force prolongs acute inflammation via T-cell-dependent pathways during scar formation. *FASEB J* 2011;25:4498-4510.
- Ferretti M, Gassner R, Wang Z, Perera P, Deschner J, Sowa G, et al. Biomechanical signals suppress proinflammatory responses in cartilage: Early events in experimental antigen-induced arthritis. *J Immunol* 2006;177:8757-8766.
- Chatzizisis YS, Coskun AU, Jonas M, Edelman ER, Feldman CL, Stone PH. Role of endothelial shear stress in the natural history of coronary atherosclerosis and vascular remodeling: Molecular, cellular, and vascular behavior. *J Am Coll Cardiol* 2007;49:2379-2393.
- Aarabi S, Bhatt KA, Shi Y, Paterno J, Chang EI, Loh SA, et al. Mechanical load initiates hypertrophic scar formation through decreased cellular apoptosis. *FASEB J* 2007;21:3250-3261.
- Tan DT, Chee SP, Dear KB, Lim AS. Effect of pterygium morphology on pterygium recurrence in a controlled trial comparing conjunctival autografting with bare sclera excision. *Arch Ophthalmol* 1997;115:1235-1240.
- Ozkurt YB, Kocams O, Comez AT, Uslu B, Dogan OK. Treatment of primary pterygium. *Optom Vis Sci* 2009;86:1178-1181.
- Tanaka A, Chikama T, Harada D, Kawamoto K, Yamada N, Morishige N, et al. Outcome of conjunctival autograft with amniotic membrane transplantation for recurrent pterygium. *Nihon Ganka Gakkai Zasshi* 2011;115:386-390.
- Ti SE, Chee SP, Dear KB, Tan DT. Analysis of variation in success rates in conjunctival autografting for primary and recurrent pterygium. *Br J Ophthalmol* 2000;84:385-389.
- Tseng SC. Amniotic membrane transplantation for ocular surface reconstruction. *Biosci Rep* 2001;21:481-489.
- Kheirkhah A, Nazari R, Nikdel M, Ghassemi H, Hashemi H, Behrouz MJ. Postoperative conjunctival inflammation after pterygium surgery with amniotic membrane transplantation versus conjunctival autograft. *Am J Ophthalmol* 2011;152:733-8.
- McLean C. Pterygium excision with conjunctival autografting. *Br J Ophthalmol* 1994;78:421.
- de Roth A. Plastic repair of conjunctival defects with fetal membranes. *Arch Ophthalmol Chic* 1940;23:522-525.
- Kim JC, Tseng SC. Transplantation of preserved human amniotic membrane for surface reconstruction in severely damaged rabbit corneas. *Cornea* 1995;14:473-484.
- Shimazaki J, Kosaka K, Shimmura S, Tsubota K. Amniotic membrane transplantation with conjunctival autograft for recurrent pterygium. *Ophthalmology* 2003;110:119-124.
- Pachigolla G, Prasher P, Di Pascuale MA, McCulley JP, McHenry JG, Mootha VV. Evaluation of the role of ProKera in the management of ocular surface and orbital disorders. *Eye Contact Lens* 2009;35:172-175.
- Cordeiro MF, Chang L, Lim KS, Daniels JT, Pleass RD, Siriwardena D, et al. Modulating conjunctival wound healing. *Eye (Lond)* 2000;14:536-547.
- Chang MR, Cheng Q, Lee DA. Basic science and clinical aspects of wound healing in glaucoma filtering surgery. *J Ocul Pharmacol Ther* 1998;14:75-95.
- Berman B, Flores F. Comparison of a silicone gel-filled cushion and silicon gel sheeting for the treatment of hypertrophic or keloid scars. *Dermatol Surg* 1999;25:484-486.
- Wilson FM 2nd, Ostler HB. Superior limbic keratoconjunctivitis. *Int Ophthalmol Clin* 1986;26:99-112.
- Chun YS, Kim JC. Treatment of superior limbic keratoconjunctivitis with a large-diameter contact lens and Botulium Toxin A. *Cornea* 2009;28:752-758.
- Blackmore SJ. The use of contact lenses in the treatment of persistent epithelial defects. *Cont Lens Anterior Eye* 2010;33:239-44.
- Fraunfelder FW, Cabezas M. Treatment of recurrent corneal erosion by extended-wear bandage contact lens. *Cornea* 2011;30:164-166.
- Sekundo W, Dick HB, Meyer CH. Benefits and side effects of bandage soft contact lens application after LASIK: A prospective randomized study. *Ophthalmology* 2005;112:2180-2183.
- Sulewski ME, Kracher GP, Gottsch JD, Stark WJ. Use of the disposable contact lens as a bandage contact lens. *Arch Ophthalmol* 1991;109:318.
- Donnenfeld ED, Selkin BA, Perry HD, Moadel K, Selkin GT, Cohen AJ, et al. Controlled evaluation of a bandage contact lens and a topical nonsteroidal anti-inflammatory drug in treating traumatic corneal abrasions. *Ophthalmology* 1995;102:979-984.
- Harissi-Dagher M, Beyer J, Dohlman CH. The role of soft contact lenses as an adjunct to the Boston keratoprosthesis. *Int Ophthalmol Clin* 2008;48:43-51.
- Kymionis GD, Plaka A, Kontadakis GA, Astyrakakis N. Treatment of corneal dellen with a large diameter soft contact lens. *Cont Lens Anterior Eye* 2011;34:290-292.
- Kmiha N, Kamoun B, Trigui A, Jelliti B, Fourati M, Chaabouni M. Effectiveness of conjunctival autograft transplantation in pterygium surgery. *J Fr Optalmol* 2001;24:729-732.
- Chen PP, Ariyasu RG, Kaza V, LaBree LD, McDonnell PJ. A randomized trial comparing mitomycin C and conjunctival autograft after excision of primary pterygium. *Am J Ophthalmol* 1995;120:151-160.
- Altıparmak UE, Katircioğlu YA, Yağci R, Yalın Z, Duman S. Mitomycin C and conjunctival autograft for recurrent pterygium. *Int Ophthalmol* 2007;27:339-343.
- Prabhasawat P, Barton K, Burkett G, Tseng SC. Comparison of conjunctival autografts, amniotic membrane grafts, and primary closure for pterygium excision. *Ophthalmology* 1997;104:974-985.
- Cameron ME. Pterygium Throughout The World. Springfield, Illinois: Charles C Thomas Publisher; 1965.

How to cite this article: Ghanavati SZ, Shousha MA, Betancurt C, Perez VL. Combined Conjunctival Autograft and Overlay Amniotic Membrane Transplantation; a Novel Surgical Treatment for Pterygium. *J Ophthalmic Vis Res* 2014;9:399-403.

Source of Support: ICO and Mashhad University of Medical Sciences, Mashhad, Iran. **Conflict of Interest:** None declared.