Efficacy and safety of endoscopic ultrasonography-guided ethanol injections of small pancreatic neuroendocrine neoplasms: a prospective multicenter study

OPEN ACCESS

GRAPHICAL ABSTRACT

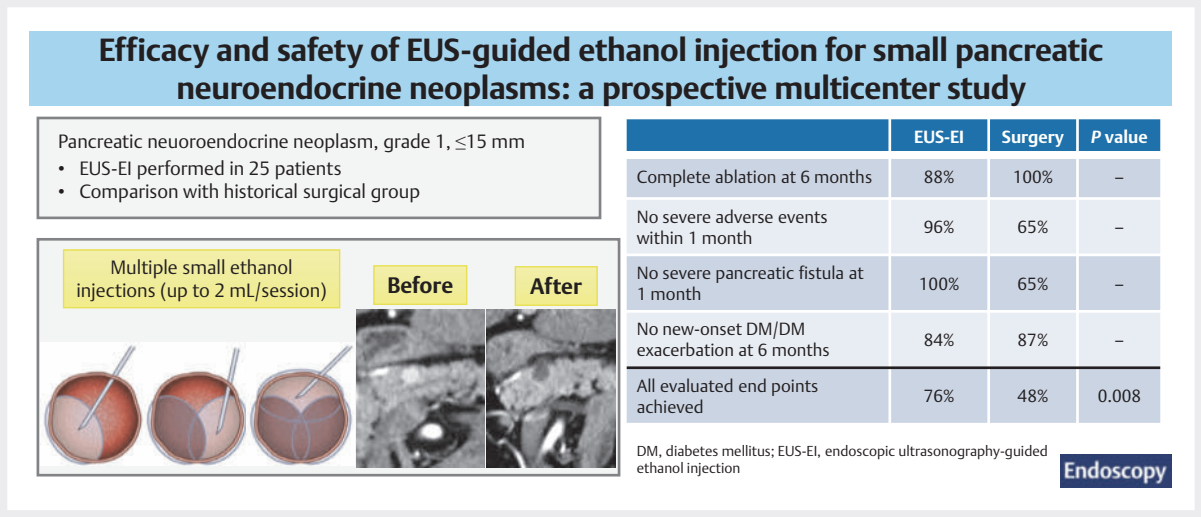

Authors

Kazuyuki Matsumoto[1], Hironari Kato[1], Takao Itoi[2], Masayuki Kitano[3], Kazuo Hara[4], Masaki Kuwatani[5], Mamoru Takenaka[6], Reiko Ashida[3], Shuntaro Mukai[2], Nozomi Okuno[4], Kazumichi Kawakubo[5], Tatsuhiro Yamazaki[1], Jun Sakurai[7], Yuki Nakatsuka[7], Michihiro Yoshida[7], Motoyuki Otsuka[1]

Institutions

1 Gastroenterology and Hepatology, Okayama University Hospital, Okayama, Japan
2 Gastroenterology and Hepatology, Tokyo Medical University, Tokyo, Japan
3 Second Department of Internal Medicine, Wakayama Medical University, Wakayama, Japan
4 Gastroenterology, Aichi Cancer Center Hospital, Nagoya, Japan
5 Gastroenterology and Hepatology, Hokkaido University Hospital, Hokkaido, Japan
6 Gastroenterology and Hepatology, Kindai University Faculty of Medicine Graduate School of Medical Sciences, Osakasayama, Japan
7 Center for Innovative Clinical Medicine, Okayama University Hospital, Okayama, Japan

received 27.1.2024
accepted after revision 24.10.2024
accepted manuscript online 25.10.2024
published online 17.1.2025

Bibliography

Endoscopy 2025; 57: 321–329
DOI 10.1055/a-2452-4607
ISSN 0013-726X
© 2025. The Author(s).
This is an open access article published by Thieme under the terms of the Creative Commons Attribution-NonDerivative-NonCommercial License, permitting copying and reproduction so long as the original work is given appropriate credit. Contents may not be used for commercial purposes, or adapted, remixed, transformed or built upon. (https://creativecommons.org/licenses/by-nc-nd/4.0/)
Georg Thieme Verlag KG, Oswald-Hesse-Straße 50, 70469 Stuttgart, Germany

Corresponding author

Supplementary Material
Supplementary Material is available at https://doi.org/10.1055/a-2452-4607

Hironari Kato, MD, PhD, Department of Gastroenterology and Hepatology, Okayama University Hospital, 2-5-1 Shikata-cho, Okayama 700-8558, Japan
drkatocha@yahoo.co.jp

ABSTRACT

Background Endoscopic ultrasonography (EUS)-guided ethanol injection (EI) has recently been introduced as one of the management strategies for pancreatic neuroendocrine neoplasms (PNENs); however, its role as a surgical alternative is unclear. We evaluated the efficacy and safety of EUS-EI in treating small PNENs through a prospective multicenter study.

Methods Patients with grade 1 tumors of ≤15 mm confirmed by pathology were included. The primary end point assessed efficacy and safety, measuring complete ablation using computed tomography at 1 and 6 months, prevention of adverse events (AEs) within 1 month, severe pancreatic fistula at 1 month, and incidence/worsening of diabetes mellitus (DM) at 6 months. The composite end point of EUS-EI was compared with that of historical results of a study based on surgical treatment.

Results 25 patients with PNENs, with a median tumor size of 10.1 mm, were treated using EUS-EI. The composite primary end point was achieved by 76.0% of patients (19/25; 95%CI 54.9%–90.6%), a proportion significantly higher than that of surgical treatment ($P = 0.008$). Regarding efficacy, 88.0% (22/25) of patients achieved complete ablation at 1 and 6 months (95%CI 68.8%–97.5%). Regarding safety, 96.0% (24/25) of patients had no severe AEs within 1 month (95%CI 79.7%–99.9%). No patients had severe pancreatic fistulas at 1 month, and 84.0% (21/25) had no incidence or exacerbation, or both, of DM at 6 months (95%CI 63.9%–95.5%).

Conclusion EUS-EI is safe and could be a potent treatment option for patients with small PNENs.

Introduction

Pancreatic neuroendocrine neoplasms (PNENs) are rare, accounting for 1%–2% of primary pancreatic malignancies [1]; however, their incidence has increased substantially owing to the widespread use of advanced endoscopic and radiological imaging techniques [2].

Treatment options for PNENs depend on hormone-related symptoms and tumor size [3, 4]. Specifically, surgical resection is usually performed in patients with symptomatic disease or tumors >2 cm in diameter; however, the optimal treatment approach for patients with small nonfunctional low grade PNENs (≤2 cm in diameter) remains controversial. The complication rate of pancreatic surgery is higher than that of other gastrointestinal surgeries. Additionally, decreased pancreatic endocrine and exocrine function may occur after pancreatic resection. Therefore, the benefits of surgery must be balanced against the potential postoperative complications [3, 4, 5].

When treating PNENs, a watch-and-wait approach is generally chosen for small-sized low grade malignant tumors [3, 4]. A recent study of patients with nonfunctional small pancreatic endocrine tumors (PNETs) who underwent surgical resection reported a similar 5-year cancer-specific survival to those who were under observation [4]; however, uncertainty remains over the prognosis after 5 years and which small-sized tumors are likely to grow in the future. Furthermore, opting for surveillance in a wait-and-watch approach requires annual contrast-enhanced examinations, potentially raising concerns related to allergies to contrast media, renal dysfunction, and radiation exposure.

Recently, advances in endoscopic ultrasonography (EUS)-guided ablative techniques have enabled a possible alternative to surgical resection. The advantages of the EUS-guided local ablation therapy include reduced complications and preserved pancreatic function. The two most commonly described techniques are radiofrequency ablation (RFA) and ethanol injection [6, 7, 8, 9, 10, 11, 12, 13, 14, 15, 16, 17, 18, 19, 20, 21, 22]. EUS-guided ethanol injection (EUS-EI), which involves direct injection of ethanol into a tumor to induce coagulation necrosis, was reported in 2006 [16]; however, most related studies have been single-center retrospective studies. Therefore, we planned a multicenter single-arm prospective study to evaluate the efficacy and safety of EUS-EI for small, low grade PNENs.

Methods

Study design and participants

This multicenter single-arm prospective study was conducted at six high volume medical centers in Japan between September 2020 and July 2023. ▶ **Fig. 1** shows a flow diagram of patient enrolment and the study's protocol overview. The eligibility criteria included: (i) age 20–75 years; (ii) provision of informed consent; (iii) grade 1 PNEN diagnosed pathologically using EUS-guided fine-needle aspiration (FNA) specimens (World Health Organisation 2017 classification); (iv) well enhanced tumor (diameter, ≤15 mm) in the arterial phase on contrast-enhanced computed tomography (CECT); and (v) PNEN diagnosed as a nonfunctional tumor or insulinoma. The exclusion criteria included: (i) allergy to contrast media or ethanol; (ii) distance between the tumor and main pancreatic duct of ≤2 mm; (iii) administration of two or more antithrombotic agents; and (iv) poor prognosis (<5 years) predicted, as described in the protocol article [23].

Written informed consent was obtained from all patients before initiation of the procedures. The study protocol was approved by the Okayama University Certified Review Board (CRB19–007) and followed the principles of the Declaration of Helsinki. Monitoring and auditing were conducted during the trial. We also established an independent data monitoring committee comprising three additional doctors (R.Y., R.H., and M. F.) who were not associated with the study to determine whether the study should continue if severe adverse events (AEs)

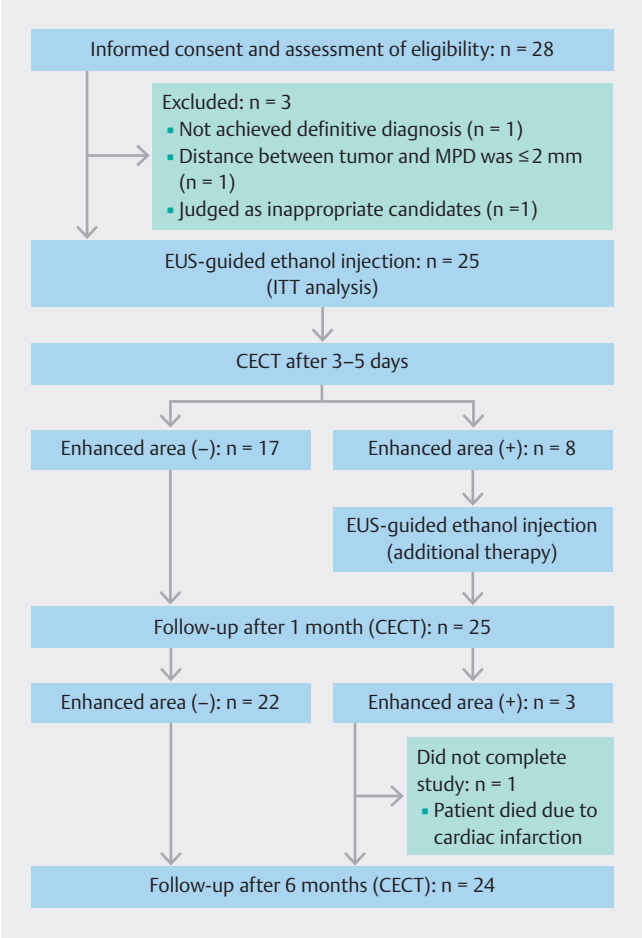

▶ **Fig. 1** Flowchart of the study. CECT, contrast-enhanced computed tomography; EUS, endoscopic ultrasonography; ITT, intention-to-treat.

occurred. All authors had access to the study data and reviewed and approved the final manuscript.

End points

Primary end point

To clarify the rationale to be presented in the Japanese regulatory submission, the primary composite end point was established as the proportion of participants who achieved all of the following clinical efficacy and safety component end points: (i) efficacy, complete ablation on CECT at 1 and 6 months after treatment; and (ii) safety, (a) no severe AEs within 1 month after treatment, (b) no severe pancreatic fistula at 1 month after the treatment, and (c) no incidence or exacerbation, or both, of diabetes mellitus (DM) at 6 months after treatment.

Secondary end points

The following secondary end points were evaluated.

1 Efficacy: (a) complete ablation on CECT at 1 month after treatment, (b) complete ablation on CECT at 6 months after treatment, and (c) 6-month overall survival.

2 Safety: prevalence of (a) total AEs, (b) severe AEs within 1 month after treatment, (c) severe pancreatic fistulas at 1 month after treatment, (d) DM exacerbation at 6 months after treatment, (e) device failure, and (f) conversion to surgery.

Definitions

Complete ablation was defined as the absence of enhanced areas within the tumor on arterial-phase CECT images with a slice of 1–2 mm in thickness. Two expert gastroenterologists independently reviewed the CECT images based on the radiologist's findings. If a judgement could not be made using CECT, contrast-enhanced EUS (CE-EUS) with perflubutane (Daiichi-Sankyo Co., Ltd., Tokyo, Japan) was performed to assess the enhanced areas within the tumor.

Procedure-related AEs were evaluated based on the 2010 guideline of the American Society for Gastrointestinal Endoscopy (ASGE) [24]; other AEs were evaluated using the Common Terminology Criteria for Adverse Events (CTCAE) v. 5.0. Severe AEs were those defined as moderate or higher in the ASGE guideline and grade ≥3 in the CTCAE. Severe pancreatic fistula was defined as the continuation of any treatment for pancreatic fistula (percutaneous or endoscopic drainage tube or medication, or both) at 1 month after treatment. DM was defined as fasting or occasional blood glucose levels of 126 or 200 mg/dL, respectively, and glycated hemoglobin (HbA1c) levels of ≥6.5 (National Glycohemoglobin Standardization Program value). New-onset DM referred to a patient without DM at the time of registration; however, DM exacerbation referred to a patient who qualified as having DM at the time of registration but subsequently started or increased medication for DM owing to poor glycemic control or whose HbA1c level increased by approximately 0.2%.

Study procedure

The procedure was performed in an endoscopy room with the patients in the prone or semiprone position and under conscious sedation with an intravenous anesthetic. Before the procedure, a 50-mg diclofenac suppository was used to prevent pancreatitis. Regarding treatment, a 25-gauge FNA needle (EZ-shot 3; Olympus Medical Systems, Tokyo, Japan) filled with ethanol was advanced into the tumor under EUS guidance. Pure ethanol (100%; Mylan Seiyaku Ltd., Tokyo, Japan) was injected until a hyperechoic blush extended to the margin of the tumor edge, and the needle was kept inside the tumor for at least 1 minute to prevent ethanol backflow. The injection was initiated from the deeper tumor side on the EUS image because a spread hyperechoic blush would prevent recognition of a tumor's low echoic parts on the far side. After removing the needle, we looked for low echoic tumor parts, which, if detected, were injected with ethanol. For safety, the amount of ethanol per puncture, total number of punctures per session, and maximum volume per session were set to 1 mL, three, and 2 mL, respectively (▶ **Fig. 2**; ▶ **Video 1**; **Fig. 1s**, see online-only Supplementary material).

CECT was performed 3–5 days post-treatment to evaluate tumor viability and procedure-related AEs. If enhanced areas of the tumor were observed on the post-procedural CECT, an

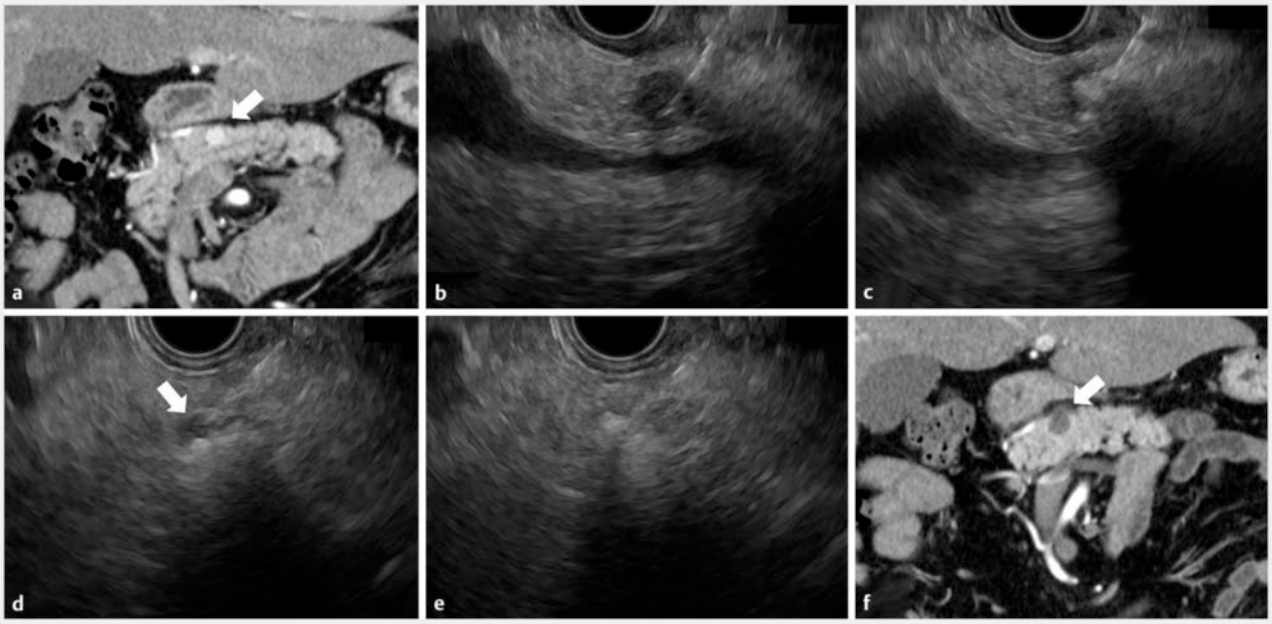

▶ **Fig. 2** Images during the endoscopic ultrasonography-guided ethanol injection procedure showing: **a** before the procedure, a well enhanced tumor measuring 10 mm located in the body of the pancreas (arrow); **b** a 25-gauge needle being inserted into the far side of the tumor; **c** ethanol being injected until the hyperechoic bubble extends to the tumor margin; **d** examination of the low echoic part of the tumor (arrow) after removal of the needle, with re-insertion of the needle into the low echoic area; **e** ethanol being injected until the hyperechoic bubble extends to the tumor margin; **f** 3 days after the procedure, no enhancing areas visible in the tumor.

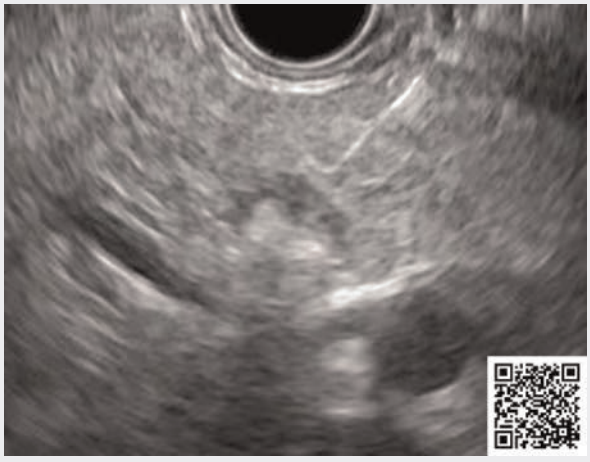

Video 1 Endoscopic ultrasonography-guided small volume ethanol injections are performed at multiple sites to treat a small pancreatic neuroendocrine neoplasm.
Online content viewable at:
https://doi.org/10.1055/a-2452-4607

additional ablation session was performed within the same hospitalization period. If it was difficult to identify the tumor's viable part on B-mode, CE-EUS was performed to locate any residual tumors [25]. The patient was discharged a day after the additional session or when no enhanced tumor areas were observed on post-procedural CECT (**Figs. 2s** and **3s**).

Follow-up

To assess the acute and subacute post-treatment course of patients with PNENs with EUS-EI in this study, patients were followed up postoperatively for 6 months. Follow-up examinations were scheduled at 1, 3, and 6 months to evaluate the patient's general condition and perform blood tests. The patients were scheduled to undergo follow-up CECT imaging at 1 and 6 months after discharge. Salvage surgical resection was suggested to the patient if incomplete ablation of the treated lesion was observed on the follow-up CECT.

Sample size calculation

Because this study was related to an orphan disease, it was designed as a single-arm study. For the interpretation of the study results, known historical results of surgical treatment in 23 patients with PNENs (diameter ≤15 mm) who underwent treatment at Okayama University Hospital between November 2007 and January 2018 were referenced (**Table 1s**). The result showed that 47.8% (11/23) of the patients met the primary end point. In our previous pilot study of EUS-EI in a similar population, 75.0% (6/8) of the patients had achieved the primary end point. Therefore, the null and alternative hypotheses were set as follows:

H_0: $P_T = 0.48$
H_1: $P_T \neq 0.48$

▶ **Table 1** Baseline characteristics of the 25 patients who underwent endoscopic ultrasonography-guided ethanol injection of a pancreatic neuroendocrine neoplasm.

	n (%), unless otherwise specified
Age, median (IQR), years	62 (52–71)
Sex, male	15 (60)
Tumor size, median (IQR), mm	10.1 (7.0–11.0)
Tumor location	
▪ Head	11 (44.0)
▪ Body	8 (32.0)
▪ Tail	6 (24.0)
Nonfunctional tumor	25 (100)
Performance status	
▪ 0	22 (88.0)
▪ 1	3 (12.0)
Presence of diabetes mellitus	8 (32.0)

IQR, interquartile range.

where P_T was the post-procedural true proportion of the primary end point. Based on the Japanese special regulation for approvals for orphan diseases, the statistical significance level was set at 10% (two-sided). The number of patients required to maintain 80% power based on an exact binomial test was 22. A sample size of 25 was planned to account for dropouts or withdrawals.

Statistical analysis

The analysis population was defined as all participants who were registered in the study and underwent the trial procedures (intention-to-treat [ITT] analysis). Continuous variables are reported as medians with interquartile ranges (IQRs) or ranges, and categorical variables as counts and percentages. Clopper–Pearson CIs were applied to the primary and secondary end points. Owing to special regulations for orphan diseases in Japan, the statistical significance level was set at 10% (two-sided); however, for scientific publication in this paper, it was planned to be set at 5% (two-sided). Subsequently, the results were interpreted based on 95%CIs, with 90%CIs described for reference purposes.

The primary analysis for the primary end point was planned to apply the exact binomial test with a null hypothesis based on historical results of surgical treatment (48%). Because of insufficient statistical precision of the result based on only 23 cases, Fisher's exact test was applied as a post-hoc additional analysis for the primary end point. The component and secondary end points were analyzed to support the clinical interpretation of the primary composite end point. The primary composite end point, component end points, and secondary end points were evaluated in cohort 1 (tumor size <10 mm) and cohort 2 (10–15 mm).

All statistical analyses were conducted by clinical statisticians (Y.N. and M.Y.) using SAS version 9.4 (SAS Institute Inc., Cary, North Carolina, USA).

Results

Study population

Of the 28 eligible patients who provided informed consent, three were excluded (no definitive diagnosis of PNEN grade 1 using EUS-FNA [n = 1], a <2-mm distance between the tumor and main pancreatic duct [n = 1], and considered to be an inappropriate candidate [n = 1]). Overall, 25 patients with nonfunctional tumors (median tumor size 10.1 mm [IQR 7.0–11.0]) were analyzed and treated with EUS-EI. After treatment, 24 patients completed the follow-up schedule, and one died from cardiac infarction 5 months after treatment. The characteristics of the enrolled patients and each cohort are shown in ▶ **Table 1** and **Table 2s**.

Primary composite and component end points

The proportion of patients who achieved the primary composite end point comprising efficacy and safety was 76.0% (19/25; 95%CI 54.9%–90.6%), which was significantly higher than that achieved in the historical surgical treatment results (47.8%; exact binomial test, $P = 0.008$) (▶ **Table 2**). Additionally, the difference in the achievement rate (EUS-EI minus surgical treatment) was 28.2 percentage points (95%CI −2.4 to 58.8 percentage points; Fisher's exact test, $P = 0.07$ on post-hoc analysis), which showed a trend similar to the primary result (**Table 3s**). **Table 4s** illustrates the primary composite end point evaluated in each cohort.

Secondary end points

The secondary end points are shown in ▶ **Table 3**. Regarding efficacy, the complete ablation rate on CECT at both 1 and 6 months was 88.0% (22/25). The 6-month overall survival rate was 96.0% (24/25); one patient died from cardiac infarction 5 months after treatment. In terms of safety, the prevalences of total and severe AEs within 1 month were 68.0% (17/25) and 4.0% (1/25), respectively. No severe pancreatic fistulas were observed at 1 month after treatment. The incidence of DM or its exacerbation at 6 months was 12.0% (3/25): new-onset DM (n = 1); worsening of pre-existing DM (n = 2). Device failure owing to needle obstruction caused by blood clots occurred in one patient (4.0%); ethanol could not be injected after the tumor had been punctured so, once the needle had been removed, it was flushed with a saline solution. None of the patients required surgery. **Table 5s** shows the evaluation of the secondary end points in each cohort.

Treatment results

Table 6s shows the treatment results. Among the 25 patients who underwent EUS-EI, 32.0% (8/25) underwent additional sessions within the same hospitalization period. The number of punctures performed in the initial session were one (n = 4;

▶ **Table 2** Details of achievement of the primary composite end point and the component end points using endoscopic ultrasonography-guided ethanol injection (EUS-EI).

	Treatment	Patients, n	End point achieved, n	6-month follow-up not completed, n[1]	End point achieved (95%CI) [90%CI][2], %	P value[3]
Primary composite end point						
Intention-to-treat analysis	EUS-EI	25	19	0	76.0 (54.9–90.6) [58.0–89.0]	0.008
	Surgery	23	11	0	47.8 (26.8–69.4) [29.6–66.5]	
Component end points: efficacy						
Complete ablation at 1 month	EUS-EI	25	22	0	88.0 (68.8–97.5) [71.8–96.6]	–
	Surgery	23	23	0	100 (85.2–100) [87.8–100]	
Complete ablation at 6 months	EUS-EI	25	22	1	88.0 (68.8–97.5) [71.8–96.6]	–
	Surgery	23	23	0	100 (85.2–100) [87.8–100]	
Component end points: safety						
Avoidance of severe adverse events within 1 month	EUS-EI	25	24	0	96.0 (79.7–99.9) [82.4–99.8]	–
	Surgery	23	15	0	65.2 (42.7–83.6) [46.0–81.4]	
Avoidance of pancreatic fistula at 1 month	EUS-EI	25	25	0	100 (86.3–100) [88.7–100]	–
	Surgery	23	15	0	65.2 (42.7–83.6) [46.0–81.4]	
Avoidance of incidence and/or exacerbation of diabetes mellitus at 6 months	EUS-EI	25	21	1	84.0 (63.9–95.5) [67.0–94.3]	–
	Surgery	23	20	0	87.0 (66.4–97.2) [69.6–96.4]	

[1] One patient died from cardiac infarction 5 months after the procedure.
[2] The two-sided 90%CI is shown as a reference because the sample size was calculated with a two-sided significance level of 10%.
[3] Exact binomial test: the null hypothesis was set using the historical results of a study based on surgical treatment.

16.0%), two (n = 12; 48.0%), or three (n = 9; 36.0%). Notably, all patients with a tumor size of 10–15 mm were treated with multiple punctures for other parts of the tumor. The median injected ethanol volume per tumor was 1.0 mL (range 0.3–3.6); the median total ethanol volumes per initial and additional session were 0.9 mL (range 0.3–2.0) and 0.9 mL (range 0.3–1.6) mL, respectively. Furthermore, the median procedure time was 21.0 minutes (IQR 14.0–30.0), and the median period of hospitalization was 6 days (IQR 5–7).

Procedure-related AEs

Procedure-related AEs occurred in 60.0% (15/25) of the patients: grade 1/2, n = 14 (56.0%); grade 3, n = 1 (4.0%). Acute pancreatitis occurred in 20.0% (5/25): mild pancreatitis (n = 4); moderate pancreatitis (n = 1), which improved with conservative treatment within 7 days. Hyperamylasemia occurred in eight patients, with serum amylase levels decreasing without treatment in all cases. Sedation-induced hypotension occurred in one patient (4.0%) during the procedure; the patient experienced a rapid increase in blood pressure following rapid fluid replacement (▶ **Table 4**).

Discussion

This is the first prospective multicenter study to evaluate EUS-EI for small grade 1 PNENs. This study set a maximum amount of ethanol to be used per session to ensure safety, and an additional session was planned to optimize the complete ablation rate. Complete ablation could not be achieved in all cases with EUS-EI; however, a high rate (88%) was observed. Severe AEs occurred in only one patient (4%).

Observation of stable, small, incidentally discovered PNENs is considered reasonable for selected patients; however, the 5-year survival of such patients and the characteristics of small-

▶ **Table 3** Details of secondary end points for the 25 patients who underwent endoscopic ultrasonography-guided ethanol injection of a pancreatic neuroendocrine neoplasm.

	n (%), unless otherwise specified
Efficacy	
Complete ablation at 1 month	22 (88.0)
Complete ablation at 6 months	22 (88.0)
Overall survival at 6 months	24 (96.0)[1]
Safety	
Total adverse events	17 (68.0)
Severe adverse events within 1 month	1 (4.0)
Severe pancreatic fistula at 1 month	0 (0.0)
New-onset diabetes mellitus and/or exacerbation at 6 months	3 (12.0)
Device failure	1 (4.0)
Conversion to surgery	0 (0.0)

[1] One patient died from cardiac infarction 5 months after treatment.

▶ **Table 4** Procedure-related adverse events[1] (results are shown as number of patients [%]).

	Any grade	Grade 1 or 2	Grade 3 or 4
Total adverse events	15 (60.0)	14 (56.0)	1 (4.0)
Post-procedural adverse events			
▪ Hyper-amylasemia	8 (32.0)	8 (32.0)	0 (0.0)
▪ Pancreatitis	5 (20.0)	4 (16.0)	1 (4.0)
▪ Nausea	1 (4.0)	1 (4.0)	0 (0.0)
▪ Abdominal pain	1 (4.0)	1 (4.0)	0 (0.0)
▪ Vomiting	1 (4.0)	1 (4.0)	0 (0.0)
Intraprocedural adverse events			
▪ Hypotension	1 (4.0)	1 (4.0)	0 (0.0)
▪ Needle obstruction	1 (4.0)	1 (4.0)	0 (0.0)

[1] Procedure-related adverse events were evaluated based on the American Society for Gastrointestinal Endoscopy (ASGE) guideline 2010; other adverse events were assessed based on Common Terminology Criteria for Adverse Events (CTCAE) v. 5.0.

sized tumors that may subsequently grow remain undetermined [4]. Regarding tumor size, previous reports on lymph node metastasis indicated an increased risk with tumors sized >15 mm [26]. A recent international study reported that an unfavorable prognosis for nonfunctional small PNETs was related to a tumor size of >15 mm, Ki-67 index of >3%, and nodal metastasis [27]. Therefore, a tumor size <15 mm was considered appropriate for local endoscopic treatments with curative intent.

EUS-EI and RFA have recently been performed for small PNENs. A recent meta-analysis including 181 patients (100 EUS-RFA, 81 EUS-EI) with PNETs (mean size 15.1 mm [SD 4.7]) reported no significant differences in the rates of technical success (94.4% vs. 96.7%; $P = 0.42$), clinical success (85.2 vs. 82.2%; $P = 0.65$), and AEs (14.1% vs. 11.5%; $P = 0.70$) between EUS-RFA and EUS-EI, respectively [28]; however, the included reports studied only nonfunctional PNENs and the complete ablation rate for EUS-EI (60%–80%) was lower than that for EUS-RFA (86%–100%) [18].

While in this study the complete ablation rate was 64.0% (16/25) in a single session, consistent with that reported previously, we planned an additional session for patients with an insufficient response [8]. As a result, the complete ablation rate increased to 88.0% (22/25). During the additional sessions, CE-EUS was conducted for patients in whom identifying residual tumors with B-mode was challenging [25]. Notably, among eight patients who received additional treatment, CE-EUS was performed in six (75%), and complete ablation was achieved in four (50%).

Previously reported studies assessed complete ablation on CECT at 3 months post-treatment and planned additional ethanol therapy for incomplete cases [6, 7]. We have encountered cases where surgical resection was necessary after EUS-EI. Pathological findings of the resected specimens revealed highly fibrotic changes in the ethanol-treated areas, with residual tumors surrounded by significant fibrosis [8]. This fibrosis probably prevented the spread of the injected ethanol into the residual tumor. Compared with the previous reports, higher treatment efficacy was achieved by performing additional treatment 3–5 days after the initial therapy.

Based on the tumor size, the complete ablation rates were 91.7% (11/12) and 84.6% (11/13) for tumors sized <10 and 10–15 mm, respectively. Although the results were obtained in a relatively small number of cases, EUS-EI may be sufficiently effective, particularly for tumors sized <10 mm (**Table 7s**).

The meta-analysis of EUS-RFA reported by Khoury et al. [22], including 292 patients with PNENs, reported rates of technical success of 99.2% (95%CI 97.9%–99.9%), complete radiological response of 87.1% (95%CI 80.1%–92.8%), and AEs of 20.0% (95%CI 14.0%–26.7%), while the severe AE incidence was 0.9% (95%CI 0.2%–2.3%). The most common AEs were transient mild abdominal pain (n = 19; 6.5%), and mild-to-moderate pancreatitis (n = 23; 7.9%). In their report, complete ablation was associated with the power setting of RFA system. A power setting of <50 W achieved complete ablation in 92.4% of cases, while 50 W achieved complete ablation in 84.6%. In RFA treatment, using a lower power for ablation results in longer ablation times and broader ablation areas compared with higher powers [29]. Consequently, there is a possibility of the heat effect spreading to the peripancreatic area, potentially leading to complications. In RFA treatment, there have been reports of complications, such as pancreatic necrosis, bleeding of the gas-

trointestinal wall, or death [19, 20, 21], which are not typically experienced with EUS-EI.

Regarding safety, only one patient had moderate pancreatitis, which improved with conservative treatment. Among the five patients with pancreatitis after EUS-EI and the 20 without pancreatitis, the median total ethanol volumes injected were 1.4 mL and 1.0 mL, respectively, suggesting a higher ethanol volume was injected in the patients with pancreatitis. Moderate pancreatitis occurred one patient, who had 2.0 mL of ethanol injected in the initial session (**Table 8s**). The ethanol volume/session is associated with pancreatitis; therefore it should be minimized a much as possible.

A study on the surgical resection of benign pancreatic tumors revealed that the morbidity rates for pancreaticoduodenectomy, distal pancreatectomy, and parenchyma-preserving resection were 52%, 47%, and 44%, respectively [5]. In a recent study comparing the treatment results of EUS-RFA and surgical treatment for pancreatic insulinoma, the surgical resection morbidity and severe AE rates were 61.8% (55/89) and 15.8% [30]. These data are similar to the historical results of surgical treatment referred to in this study. Furthermore, in pancreaticoduodenectomy and distal pancreatectomy, which involve extensive resection of the pancreas, postoperative complications including DM and impaired nutrient absorption occurred in 14%–18% and 17%–33% of cases, respectively [5, 31]. The incidence of newly developed DM was 4.0% (1/25) in this study, with EUS-EI essentially preserving pancreatic function. With EUS-EI, serious AEs and pancreatic fistulas occurred within 1 month in 1/25 and 0/25 patients, respectively; with surgical treatment, both occurred in 15/23 patients, meaning EUS-EI offers a significant improvement in the primary composite end point.

This study has some limitations. First, it was designed as a multicenter single-arm prospective study rather than a randomized controlled trial (RCT) but, given the limited number of potentially eligible patients, it would be difficult to conduct a larger RCT with adequate statistical power.

Second, we referred to the results of a historical surgical treatment study of limited sized for the primary end point analysis. Owing to the insufficient statistical precision of the reference, we performed post-hoc additional analyses. The difference in the achievement rates between EUS-EI and surgical treatments was 28.2 percentage points (95%CI −2.4 to 58.8 percentage points; Fisher's exact test, $P = 0.07$). Although this did not reach statistical significance, the 95%CI showed a trend similar to the primary result. Because the distribution of patient characteristics was not balanced between EUS-EI in this study and the previous surgical resection study, a logistic regression model was additionally applied to the primary end point, incorporating treatment procedures (surgical resection/EUS-EI) as an independent variable, and function/nonfunction and tumor size (<10/10–15 mm) as covariates. This revealed an odds ratio (OR) for the treatment procedures of 4.0 (95%CI 0.9–17.0; $P = 0.06$), which was similar to the main results of this study.

Third, because we planned a 6-month follow-up period after treatment to assess the acute and subacute course of patients with PNEN post-treatment with EUS-EI, the follow-up period was inadequate to evaluate tumor recurrence. The study of So et al. on long-term treatment outcomes of EUS-EI for small PNENs (mean tumor size 12.1 mm [SD 3.6]) revealed that, of the 97 patients treated with EUS-EI, 63 (65%) showed complete ablation [17]. During follow-up, 29 patients (46.0%) showed local recurrence after complete ablation. The median duration from the first session to recurrence was 34.5 months. Therefore, a long-term follow-up period of at least 5 years is required to prove the efficacy of EUS-EI. We have already initiated a long-term prospective observational study involving patients who participated in this study to assess future treatment outcomes (UMIN000044094).

In conclusion, EUS-EI appears safe, effective, and minimally invasive for the treatment of small PNENs. Therefore, in addition to surgical treatment or observation, it could be considered an optimal treatment option for small PNENs.

Acknowledgement

We thank Dr. Ryuichi Yoshida (Department of Gastroenterological Surgery, Okayama University Hospital, Okayama, Japan), Dr. Ryo Harada (Department of Gastroenterology, Japanese Red Cross Okayama Hospital, Okayama, Japan), and Dr. Masakuni Fujii (Department of Internal Medicine, Okayama Saiseikai General Hospital, Okayama, Japan) for establishing and performing independent data monitoring.

Conflict of Interest

The authors declare that they have no conflict of interest.

Funding Information

Japanese Foundation for Research and Promotion of Endoscopy
http://dx.doi.org/10.13039/100018254

Clinical Trial

Trial Registration: Japan Primary Registries Network (http://rctportal.niph.go.jp) | Registration number (trial ID): jRCTs061200016 | Type of study: Prospective, Muli-Center study, Historical control

References

[1] Yao JC, Eisner MP, Leary C et al. Population-based study of islet cell carcinoma. Ann Surg Oncol 2007; 14: 3492–3500 doi:10.1245/s10434-007-9566-6

[2] Ito T, Sasano H, Tanaka M et al. Epidemiological study of gastroenteropancreatic neuroendocrine tumors in Japan. J Gastroenterol 2010; 45: 234–243 doi:10.1007/s00535-009-0194-8

[3] Falconi M, Eriksson B, Kaltsas G et al. ENETS consensus guidelines update for the management of patients with functional pancreatic neuroendocrine tumors and non-functional pancreatic neuroendocrine tumors. Neuroendocrinology 2006; 84: 196–211

[4] Sadot E, Reidy-Lagunes DL, Tang LH et al. Observation versus resection for small asymptomatic pancreatic neuroendocrine tumors: a matched case-control study. Ann Surg Oncol 2016; 23: 1361–1370 doi:10.1245/s10434-015-4986-1

[5] Falconi M, Mantovani W, Crippa S et al. Pancreatic insufficiency after different resections for benign tumors. Br J Surg 2008; 95: 85–91

[6] Park do H, Choi JH, Oh D et al. Endoscopic ultrasonography-guided ethanol ablation for small pancreatic neuroendocrine tumors: results of a pilot study. Clin Endosc 2015; 48: 158–164 doi:10.5946/ce.2015.48.2.158

[7] Choi JF, Park DH, Kim MH et al. Outcomes after endoscopic ultrasound-guided ethanol-lipiodol ablation of small pancreatic neuroendocrine tumors. Dig Endosc 2018; 30: 652–658 doi:10.1111/den.13058

[8] Matsumoto K, Kato H, Kawano S et al. Efficacy and safety of scheduled early endoscopic ultrasonography-guided ethanol reinjection for patients with pancreatic neuroendocrine tumors: Prospective pilot study. Dig Endosc 2020; 32: 425–430

[9] Jürgensen C, Schuppan D, Neser F et al. EUS-guided alcohol ablation of an insulinoma. Gastrointest Endosc 2006; 63: 1059–1062 doi:10.1016/j.gie.2005.10.034

[10] Muscatiello N, Salcuni A, Macarini L et al. Treatment of a pancreatic endocrine tumor by ethanol injection guided by endoscopic ultrasound. Endoscopy 2008; 40: E258–E259 doi:10.1055/s-2007-995540

[11] Deprez PH, Claessens A, Borbath I et al. Successful endoscopic ultrasound-guided ethanol ablation of a sporadic insulinoma. Acta Gastroenterol Belg 2008; 71: 333–337

[12] Vleggaar FP, Bij de Vaate EA et al. Endoscopic ultrasound-guided ethanol ablation of a symptomatic sporadic insulinoma. Endoscopy 2011; 43: E328–E329

[13] Levy MJ, Thompson GB, Topazian MD et al. US-guided ethanol ablation of insulinomas: a new treatment option. Gastrointest Endosc 2012; 75: 200–206 doi:10.1016/j.gie.2011.09.019

[14] Qin SY, Lu XP, Jiang HX. EUS-guided ethanol ablation of insulinomas: case series and literature review. Medicine (Baltimore) 2014; 93: e85 doi:10.1097/MD.0000000000000085

[15] Lakhtakia S. Therapy of pancreatic neuroendocrine tumors: fine needle intervention including ethanol and radiofrequency ablation. Clin Endosc 2017; 50: 546–551 doi:10.5946/ce.2017.167

[16] Jürgensen C, Schuppan D, Neser F et al. EUS-guided alcohol ablation of an insulinoma. Gastrointest Endosc 2006; 63: 1059–1062 doi:10.1016/j.gie.2005.10.034

[17] So H, Ko SW, Shin SH et al. Comparison of EUS-guided ablation and surgical resection for nonfunctioning small pancreatic neuroendocrine tumors: a propensity score-matching study. Gastrointest Endosc 2023; 97: 741–751 doi:10.1016/j.gie.2022.11.004

[18] Matsumoto K, Kato H. Endoscopic ablation therapy for the pancreatic neoplasms. Dig Endosc 2023; 35: 430–442 doi:10.1111/den.14468

[19] Barthet M, Giovannini M, Lesavre N et al. Endoscopic ultrasound-guided radiofrequency ablation for pancreatic neuroendocrine tumors and pancreatic cystic neoplasms: a prospective multicenter study. Endoscopy 2019; 51: 836–842 doi:10.1055/a-0824-7067

[20] Marx M, Trosic-Ivanisevic T, Caillol F et al. EUS-guided radiofrequency ablation for pancreatic insulinoma: experience in 2 tertiary centers. Gastrointest Endosc 2022; 95: 1256–1263 doi:10.1016/j.gie.2021.11.045

[21] Marx M, Godat S, Caillol F et al. Management of non-functional pancreatic neuroendocrine tumors by endoscopic ultrasound-guided radiofrequency ablation: retrospective study in two tertiary centers. Dig Endosc 2022; 34: 1207–1213 doi:10.1111/den.14224

[22] Khoury T, Sbeit W, Fusaroli P et al. Safety and efficacy of endoscopic ultrasound-guided radiofrequency ablation for pancreatic neuroendocrine neoplasms: systematic review and meta-analysis. Dig Endosc 2024; 36: 395–405 doi:10.1111/den.14681

[23] Matsumoto K, Kato H, Kitano M et al. Study protocol for endoscopic ultrasonography-guided ethanol injection therapy for patients with pancreatic neuroendocrine neoplasm: a multicenter prospective study. BMJ Open 2021; 11: e046505

[24] Cotton PB, Eisen GM, Aabakken L et al. A lexicon for endoscopic adverse events: report of an ASGE workshop. Gastrointest Endosc 2010; 71: 446–454 doi:10.1016/j.gie.2009.10.027

[25] Matsumoto K, Kato H, Okada H. Usefulness of contrast-enhanced endoscopic ultrasonography for the treatment of ethanol reinjection in patient with small pancreatic neuroendocrine neoplasm. Dig Endosc 2022; 34: e5–e6 doi:10.1111/den.14148

[26] Hashim YM, Trinkaus KM, Linehan DC et al. Regional lymphadenectomy is indicated in the surgical treatment of pancreatic neuroendocrine tumors (PNETs). Ann Surg 2014; 259: 197–203 doi:10.1097/SLA.0000000000000348

[27] Han IW, Park J, Park EY et al. Fate of surgical patients with small nonfunctioning pancreatic neuroendocrine tumors: an international study using multi-institutional registries. Cancers (Basel) 2022; 14: 1038

[28] Garg R, Mohammed A, Singh A et al. EUS-guided radiofrequency and ethanol ablation for pancreatic neuroendocrine tumors: a systematic review and meta-analysis. Endosc Ultrasound 2022; 11: 170–185 doi:10.4103/EUS-D-21-00044

[29] Rossi G, Petrone MC, Capurso G et al. Standardization of a radiofrequency ablation tool in an ex-vivo porcine liver model. Gastrointestinal Disorders 2020; 2: 300–309

[30] Crinò SF, Napoleon B, Facciorusso A et al. Endoscopic ultrasound-guided radiofrequency ablation versus surgical resection for treatment of pancreatic insulinoma. Clin Gastroenterol Hepatol 2023; 21: 2834–2843 e2 doi:10.1016/j.cgh.2023.02.022

[31] Cauley CE, Pitt HA, Ziegler KM et al. Pancreatic enucleation: improved outcomes compared to resection. J Gastrointest Surg 2012; 16: 1347–1353 doi:10.1007/s11605-012-1893-7