

Access this article online
Quick Response Code:

Website: www.e-tjo.org
DOI: 10.4103/tjo.tjo_15_17

# Adjustable suture strabismus surgery in pediatric patients using pull-string technique

Chong-Bin Tsai

## Abstract:

**BACKGROUND/PURPOSE:** The concept of adjustable suture has been developed in strabismus surgeries for nearly four decades. This technique is not yet universally embraced by strabismus surgeons, especially in pediatric patients. The aim of this study is to describe and evaluate the application of the adjustable suture with pull-string technique in pediatric patients.

**METHODS:** A retrospective medical record review was conducted for patients aged 18 years and under who received adjustable suture strabismus surgery using short tag sliding noose with pull-string technique. For the analysis, the patients were arbitrarily divided into three age groups: 6 years and younger, between 6 and 12 years, and 12 years and older. Patients were examined at 1 week and 1, 3, and 6 months after surgery.

**RESULTS:** A total of 123 patients were enrolled in this study. The mean age at the time of surgery was 9.4 years, ranging from 0.7 to 18.4 years. Eighteen (14.6%) patients required adjustment and 105 (85.4%) patients did not require adjustment. The average follow-up was 10.2 months (range, 1–48 months). At their final postoperative follow-up, 93 of 123 (75.6%) patients were within 10 prism diopters of orthophoria. The success rates were 77.6% (66/85) in exotropia patients and 71.1% (27/38) in esotropia patients. The success rates were 76.4% (84/110) for those who receive the procedure as primary surgery and 69.2% (9/13) for those who receive the procedure as reoperative surgery. Of the 18 patients who required adjustment, 16 (88.9%) patients were successful. Of the 105 patients who did not require adjustment, 77 (73.3%) patients were successful.

**CONCLUSION:** This study showed that the pull-string technique provided similar success rate compared to those reported in literature in pediatric patients. The pull-string technique is developed to simplify the postoperative adjustments. Many surgeons encounter difficulties to handle the postoperative adjustments, especially when they need to retrieve the buried subconjunctival adjustable sutures. The obstacles are reduced with the aid of pull string. Using the pull-string technique, the surgeon can perform adjustable suture surgeries in any age group with confidence.

## Keywords:

Adjustable suture, pediatric patient, pull-string technique, strabismus surgery

## Introduction

Although the concept of adjustable suture has been developed in strabismus surgeries for nearly four decades,<sup>[1]</sup> this technique is not yet universally embraced by strabismus surgeons. It was estimated that less than one-fourth of strabismus surgeons

used adjustable suture technique and fewer than that used them in pediatric patients.<sup>[2,3]</sup> Possible obstacles include lack of confidence in the skill of adjustable suture technique, requirement of extra time and effort, risk of resection for pediatric patients in recovery room, and resistance from anesthesiologists. It has even been suggested that the benefit to children receiving adjustable suture is relatively small as compared to the risk they exposed to.

This is an open access article distributed under the terms of the Creative Commons Attribution-NonCommercial-ShareAlike 3.0 License, which allows others to remix, tweak, and build upon the work non-commercially, as long as the author is credited and the new creations are licensed under the identical terms.

For reprints contact: reprints@medknow.com

**How to cite this article:** Tsai CB. Adjustable suture strabismus surgery in pediatric patients using pull-string technique. Taiwan J Ophthalmol 2017;7:38-43.

Department of  
Ophthalmology, Chia-Yi  
Christian Hospital, Chia-Yi,  
Taiwan

### Address for correspondence:

Dr. Chong-Bin Tsai,  
Department of  
Ophthalmology, Chia-Yi  
Christian Hospital,  
539 Jhongsiao Road,  
Chia-Yi 60002, Taiwan.  
E-mail: 00687@cych.  
org.tw

Submission: 12-11-2016  
Accepted: 05-01-2017

Various techniques of adjustable suture strabismus surgery in pediatric patients were reported in literature.<sup>[4-9]</sup> However, there was still room for improvement. The aim of this study is to describe and evaluate the application of the pull-string adjustable suture technique in pediatric patients.

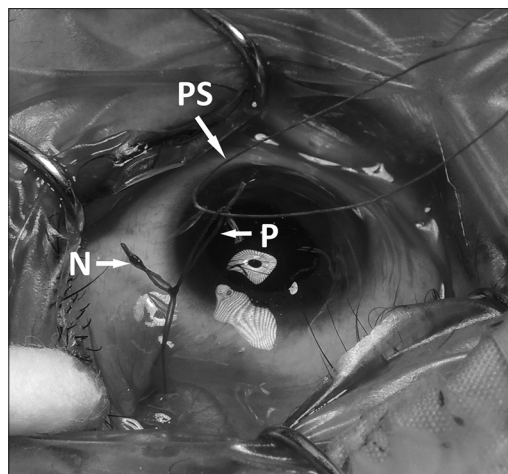
## Methods

This study was approved by the Chia-Yi Christian Hospital Institutional Review Boards with waiver of informed consent. A retrospective medical record review was conducted for all patients aged 18 years and under who had strabismus surgery performed by the same surgeon (CBT) from 2012 to 2016 at Chia-Yi Christian Hospital. All patients who had horizontal muscle surgery were included in the study. Patients who had additional vertical or oblique muscle surgery were also included, but only the horizontal component was analyzed. Patients were included only if they had a minimum postoperative follow-up of 1 month. Exclusion criteria included patients with restrictive strabismus, paralytic strabismus, strabismus from a slipped muscle, nystagmus, or Duane syndrome.

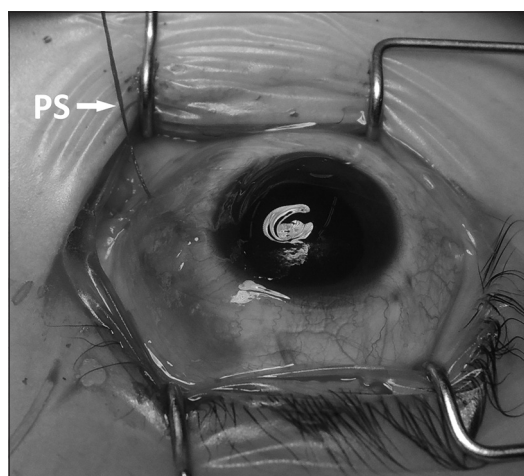
Radial fornix incisions were made through conjunctiva and Tenon's capsule. The site of conjunctival incision was selected as to minimize winding of the pull-string during later removal. Incisions at inferior nasal or inferior temporal quadrants were therefore selected for medial, lateral, and inferior rectus muscles and at superior quadrants were selected for superior rectus muscles.

Adjustable suture using short tag sliding noose with pull-string technique was performed.<sup>[10]</sup> Briefly, the muscle was secured using double-armed 6-0 polyglactin 910 sutures (Vicryl, Ethicon, Johnson and Johnson, Somerville, New Jersey, USA), detached, and reinserted in a hang back fashion with an 8-mm long pole suture and a 3-mm long short tag sliding noose. A thread of 6-0 polyglactin suture, the pull string, was then passed between the two arms of pole suture above the sliding noose [Figure 1]. The sliding noose suture, pole suture, and part of the pull string were then tucked under the conjunctiva. The conjunctival incision was closed with an 8-0 polyglactin 910 suture (Vicryl, Ethicon, Johnson and Johnson, Somerville, New Jersey, USA), leaving a 3–5 mm wide opening for the extra length of the pull string to be exposed [Figure 2]. The exposed portion of pull string was taped, with the two threads separated apart, on the adjacent skin [Figure 3].

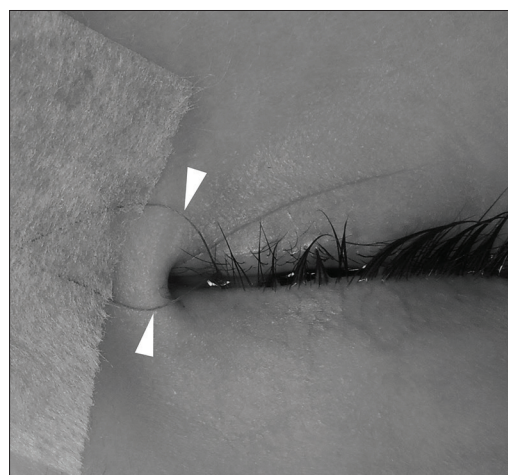
Patients were assessed in the postoperative recovery room at least 2 h after surgery. Proparacaine eye drops were placed in the eyes to facilitate the postoperative



**Figure 1:** Adjustable suture using short tag sliding noose with pull-string technique. A thread of 6-0 polyglactin suture, the pull string (PS), was passed between the two arms of pole suture (P) above the sliding noose (N)



**Figure 2:** The sliding noose suture, pole suture, and part of the pull string were then tucked under the conjunctiva. The conjunctival incision was closed with an 8-0 polyglactin 910 suture, leaving a 3–5 mm wide opening for the extra length of the pull string (PS) to be exposed



**Figure 3:** The exposed portion of pull string was taped, with the two threads (arrowheads) separated apart, on the adjacent skin

measurement. The patients were placed in an upright position. Measurements of ocular alignments were performed using an alternative cover test with prisms while the patient fixated on distant and near targets (either a penlight or a video on smartphone). For noncooperative patients, the Krimsky or Hirschberg test was used to evaluate corneal reflexes. A digital camera with flashlight was often used for instant review of the position of corneal reflexes, especially in uncooperative patients. The general criteria for adjustment were to overcorrect exotropia 6–8 prism diopters (PD) at distant and orthotropia for esotropia.

If adjustment was necessary, it was performed under topical anesthesia for cooperative patients, usually 15 years and above. Patients under age 15 were sedated in the recovery room by the anesthesiologist using intravenous propofol or ketamine, with mask oxygen supply and pulse oximeter to monitor oxygen saturation. A lid speculum was placed. The pull string was then used to pull out the long pole suture and then the short tag sliding noose, from subconjunctival space through the small incision. The surgeon then performed the adjustments outside the conjunctival incision, without the need to either enlarge the conjunctival wound or explore under conjunctiva to find the sutures. For cooperative patients, the assessment could be repeated after each adjustment and the pull string would help retrieve the pole suture, whenever the suture slipped back into the subconjunctival space. After the completion of adjustment, the pull string was cut, and the pole suture and sliding noose were tucked back to the subconjunctiva space through the small conjunctival incision.

If adjustment was unnecessary, the pull string could be removed with topical anesthesia. With the patient's eyes closed, one of the two exposed threads of pull string was cut. The separation of two threads when taping on the

skin helped the surgeon to identify each thread and not to cut both threads accidentally. The uncut thread was then pulled outward slowly. Once an inward retracting movement of the cut thread was observed, the whole pull string could be pulled out quickly. The overlying conjunctiva and the buried pole suture and sliding noose were not disturbed in the whole procedure of pull-string removal. The removal of pull string could be performed in any age group without the need of intravenous sedation by anesthesiologists.

All patients were examined at 1 week and 1, 3, and 6 months after surgery. A successful outcome was defined as orthotropia or a horizontal tropia of 10 PD or less at distant. All statistical calculations were performed using the computer program SPSS (IBM Corp. Armonk, NY, USA). Comparison of numerical variables between the study groups was performed using Pearson's Chi-square tests. Fisher's exact test was used when the expected frequency was <5.

## Results

A total of 123 patients, including 53 (43.1%) males and 70 (56.9%) females, were enrolled in this study. The mean age at the time of surgery was 9.4 years, with a range from 0.7 to 18.4 years. For the analysis, the patients were arbitrarily divided into three age groups: 6 years and younger (40 patients), between 6 and 12 years (46 patients), and 12 years and older (37 patients). Thirteen (10.6%) patients had undergone previous surgery. Eighty-five (69.1%) patients had exotropia and 38 (30.9%) patients had esotropia preoperatively. The mean preoperative deviation was 44.9 PD (range, 10–90 PD) in exotropia patients and 35.5 PD (range, 10–80 PD) in esotropia patients [Table 1]. Short tag sliding noose with pull-string sutures was placed on all recessed, resected, or plicated horizontal and vertical rectus muscles. Eighteen (14.6%) patients required

**Table 1: Preoperative data of enrolled patients**

	6 years and younger	Between 6 and 12 years	Between 12 and 18 years	Total
Number of patients	40	46	37	123
Age at time of surgery (years)	4.2±1.2	8.7±1.8	15.7±2.0	9.4±4.9
Sex (%)				
Male	18 (45.0)	19 (41.3)	16 (43.2)	53 (43.1)
Female	22 (55.0)	27 (35.8)	21 (56.8)	70 (56.9)
Previous strabismus surgery (%)				
Yes	1 (2.5)	7 (15.2)	5 (13.5)	13 (10.6)
No	39 (97.5)	39 (84.8)	32 (86.5)	110 (89.4)
Strabismus type (%)				
Exotropia	17 (42.5)	36 (78.3)	32 (86.5)	85 (69.1)
Esotropia	23 (57.5)	10 (21.7)	5 (13.5)	38 (30.9)
Preoperative deviation (%)				
Exotropia	53.6±21.9	41.6±15.7	43.8±15.1	44.8±17.3
Esotropia	40.9±16.5	24.9±9.8	31.8±15.9	35.5±16.2

adjustment and 105 (85.4%) patients did not require adjustment. In those patients who required adjustment, the adjustments were to correct undercorrection in 12 exotropia patients and 3 esotropia patients and to correct overcorrection in 2 exotropia patients and 1 esotropia patient [Table 2]. For those patients who did not require adjustments, pull-string sutures were removed under topical anesthesia in all patients successfully without complication.

The average follow-up was 10.2 months (range, 1–48 months). At their final postoperative follow-up, 93 of 123 (75.6%) patients were within 10 PD of orthophoria. The success rates were 77.6% (66/85) in exotropia patients and 71.1% (27/38) in esotropia patients, without statistically significant difference. The success rates were 76.4% (84/110) for those who receive the procedure as primary surgery and 69.2% (9/13) for those who receive the procedure those as reoperative surgery, without statistically significant difference. Of the 18 patients who required adjustment, 16 (88.9%) patients were successful. Of the 105 patients who did not require adjustment, 77 (73.3%) patients were successful. The difference of success rates between those who need adjustment and those who did not was not statistically significant [Table 3].

## Discussion

Adjustable suture strabismus surgery is a well-established technique in adult. However, physicians encounter more challenges when performed such surgeries in pediatric patients. The lack of cooperation during postoperative evaluation and during adjustment is the major obstacles. Many techniques have been developed to overcome the mentioned issues. An ideal adjustable suture technique should address the following concerns: when adjustment is not needed, there should be none or additional minimal manipulation; when adjustment is needed, the procedure should be performed quickly and causing minimal discomfort.

There are two basic types of adjustable suture technique: bow-tie technique and sliding noose technique.<sup>[11,12]</sup> The bow-tie technique requires fewer procedures during operation. It demands full exposure during adjustment. After untying the bow-tie, the surgeon holds the two muscle sutures steady and reties the suture tighter or looser to adjust the surgical amount. There are disadvantages of possible unequal lengths of muscle sutures after retying, nonquantitative amount of adjustment, and a noninterruptible procedure before retying is completed. The last disadvantage is of concern especially in pediatric patients receiving intravenous propofol, which is a mainly hypnotic and barely analgesic agent. Despite the concurrent use of topical anesthesia, any excessive manipulation under the conjunctiva will stimulate the patients to an irritable status that the anesthesiologist often needs to request the surgeon to hold the procedure temporally and increase the dose of anesthetic agents to resedate the patient before further proceeding. If the surgeon cannot stop the manipulation when the anesthesiologist asks for having a hold, the scenario sometimes turns critical, especially in an environment of the recovery room. Such experiences of insecurity will make the anesthesiologist less willing to resedate the patient in the recovery room for adjustment. In that situation, the adjustment procedure will become more time-consuming if every patient has to go back to operation room for resedation.

The bow-tie techniques used in pediatric patients were reported in the earlier literature. In 1999, Chan *et al.*<sup>[4]</sup> described adjustable suture technique in 89 patients, aged 7–18 years, who had undergone horizontal strabismus surgery. A mock trial with cotton bud touching the globe under topical anesthesia was performed 1 day preoperatively to determine which patients will be cooperative for the procedure. A bow-tie technique was used in the muscle sutures over a stand of 6-0 silk after the suture ends were passed back through the original insertion. A “bucket-handle” 6-0 vicryl suture was placed to facilitate handling the globe during adjustment. All

**Table 2: Causes and amounts of postoperative adjustments**

	6 years and younger	Between 6 and 12 years	Between 12 and 18 years	Total
Number of patients	40	46	37	123
Patients required postoperative adjustment				
No (%)	35 (87.5)	39 (84.8)	31 (83.8)	105 (85.4)
Exotropia	13	29	28	70
Esotropia	22	10	3	35
Due to overcorrection (%)	3 (7.5)	1 (2.2)	0	4 (3.3)
Exotropia	2	1		3
Esotropia	1	0		1
Due to undercorrection (%)	2 (5.0)	6 (0.0)	6 (16.2)	14 (11.4)
Exotropia	2	6	4	12
Esotropia	0	0	2	2
Amount of adjustment (mm)	2.8±1.1	3.4±1.0	4.5±1.8	3.6±1.4

**Table 3: Postoperative success rates between different groups**

	Success rate	P
All patients	75.6% (93/123)	
Age group		
6 years or younger	65.0% (26/40)	0.163
Between 6 and 12 years	80.4% (37/46)	
Between 12 and 18 years	81.1% (30/37)	
Strabismus type		
Exotropia	77.6% (66/85)	0.431
Esotropia	71.1% (27/38)	
Previous strabismus surgery		
Yes	69.2% (9/13)	0.517
No	76.4% (84/110)	
Horizontal muscles operated		
One	100% (2/2)	0.161
Two	79.5% (70/88)	
Three	68.0% (17/25)	
Four	57.1% (4/7)	
Need for postoperative adjustment		
Yes	88.9% (16/18)	0.236
No	73.3% (77/105)	

patients were adjusted on the next day after surgery to give the patient more time to recover from the anesthesia. Topical anesthesia was administered. No lid speculum was used to avoid upsetting the patients. The bucket-handle suture could help control the globe without direct contact. All patients completed the procedure on the first postoperative day, with 24 (27%) patients requiring further adjustment. The success rate was 74% after a mean follow-up period of 13.3 months. In 2007, Dawson *et al.*<sup>[5]</sup> reported adjustable suture squint surgery in 45 patients, aged 10–15 years. Adjustable sutures were placed on both recessed and resected horizontal and vertical recti. The surgical technique used was identical to those used in adult patients. Their technique left long suture ends at the end of surgery and required postoperative manipulation to trim the suture ends in all patients. The squint surgery was performed under general anesthesia and the adjustment was carried out on the same day under topical anesthesia. Thirty (67%) patients required adjustment. Thirty-four (76%) patients achieved successful outcomes.

The sliding noose technique takes a different approach. The adjustment of surgical amount is accomplished by moving the sliding noose forward or backward on the two threads of pole sutures attaching the muscle. The adjustments are equal for both threads. The amount of adjustment is well controlled and quantitative. The sliding noose and pole suture can be pulled outside the conjunctival opening for adjustment. Therefore, it is not necessary for full exposure to perform the adjustment.

Increasing applications of sliding noose techniques in pediatric patients were reported. Engel and Rousta<sup>[6]</sup>

used a modified technique in 61 patients, aged 12 months to 14 years. The technique as described by Jampolsky<sup>[13]</sup> placed a sliding knot around the sutures connected to the muscle (the pole suture) to control the amount of hanging back from original insertion. They modified the technique with a separate partial thickness scleral pass of the ends of pole suture near the fornix incision. The additional 6–7 mm of suture left beyond the sliding knot allowed later adjustment. The patients were evaluated 3–5 h after surgery. The patients for whom the adjustment was not necessary were discharged without further procedure. The patients requiring adjustment were adjusted under intravenous propofol sedation, mask, or laryngeal mask airway anesthesia. Topical tetracaine was administered. An eyelid speculum was used. The fornix incision was opened, and the pole sutures were exposed for adjustment. After adjustment, the pole sutures were tied and trimmed. Twenty-two (36%) patients required adjustments. After a minimum follow-up of 6 weeks (median 19.4), the success rate was 88%.

To simplify the adjustment procedure, Hakim *et al.*<sup>[7]</sup> reported a releasable adjustable suture technique on medial rectus recession in fifty infantile esotropia patients, aged 10–94 months. The medial rectus muscle was recessed, reattached to the new sclera site with 2 mm hang back, and was tied. A second suture, passing under the previously tied muscle suture, was placed at the original insertion. The second suture was tied in a strengthened loop knot to advance the muscle suture 2 mm and was kept releasable. One limb of the releasable suture was tucked in the inferior fornix. The patients were evaluated on the first postoperative day. If the alignment was satisfactory, the releasable suture was left in place without further procedure. If undercorrection was noted, the tucked suture was pulled to untie the strengthened loop. The muscle then slipped and produced additional 2 mm recession. Eighteen (36%) patients required adjustment. The overall success rate was 94%. However, this technique with fixed amount of extra-recession only was of limited uses clinically.

Another approach to simplify the adjustment stage by short tag noose technique was reported by Nihalani and Hunter.<sup>[14]</sup> The advantage is that there is no procedure at all when adjustment is not needed. However, it was often difficult to retrieve the buried adjustable sutures under the conjunctiva when adjustment was required. To avoid stimulating the patient by prolonged subconjunctival exploring, a modification with pull-string technique was developed.<sup>[10]</sup> The major advantage of pull-string technique is to simplify the process of recovering the tucked subconjunctival adjustable sutures, thus avoiding manipulation under the conjunctiva and reducing discomfort to patients. Neither the removal of the pull string in nonadjusted cases nor retrieval of the pole suture

in adjusted cases takes more than 15 s. The disadvantage is that all patients, even those not requiring adjustment, have to receive some manipulation of sutures. In spite of the disadvantage, the removal of pull string is quite simple and can be performed without any sedation, even in a uncooperative infant [Figure 1]. In our study, the pull-string technique was used in all patients. For those patients not needing adjustment, all pull strings were removed successfully without any sedation.

The success rates of adjustable and nonadjustable suture strabismus surgery in pediatric patients were reported. Awadein *et al.*<sup>[8]</sup> retrospectively compared the success rates between 98 patients, aged 0.5–10 years, of nonadjustable suture group and 298 patients, aged 0.5–10 years, of adjustable suture group. In the adjustable suture group, an adjustable sliding noose was placed around the pole suture. An additional 6-0 polyester suture was placed twice through the sclera as a traction suture used to stabilize the globe while retracting the conjunctiva to expose the noose during adjustment. The patients were evaluated 1–2 h after surgery. If adjustment was necessary, the patients received adjustment under topical anesthesia or intravenous propofol anesthesia. 189 (64%) patients required adjustment. The early, at the end of 3 months follow-up, success rate in the adjustable group (79%) was significantly better than in the nonadjustable group (64.5%). Kamal *et al.*<sup>[9]</sup> reported a prospective randomized control trial, including 30 patients, aged 0.5–11 years, of nonadjustable suture group and 30 patients, aged 0.6–12 years, of adjustable suture group. In the adjustable suture group, an adjustable noose was placed around the muscle suture and a traction suture of 6-0 vicryl was placed through sclera to gain access to the adjustable knot during adjustment. The patients were evaluated at 1–4 h after surgery. When necessary, adjustments and tying of the suture were performed under intravenous propofol anesthesia. In the adjustable suture group, 5 (16.7%) overcorrected patients and 5 (16.7%) undercorrected patients required further adjustments. The 6 months success rate was 86.67% of adjustable group and 73.33% of nonadjustable group. The adjustable group showed better clinical results although the difference was not statistically significant.

In this study, the short tag sliding noose with pull-string technique was used in pediatric patients. The overall success rate was 75.6%. The success rates were 65.0%, 80.4%, and 81.1% in the age group 0–6, 6–12, and 12–18, respectively. The outcome was comparable to those of Chan *et al.*,<sup>[4]</sup> Dawson *et al.*,<sup>[5]</sup> and Awadein *et al.*,<sup>[8]</sup> who reported success rates of 74%, 76%, and 79%, respectively. The pull-string technique is developed to simplify the postoperative adjustments. Many surgeons

encounter difficulties to handle the postoperative adjustments, especially when they need to retrieve the buried subconjunctival adjustable sutures. It is often time-consuming to identify the adjustable sutures in the subconjunctival space, which is messy with blood clots and fibrin postoperatively. Furthermore, prolonged manipulation produces more irritation, which is undesirable in a sedated pediatric patient. These obstacles are reduced remarkably with the aid of pull string. Although the technique requires additional removal procedure when adjustment is not necessary, the procedure of pull string removal is simple and can be completed usually within 5 min. Using the pull-string technique, the surgeon can perform adjustable suture surgeries in any age group with confidence.

### Financial support and sponsorship

Nil.

### Conflicts of interest

The author has no conflicts of interest to declare.

### References

1. Rosenbaum AL, Metz HS, Carlson M, Jampolsky AJ. Adjustable rectus muscle recession surgery. A follow-up study. *Arch Ophthalmol* 1977;95:817-20.
2. Karmel M. Second chances: Adjustable sutures for strabismus corrections. *Eyenet*; 2010. p. 31-3.
3. Repka MX, Yu F, Lum F, Coleman AL. Strabismus among aged Medicare beneficiaries: Impact of health status and region. *J AAPOS* 2013;17:391-4.
4. Chan TK, Rosenbaum AL, Hall L. The results of adjustable suture technique in paediatric strabismus surgery. *Eye (Lond)* 1999;13:567-70.
5. Dawson E, Bentley C, Lee J. Adjustable squint surgery in children. *Strabismus* 2001;9:221-4.
6. Engel JM, Rousta ST. Adjustable sutures in children using a modified technique. *J AAPOS* 2004;8:243-8.
7. Hakim OM, El-Hag YG, Haikal MA. Releasable adjustable suture technique for children. *J AAPOS* 2005;9:386-90.
8. Awadein A, Sharma M, Bazemore MG, Saeed HA, Guyton DL. Adjustable suture strabismus surgery in infants and children. *J AAPOS* 2008;12:585-90.
9. Kamal AM, Abozeid D, Seif Y, Hassan M. A comparative study of adjustable and non-adjustable sutures in primary horizontal muscle surgery in children. *Eye (Lond)* 2016;30:1447-51.
10. Tsai CB. Pull-string technique for recovering subconjunctival short-tag noose adjustable sutures. *J AAPOS* 2014;18:606-8.
11. Hunter DG. Adjustable suture in strabismus surgery. In: Wilson ME, Saunders RA, Tricedi RH, editors. *Pediatric Ophthalmology: Current Thought and a Practical Guide*. Heidelberg, Germany: Springer; 2008. p. 213-26.
12. Strominger MB, Richards R. Adjustable sutures in pediatric ophthalmology and strabismus. *J Pediatr Ophthalmol Strabismus* 1999;36:112-7.
13. Jampolsky A. Current techniques of adjustable strabismus surgery. *Am J Ophthalmol* 1979;88:406-18.
14. Nihalani BR, Hunter DG. Adjustable suture strabismus surgery. *Eye (Lond)* 2011;25:1262-76.