

Unilateral multiple variations of renal, phrenic, suprarenal, inferior mesenteric and gonadal arteries

**Kosuri Kalyan
Chakravarthi**

Department of Anatomy, Santhiram Medical College, NH-18, Nandyal, Kurnool District, Andhra Pradesh, India

Address for correspondence:

Mr. Kosuri Kalyan Chakravarthi, Department of Anatomy, Santhiram Medical College, NH-18, Nandyal - 518 501, Kurnool District, Andhra Pradesh, India. E-mail: kalyankosuric@gmail.com

Abstract

Knowledge of the branching pattern of the abdominal aorta is clinically important for any abdominal surgeon operating on parts of the gut or neighboring structures. Variations of these vessels may influence urological, renal transplantation and laparoscopic surgeries. We present an unreported case of multiple variations of branching pattern of abdominal aorta. It includes double renal arteries for left kidney, a common trunk with right and left phrenic, right and left superior suprarenal and left middle supra renal arteries, and a common trunk originate 2.5 cm above the bifurcation of abdominal aorta gave off inferior mesenteric, accessory renal artery to the left kidney and left testicular arteries in the middle-aged normal male cadaver. The embryogenesis of such multiple variations of branches of abdominal aorta is not clear, but the anatomic consequences may have important clinical implications. Knowledge of these variations is important for urologists, radiologists and surgeons in general.

KEYWORDS: Gonadal arteries, mesenteric, phrenic arteries, renal arteries, supra-renal arteries

INTRODUCTION

Renal arteries are a pair of lateral branches from the abdominal aorta; generally originate from the abdominal aorta, just below the superior mesenteric artery in the level of L1 and L2 vertebrae. Normally, each kidney receives one renal artery. Variations in the number of the renal arteries and their position with respect to the renal veins are common; and so are the variations of the supra-renal arteries.^[1] Accessory renal arteries may originate from the aorta or from other vessels, a single renal artery may be present in only 33% of normal subjects.^[2]

The superior, middle and inferior suprarenal arteries are normally branches of phrenic, abdominal aorta and renal arteries. The inferior phrenic arteries constitute a pair of important vessels, supplying multiple organs including the diaphragm, adrenal glands, esophagus, stomach, liver, inferior vena cava, and retroperitoneum. The majority (80-90%) of inferior phrenic arteries originate as separate vessels with near equal frequency from either the abdominal aorta or the celiac trunk. Testicular artery is the paired branch of abdominal aorta, it can exhibit a wide range of origin variations. The gonadal arteries (testicular in males and ovarian in females) may arise from other arteries such as the renal, suprarenal or lumbar arteries. The artery may be found duplicated, tripled or quadrupled.^[3]

Here we describe an unreported case of multiple variations of branches of abdominal aorta. The objective of this case report is to bring awareness to clinicians about the variations of branches of abdominal aorta. This report may also be useful to clinicians performing invasive techniques.

CASE REPORT

During routine dissection for the undergraduate students in the Department of Anatomy, Santhiram Medical College, Nandyal, of a middle-aged male cadaver, we encountered unilateral anomalous branching pattern of abdominal aorta.

OBSERVATION

We observed following multiple anomalous branching pattern of abdominal aorta

- Double renal arteries for left kidney
- A common trunk which later gave off right and left phrenic, right and left superior suprarenal and left middle supra renal arteries
- A common trunk arose 2.5 cm above the bifurcation of abdominal aorta gave off inferior mesenteric, accessory renal to the left kidney and left testicular arteries [Figure 1].

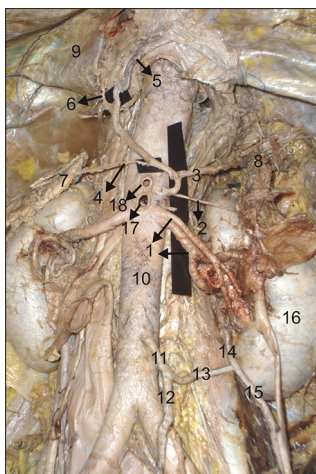


Figure 1: Multiple variations in the branching pattern of the abdominal aorta. 1-Two renal arteries; 2-Left middle supra-renal artery; 3-Left superior supra-renal artery; 4-Right superior supra-renal; 5-Left inferior phrenic artery; 6-Right inferior phrenic artery; 7-Right supra-renal gland; 8-Left supra-renal gland; 9-Diaphragm; 10-Abdominal aorta; 11-Common trunk; 12-Inferior mesenteric artery; 13-Common branch which later divides in to two branches; 14-Left accessory renal artery; 15-Left gonadal artery; 16-Left kidney; 17-Superior mesenteric artery; 18-Coeliac trunk

DISCUSSION

Khamanarong *et al.*^[4] dissected 267 cadavers (534 kidneys) for establishing the incidence and characteristics of variations in renal arteries among Thai nationals. They found double renal arteries in 93 kidneys (17.43%). Bordei *et al.*^[5] analyzed 272 kidneys for a study of renal vascularization and identified 54 (20%) double renal arteries. In the present case anomalous double renal arteries were observed on the left side. Such variations may be due to the deficiency in the development of mesonephric arteries.

The inferior phrenic may arise from the renal, left gastric, superior mesenteric, suprarenal; or rarely from the hepatic artery.^[6-8] Shivaram *et al.*^[9] reported anomalous origin of the inferior phrenic arteries from the celiac trunk. Variations in the origin of suprarenal arteries have been reported before.^[10] Middle suprarenal artery is the most variable among the three suprarenal arteries. In the present case we found anomalous origin of common trunk for right and left inferior phrenic, right and left superior suprarenal and left middle supra renal arteries. Such anomalies are important for surgical and radiological interventions of retroperitoneal organs of upper abdomen to avoid complications.

There are different reports in the literature on the presence of accessory renal arteries on the right or left sides. Accessory renal arteries rarely originate from the external iliac, lumbar, spermatic, ovarian, inferior

mesenteric, superior suprarenal, inferior phrenic, right colic, subcostal, contralateral renal, splenic and the thoracic aorta.^[11] Variations in the origin of testicular arteries are common and are frequently reported. Ravery *et al.*^[12] reported anomalous origin of the testicular artery from the inferior polar artery of the kidney and its surgical importance. Armstrong *et al.*^[13] reported common origin of inferior mesenteric and accessory renal artery. But in this case we found an extremely rare anomalous origin of common trunk for inferior mesenteric, accessory renal artery to the left kidney and left gonadal artery [Figure 1]. Such variations have not been reported in literature to the best of our knowledge. Therefore, awareness of the possible existence of such variations of inferior mesenteric, testicular and accessory renal arteries is of great importance during surgical procedures in this region.

CONCLUSION

An awareness of renal, suprarenal, mesenteric and testicular vascular variations is important for both surgeons and radiologists. Knowledge of the variations in renal arterial supply has assumed increased importance for renal transplantation, the implantation of vascular stents, assessment of renovascular hypertension, vascular reconstruction, and reconstructive surgery for abdominal aortic aneurysms.

REFERENCES

1. Jeffery RF. Unusual origin of renal arteries. *Radiol* 1972; 102:309-10.
2. Anson BJ, McVay CB. The topographical positions and the mutual relations of the visceral branches of the abdominal aorta. A study of 100 consecutive cadavers. *Anat-Rec.*, 1936; 67:7-15.
3. Bergman RA, Cassell MD, Sahinoglu K, Heidger PM. Human doubled renal and testicular arteries. *Ann Anat* 1992; 174:313-5.
4. Khamanarong K, Prachaney P, Utraravichien A, Tongun T, Sripaoraya K. Anatomy of renal arterial supply. *Clin Anat* 2004; 17 (4):334-6.
5. Bordei P, Sapte E, Iliescu D. Double renal arteries originating from the aorta. *Surg Radiol Anat* 2004; 26 (6):474-9.
6. Lin PH, Chalk EL. Embryology, anatomy and surgical exposure of the abdominal blood vessels. *Surg Clin N Am* 2000; 80:417-33.
7. Nebesar RA, Kornbilth OL, Pollard JJ, Mihels NA. Celiac and superior mesenteric arteries: A correlation of angiograms and dissections. Boston Little Brown Co., 1969; P 1-178.
8. Pick JW, Anson BJ. Inferior phrenic artery: Origin and suprarenal branches. *Anat Rec* 1940; 78:413-7.
9. Shivarama CH, Bhat Shivarama, Shetty RK, Avadhani R. Multiple variations of branches of abdominal aorta: A case study. *Nitte University Journal of Health Science* 2012; 2: 48-50.
10. Harrison CB, Kaplan JJ, Scherz HC, Packer MG, Jones J. Microvascular auto transplantation of the intra-abdominal testis. *J Urol* 1990; 144:506-7.
11. Van Baalen JM, Van Bockel HJ. Thoracic origin of the right renal artery. *J Vasc Surg* 1994; 19:762-3.
12. Ravery V, Cussenot O, Desgrandchamps F, Teillac P, Martin-Bouyer Y. Variations in arterial blood supply and the risk of hemorrhage during percutaneous treatment of lesions of the pelviureteral

junction obstruction: Report of a case of testicular artery arising from an inferior polar renal artery. *Surg Radiol Anat* 1993; 15:355-9.

13. Armstrong BG, Hunt TH, Price CW, Resnick MI. Common origin of inferior mesenteric and accessory renal artery. *Urology* 1979; 14: 298-9.

How to cite this article: Chakravarthi KK. Unilateral multiple variations of renal, phrenic, suprarenal, inferior mesenteric and gonadal arteries. *J Nat Sc Biol Med* 2014;5:173-5.

Source of Support: Nil. **Conflict of Interest:** None declared.

Access this article online	
Quick Response Code:	Website: www.jnsbm.org
	DOI: 10.4103/0976-9668.127320