

Received: 2016.10.16  
Accepted: 2016.12.18  
Published: 2017.03.16

ISSN 1941-5923  
© Am J Case Rep, 2017; 18: 271-275  
DOI: 10.12659/AJCR.901975

# Refractory Cardiogenic Shock from Right Ventricular Infarction Successfully Managed with Inhaled Epoprostenol

Authors' Contribution:  
Study Design A  
Data Collection B  
Statistical Analysis C  
Data Interpretation D  
Manuscript Preparation E  
Literature Search F  
Funds Collection G

DEF 1 **Natalie Held**  
DE 1 **Nathaniel Little**  
DE 1,2 **Mori J. Krantz**  
DE 1,2 **Brian L. Stauffer**

1 School of Medicine, University of Colorado, Aurora, CO, U.S.A.  
2 Department of Internal Medicine – Cardiology, Denver Health Medical Center, Denver CO, U.S.A.

**Corresponding Author:** Brian L. Stauffer, e-mail: [brian.stauffer@ucdenver.edu](mailto:brian.stauffer@ucdenver.edu)  
**Conflict of interest:** None declared

**Patient:** Male, 53  
**Final Diagnosis:** Cardiogenic shock from acute right coronary artery infarction  
**Symptoms:** Altered mental state  
**Medication:** —  
**Clinical Procedure:** Inhaled epoprostenol  
**Specialty:** Cardiology

**Objective:** Unusual clinical course

**Background:** Recognition and appropriate management of right ventricular (RV) infarction is essential, as RV injury increases mortality and substantially alters management during acute coronary syndrome. We report a case of RV infarction presenting with new right bundle branch block (RBBB), and therapeutic use of inhaled epoprostenol to reduce RV afterload and augment cardiac output during refractory cardiogenic shock.





**Case Report:** A 53-year-old male presented to our institution in ventricular fibrillation with subsequent development of RBBB in the setting of proximal right coronary artery occlusion. Following percutaneous coronary intervention, the patient developed severe RV dysfunction with refractory cardiogenic shock. This was successfully managed with inhaled epoprostenol with normalization of right ventricular systolic function.

**Conclusions:** Although typically associated with anterior myocardial infarction, new RBBB should be recognized as a potential presenting sign of acute RV infarction. The use of inhaled epoprostenol in the setting of RV infarction has not been previously described, but it may augment right ventricular cardiac output via pulmonary vasodilatation.

**MeSH Keywords:** Bundle-Branch Block • Epoprostenol • Inferior Wall Myocardial Infarction • Shock, Cardiogenic

**Abbreviations:** RV – right ventricular; RBBB – right bundle branch block; RCA – right coronary artery; LAD – left anterior descending; ECG – electrocardiogram; IABP – intra-aortic balloon pump; MAP – mean arterial pressure; LV – left ventricular; WU – Wood units; PA – pulmonary artery; PDA – posterior descending artery

**Full-text PDF:** <http://www.amjcaserep.com/abstract/index/idArt/901975>

 1673  —  3  11



## Background

Right ventricular (RV) infarction complicates up to half of acute inferior myocardial infarctions, generally in the setting of proximal right coronary artery (RCA) occlusion [1,2]. Early recognition is important, as RV infarction increases mortality and complicates management given the associated risk of life-threatening arrhythmias and the potential to worsen clinical status if treated with nitrates and other preload-reducing agents frequently used during left ventricular (LV) infarction [1]. We describe an unusual case of RV infarction presenting with right bundle branch block (RBBB). While right or left bundle branch block can complicate anterior wall myocardial infarction as a result of reduced blood supply to the left anterior descending (LAD) artery branches supplying the interventricular septum, these conduction disturbances have not been previously reported in RV infarction cases of RCA occlusion [3,4]. Following RCA reperfusion, our patient developed severe RV dysfunction and cardiogenic shock that was treated with inhaled epoprostenol, in addition to traditional therapies utilized for vasopressor support and afterload augmentation. To our knowledge, the successful use of inhaled prostacyclin therapy for management of refractory cardiogenic shock after RV infarction has not been described.

## Case Report

A 53-year-old male had a history of non-obstructive coronary artery disease with a prior coronary arteriogram demonstrating a 40–50% RCA stenosis. He subsequently presented to the hospital after becoming obtunded and unresponsive at home. Emergency medical services found the patient to be pulseless and in ventricular fibrillation. He was intubated and received several rounds of defibrillation and intravenous epinephrine in route to the hospital prior to return of spontaneous circulation. In the emergency department (ED), a 12-lead electrocardiogram (ECG) revealed sinus tachycardia with inferior and anterior ST segment elevations and a new RBBB (Figure 1). He was emergently taken to the cardiac catheterization lab, where a 100% proximal RCA thrombotic occlusion was demonstrated. Manual aspiration thrombectomy was performed and a drug eluting stent was implanted with resulting thrombolysis in myocardial infarction (TIMI) grade 3 coronary flow. Due to profound hypotension and bradycardia, an intra-aortic balloon pump (IABP) and a temporary transvenous pacemaker were placed. He was subsequently resuscitated with six liters of crystalloid and continuous intravenous infusions of norepinephrine, vasopressin, dobutamine, and phenylephrine were initiated for persistent hypotension. Ventilator settings were optimized to address hypoxemia and the potential contribution of hypoxia-mediated pulmonary vasoconstriction. In spite of maximal doses of four vasoactive infusions and an

IABP, the patient's augmented mean arterial pressure (MAP) steadily declined to 40 mm Hg over the next two hours and his serum lactate remained elevated at 5.4 mmol/L.

An emergent bedside echocardiogram demonstrated normal LV systolic function with inferior wall hypokinesis and severely reduced RV systolic function with RV dilation. Given the patient's progressive hemodynamic decline, persistent hypotension, and significantly reduced RV systolic function, continuously inhaled epoprostenol 50 ng/kg/minute was initiated via endotracheal tube, in an effort to optimize RV cardiac output through reduction in pulmonary vascular resistance and subsequent reduction in RV afterload.

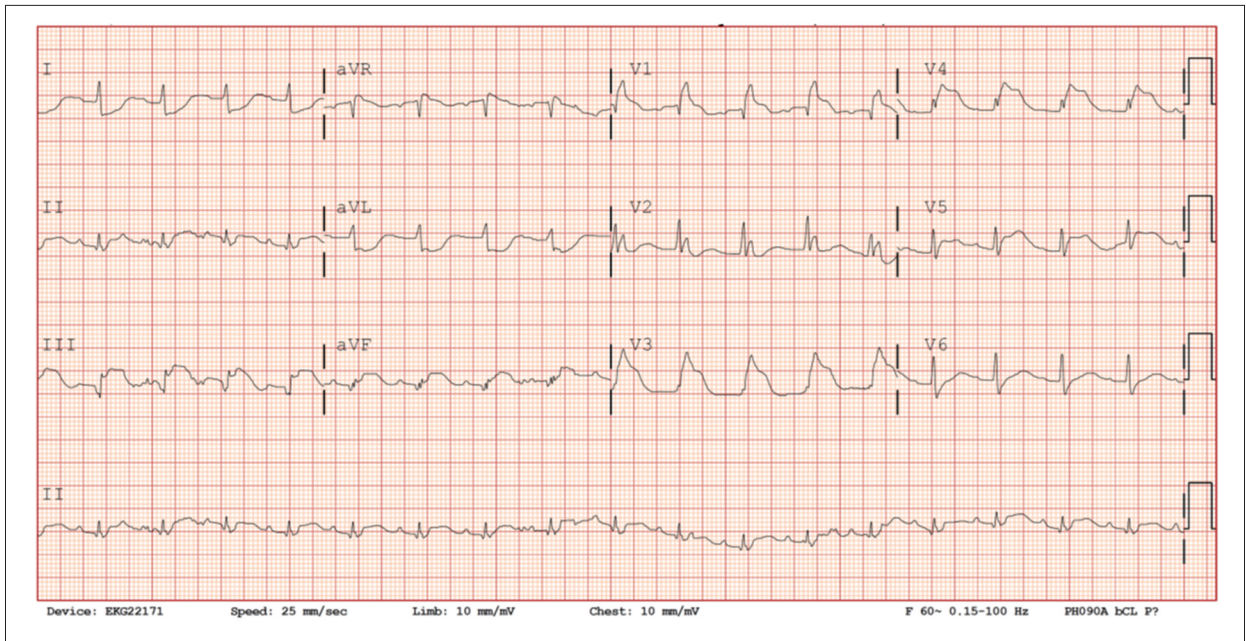
Within an hour of starting epoprostenol the patient's MAP consistently exceeded 60 mm Hg. Over the next 24 hours his lactate fell to 2.8 mmol/L and he was weaned off of all vasoactive medications with the exception of dobutamine 10 mcg/kg/minute. Inhaled epoprostenol was continued along with IABP counter-pulsation and transvenous pacing. A limited transthoracic echocardiogram demonstrated markedly improved (low normal) RV systolic function. Right heart catheterization 24 hours after initiation of inhaled epoprostenol revealed a mean pulmonary artery pressure of 29 mm Hg, pulmonary capillary wedge pressure of 16 mm Hg, and Fick cardiac index of 2.00 L/min/m<sup>2</sup>. Pulmonary vascular resistance was 2.94 Wood units (WU) and systemic vascular resistance was 1212 WU. Pulmonary artery (PA) saturation was 53%.

The patient was maintained on continuous inhaled epoprostenol for 30 hours, after which the medication was weaned in a step-wise fashion. Three days later the IABP, temporary transvenous pacer, and dobutamine drip were discontinued after repeat PA saturation was 75%, suggesting normal systemic perfusion. Repeat ECG showed a resolution of ST elevations and RBBB (Figure 2). The patient was extubated eight days after presentation and ultimately discharged home against medical advice on hospital day 12.

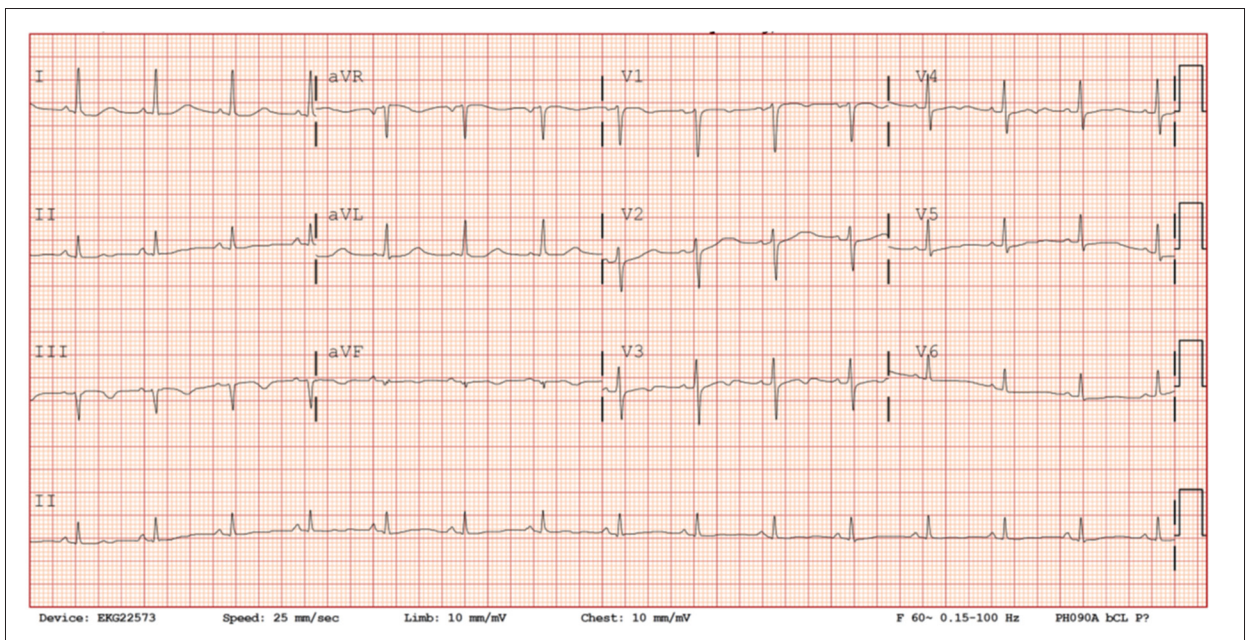
He was seen in cardiology clinic one month after hospital discharge and had no signs or symptoms of heart failure. A transthoracic echocardiogram demonstrated a mildly dilated RV with normal RV systolic function.

## Discussion

Both the presence of RBBB and RV infarction have independently been shown to increase in-hospital mortality during acute myocardial infarction, making early recognition of each important for improving patient prognosis [5,6]. New RBBB is traditionally suggestive of LAD coronary artery occlusion leading to myonecrosis of the interventricular septum. The current



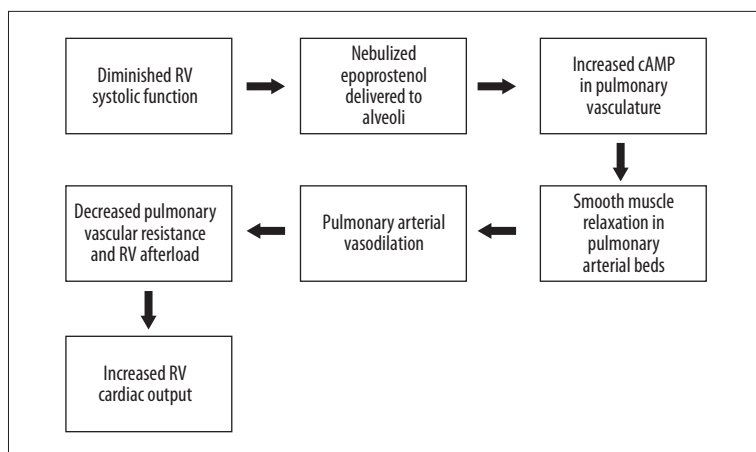
**Figure 1.** ECG during initial presentation. There are ST elevations in the inferior and anterior leads, and a right bundle branch block.



**Figure 2.** ECG after coronary reperfusion and removal of transvenous pacer. There is resolution of ST elevation and right bundle branch block.

case is novel in two regards that may assist clinicians diagnostically and therapeutically: it demonstrates that RBBB may occur in ST-segment elevation myocardial infarction that is unrelated to occlusion of the LAD, and that adjunct treatment with inhaled epoprostenol may rapidly ameliorate cardiogenic shock in the setting of inferior infarction complicated by severe RV systolic dysfunction and shock.

RBBB has been described as an ominous prognostic factor in patients with anterior myocardial infarction [6], but there is little published data describing RBBB as a presenting sign or complication of inferior infarction due to RCA occlusion. Celik et al. described a case of intermittent RBBB development in the setting of acute inferior myocardial infarction due to mid-circumflex lesion (with chronic total occlusion of the RCA) [3]. They postulated that RBBB developed in the setting of interrupted



**Figure 3.** Proposed mechanism of epoprostenol in acute right ventricular infarction showing the beneficial effects of selective pulmonary arterial vasodilation.

posterior descending artery (PDA) flow from the circumflex occlusion, as the right bundle branch is supplied by both branches of the left anterior descending artery, and collaterals from either the right or circumflex systems (including the atrioventricular node artery originating from the PDA) [3,7]. Our case of RBBB developing in the setting of single vessel coronary arterial obstruction is surprising. We speculate that RBBB in our patient may have developed from overwhelming hypoperfusion in the PDA distribution as well as the atrioventricular nodal artery originating in a right-dominant system. In contrast to the natural history of anterior wall myocardial infarctions complicated by RBBB, which persist and generally require permanent pacemaker, our patient's RBBB resolved following percutaneous coronary intervention.

Management of RV infarction includes widely accepted interventions for LV infarction, including the use of intravenous thrombolytics and percutaneous coronary interventions to address total thrombotic arterial occlusion. In the setting of acute RV failure, however, management also requires understanding and optimization of right-sided cardiovascular hemodynamics. Adequate right-sided filling pressure is critical for maintaining cardiac output in acute RV failure, as an ischemic right ventricle has a fixed and reduced stroke volume [1]. In contrast to patients with LV infarcts alone, patients with RV infarction require aggressive intravenous fluid resuscitation to optimize preload and maintain adequate forward flow. Drugs that reduce preload such as nitrates should be avoided as the infarcted RV is in a relatively under-filled state. If RV failure ensues, hemodynamics should be further optimized with addition of inotropic support and reduction of RV afterload. Initially, therapy should be aimed at correcting causes of pulmonary vascular constriction like hypercapnia, acidemia, and alveolar hypoxia [8]. In the current case, however, these interventions failed to improve hemodynamics. Ultimately, RV afterload reduction was attempted using a pulmonary arterial vasodilator administered through the endotracheal tube. Many such medications are approved for treatment of chronic pulmonary

arterial hypertension, but not for treatment of acute RV failure in the setting of myocardial ischemia.

In the case described, inhaled epoprostenol was used as a pulmonary vasodilator to reduce afterload of the right heart and theoretically improve cardiac output of a severely compromised RV. Epoprostenol is a naturally occurring prostacyclin that increases intracellular cAMP leading to smooth muscle relaxation, pulmonary vasodilatation, and potentially increased cardiac inotropy [8]. As a continuous intravenous infusion, it has been shown to improve both exercise capacity and survival in pulmonary arterial hypertension [9]. It has also been demonstrated as an inhaled formulation to treat acute RV failure after cardiothoracic surgery [10]. Mechanistically similar medications, such as inhaled nitric oxide, have been shown to increase RV ejection fraction, pulmonary hemodynamics, and mixed venous oxygen saturation in patients with acute RV failure [7]. Unfortunately, both the delivery system necessary for nitric oxide, as well as the medication cost itself, could be prohibitive in hospitals without a large pulmonary hypertension population [11]. Although, there have been no randomized trials examining the use of inhaled epoprostenol in acute ischemic RV failure, inhaled epoprostenol may be an alternate strategy for management of these patients without the need for specialized delivery devices.

We hypothesize that addition of inhaled epoprostenol in our patient resulted in an incremental reduction in pulmonary vascular resistance and right heart afterload, ultimately translating into improved overall cardiac output (Figure 3). It is also possible that the beneficial effects of adjunct inhaled epoprostenol may relate to favorable modifications in systemic inflammation, as well as its previously described antiplatelet effect [9]. Cumulatively, we hypothesize that inhaled epoprostenol contributed to cardiopulmonary stabilization, permitted early weaning of systemic inotrope support, improved echocardiographic RV systolic function, and sustained improvements in MAP. Furthermore, by using a nebulized rather than intravenous formulation of prostacyclin, the risks of systemic

hypotension and hypoxemia through ventilation-perfusion mismatch were minimized.

Fortunately, many patients with RV infarction develop spontaneous improvement in hemodynamics and RV function without development of chronic right heart failure. This is due in part to the RV's lower overall oxygen-requirement when compared with the left ventricle, as well as a dual blood supply system that perfuses the RV in both diastole and systole [1]. Although management recommendations for larger populations cannot be drawn from a single case, the rapid improvement of our patient following initiation of epoprostenol suggests a clinical benefit in this case. The current case provides proof of principle for the benefit of epoprostenol in acute right

ventricular infarction and failure, but additional clinical experience is necessary to draw robust conclusions.

## Conclusions

This case highlights the importance of recognizing new RBBB as a potential sign of RV infarction, and the potential usefulness of inhaled epoprostenol for management of acute RV cardiogenic shock.

## Conflict of interest

None declared.

## References:

1. Goldstein J: Pathophysiology and management of right heart ischemia. *J Am Coll Cardiol*, 2002; 40(5): 841–53
2. Inohara T, Kohsaka S, Fukuda K, Menon V: The challenges in the management of right ventricular infarction. *Eur Heart J: Acute Cardiovasc Care*, 2013; 2(3): 226–234.
3. Celik M, Iyisoy A, Celik T. Intermittent right bundle branch block development in a patient with acute inferior myocardial infarction. *Int J Cardiol*, 2011; 150(3): 121–23
4. Melgarejo-Moreno A, Galcerá-Tomás J, García-Alberola A et al: Incidence, clinical characteristics, and prognostic significance of right bundle-branch block in acute myocardial infarction. A study in the thrombolytic era. *Circulation*, 1997; 96(4): 1139–44
5. Xiang L, Zhong A, You T et al: Prognostic significance of right bundle branch block for patients with acute myocardial infarction: A systematic review and meta-analysis. *Med Sci Monit*, 2016; 22: 998–1004
6. Kurisu S, Inoue I, Kawagoe T et al: Right bundle-branch block in anterior acute myocardial infarction in the coronary intervention era: Acute angiographic findings and prognosis. *Int J Cardiol*, 2007; 116(1): 57–61
7. Futami C, Tanuma K, Tanuma Y, Saito T: The arterial blood supply of the conducting system in normal human hearts. *Surg Radiol Anat*, 2003; 25: 42–49
8. Ventetuolo CE, Klinger JR: Management of acute right ventricular failure in the intensive care unit. *Ann Am Thorac Soc*, 2014; 11(5): 811–22
9. Hill NS, Preston IR, Roberts KE: Inhaled therapies for pulmonary hypertension. *Respir Care*, 2015; 60(6): 794–805
10. De Wet CJ, Affleck DG, Jacobsohn E et al: Inhaled prostacyclin is safe, effective, and affordable in patients with pulmonary hypertension, right heart dysfunction, and refractory hypoxemia after cardiothoracic surgery. *J Thorac Cardiovasc Surg*, 2004; 127: 1058–67
11. McGinn K, Reichert M: A comparison of inhaled nitric oxide versus inhaled epoprostenol for acute pulmonary hypertension following cardiac surgery. *Ann Pharmacother*, 2016; 50(1): 22–26