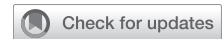

Type A aortic dissection following a tetralogy of Fallot repair



Monicka Shehata, MBBS,^a Ryan Bashir, MBBS,^a Bassel Al-Alao, MD, FRCSI,^a M. Yousuf Salmasi, PhD, MBBS, MRCS,^a George Asimakopoulos, PhD, FRCS,^a and Andreas Hoschtitzky, MSc, FRCS,^b London, United Kingdom

From the Departments of ^aCardiac Surgery and ^bCongenital Cardiac Surgery, Royal Brompton Hospital, London, United Kingdom.

Drs Shehata and Bashir contributed equally to this article.

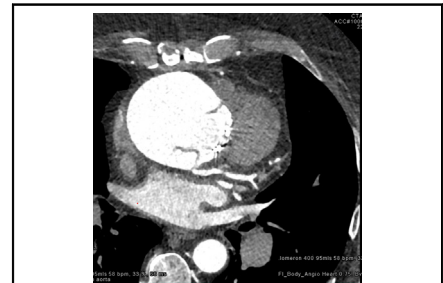
Received for publication June 15, 2023; revisions received Aug 15, 2023; accepted for publication Aug 16, 2023; available ahead of print Sept 26, 2023.

Address for reprints: Andreas Hoschtitzky, MSc, FRCS, Department of Congenital Cardiac Surgery, Royal Brompton Hospital, Sydney St, Chelsea, London, SW3 6NP United Kingdom (E-mail: a.hoschtitzky@rbht.nhs.uk).

JTCVS Techniques 2023;22:145-6
2666-2507

Copyright © 2023 The Authors. Published by Elsevier Inc. on behalf of The American Association for Thoracic Surgery. This is an open access article under the CC BY-NC-ND license (<http://creativecommons.org/licenses/by-nc-nd/4.0/>).

<https://doi.org/10.1016/j.xjtc.2023.09.021>



Dilated aortic root measuring 7 cm with dissection flaps.

CENTRAL MESSAGE

An underlying TOF aortopathy may predispose to the rare occurrence of a type A aortic dissection following a TOF repair.

Progressive aortic root dilatation has been noted following repair of complex congenital heart diseases such as tetralogy of Fallot (TOF).¹ Whilst aortic root dilatation has been recognized as a complication of conotruncal anomalies, type A aortic dissection (TAD) is an exceptionally rare complication with only 7 individual case reports in the literature from 2005 to 2022.² Eleven further cases have been identified in the National Inpatient Sample Database of TAD cases amongst all hospital admissions in adults with repaired tetralogy of Fallot (TOF) from 2000 to 2014.³ Although the true incidence for TAD in post-TOF repair remains unknown, an estimated figure sits at approximately 6 in 10,000.

CASE REPORT

A 55-year-old man with a background of essential hypertension, depression, smoking, and stress underwent a TOF repair (at age 3 years). He had a secondary operation (at age 54 years) to repair a residual ventricular septal defect alongside an aortic valve replacement (Edwards Lifesciences Inspiris Resilia valve) for regurgitation and relief of a right ventricular outflow tract obstruction, from which he recovered well. Although a dilated root of 52 mm was noted preoperatively, dissection flaps were initially absent and intervention was deemed unnecessary as per the Adult Congenital Heart Disease multidisciplinary team meeting.

INVESTIGATIONS

An incidental finding of a large aortic root was found on a routine yearly follow-up transthoracic echocardiogram. The ejection fraction was noted at 41%. He had mild left ventricular hypertrophy with mildly reduced left ventricular

systolic function and regional wall motion abnormality. The aortic root was dilated at 7 cm.

A subsequent computed tomography aortogram confirmed the presence of a subacute proximal aortic dissection, classified as a limited DeBakey type II, with dissection flaps particularly close to the left mainstem artery. Close to the posterior aspect of the sternal body, the ascending aorta measured 7.8 × 7.2 cm. The patient was otherwise asymptomatic and was managed with oral antihypertension agents to optimize hemodynamic parameters. A further computed tomography angiogram confirmed an unobstructed left main stem and a compromised ostium, although a separate small conal branch arising from the right-sided sinus was no longer identifiable.

MANAGEMENT

Cardiopulmonary bypass consisted of left femoral-to-femoral cannulation and an additional superior vena cava cannula. Thoracic cavity access required a repeat third sternotomy. The dissection was repaired with resection of the dissected aorta, sandwich repair of the base of the aortic root, repair of the left main stem coronary artery, and an interposition tube graft (32 mm Gelweave; Terumo Aortic). Due to postoperative right ventricular dysfunction, his chest wound was stented and closed 3 days later. A postoperative

transthoracic echocardiogram revealed an ascending aorta of normal diameter and a moderately to severely dilated right ventricle with severely reduced systolic function. The aortic annulus measured 2.7×2.4 cm and no aortic insufficiency was detected. A small ventricular septal defect was noted.

Postoperative complications included arrhythmias, sepsis, acute renal failure, right ventricular failure, and stroke. He required pharmacological and electrical cardioversion for atrial fibrillation associated with runs of ventricular tachycardia and hemodynamic instability. Varied antimicrobial therapy was required for recurrent episodes of pyrexia and rising inflammatory markers of 6 weeks' duration. Sputum cultures were positive for *Escherichia coli* and repeat bronchoalveolar lavage was positive for *Pseudomonas aeruginosa*.

On serial imaging, he was found to have a subacute left parieto-occipital stroke believed to be embolic in nature, with a small subarachnoid hemorrhage and a further small right occipital infarct. The patient recovered well with almost no residual neurological deficit. He had a mildly raised C-reactive protein of 13 mg/L and was in rate-controlled atrial fibrillation at ongoing 6-monthly follow-up.

DISCUSSION

Of the 7 cases reported, 5 describe an acute presentation of an ascending aorta dissection on a background of TOF, whilst only 2 describe a subacute presentation.² Ascending aorta dimensions ranged from 5.5 to 9.3 cm. Four cases were of men in their 30s, 2 in their 60s, and 1 18-year old⁴ (with 22q11 deletion syndrome). Whilst dissection remains a rare phenomenon, dilatation of the aortic root following repair of TOF is well reported in an enlarging population of patients. As this is usually asymptomatic⁵ routine follow-up is crucial. If permissible, valve-sparing operations are favored for this cohort of patients due to advantages such as anticoagulation avoidance and durability. Although an aortic valve replacement may predispose to

aortic dissection, a preexisting dilated aortic root suggests that TOF aortopathy was the most likely contributing disease process. Cardiovascular risk factors such as uncontrollable hypertension, obesity, as well as underlying anxiety were likely contributing factors to TOF aortopathy in this case.

CONCLUSIONS

Continued surveillance of patients with TOF repair is crucial to identifying those with further aortic complications. Pathological aortic features present in this patient cohort seem to form the basis of dilated aortic pathologies post-TOF repair.

The subject provided informed written consent for the publication of the study data; institutional review board approval was not required.

Conflict of Interest Statement

The authors reported no conflicts of interest.

The *Journal* policy requires editors and reviewers to disclose conflicts of interest and to decline handling manuscripts for which they may have a conflict of interest. The editors and reviewers of this article have no conflicts of interest.

References

1. Rathi VK, Doyle M, Williams RB, Yamrozik J, Shannon RP, Biederman RW. Massive aortic aneurysm and dissection in repaired tetralogy of Fallot; diagnosis by cardiovascular magnetic resonance imaging. *Int J Cardiol*. 2005; 101:169-70.
2. Vaikunth SS, Chan JL, Woo JP, Bykhovsky MR, Lui GK, Ma M, et al. Tetralogy of Fallot and aortic dissection: implications in management. *JACC Case Rep*. 2022;4: 581-6.
3. Egbe AC, Crestanello J, Miranda WR, Connolly HM. Thoracic aortic dissection in tetralogy of Fallot: a review of the National Inpatient Sample Database. *J Am Heart Assoc*. 2019;8:e011943.
4. Konstantinov IE, Fricke TA, d'Udekem Y, Robertson T. Aortic dissection and rupture in adolescents after tetralogy of Fallot repair. *J Thorac Cardiovasc Surg*. 2010;140:e71-3.
5. Buratto E, Konstantinov IE. Valve-sparing aortic root surgery in children and adults with congenital heart disease. *J Thorac Cardiovasc Surg*. 2021;162:955-62.