

# Widespread presentation and spontaneous regression of porokeratotic eccrine ostial and dermal duct nevus



Stephanie Petkiewicz, MDCM, PhD,<sup>a</sup> Julia Baltz, MD,<sup>b</sup> Kristine Cornejo, MD,<sup>c</sup>  
April Deng, MD, PhD,<sup>c</sup> and Karen Wiss, MD<sup>b</sup>  
Ottawa, Canada, and Worcester, Massachusetts

**Key words:** Porokeratotic eccrine ostial and dermal duct nevus; porokeratosis; resolution.

## INTRODUCTION

Porokeratotic eccrine ostial and dermal duct nevus (PEODDN) is an uncommon hamartomatous growth with disordered keratinization. The lesions typically appear on the limbs, often at birth or in early childhood, as linearly distributed papules and plaques. When involving the palms or soles, keratotic plugs are often seen. PEODDN is typically unilateral; however, bilateral involvement has been reported. Lesions often persist over time with rare reports of associated malignancies.<sup>1-3</sup> Treatment is challenging and options include erbium/carbon dioxide (CO<sub>2</sub>) lasers, keratolytic agents, and surgical excision.<sup>4</sup> Cases of PEODDN have been reported in association with deafness, polyneuropathy and hyperthyroidism, seizure disorder, and hemiparesis.<sup>4</sup> Most patients are healthy, however, and these associations may be coincidental. Histologically, the lesions show epidermal hyperplasia with cornoid lamellae located over the eccrine ostia. PEODDN is believed to be caused by somatic mutation and mosaic expression of mutated *GJB2* gene that encodes the gap junction protein connexin 26.<sup>5</sup> The term *porokeratotic adnexal ostial nevus* has been suggested to describe both the PEODDN and the related lesion, porokeratotic eccrine and hair follicle nevus (PEHFN).<sup>2</sup> We report 4 cases of PEODDN, 2 of which showed significant spontaneous regression.

### Abbreviations used:

CO <sub>2</sub> :	carbon dioxide
PEHFN:	porokeratotic eccrine and hair follicle nevus
PEODDN:	Porokeratotic eccrine ostial and dermal duct nevus

## CASE REPORTS

### Patient 1

A 1-week-old girl was seen for congenital verrucous plugged papules and plaques in a blaschkoid distribution on the right trunk and limbs (Fig 1, A). By 3 months of age, the lesions had become less pronounced but still involved much of the hemibody. By 15 months of age (Fig 1, B), the original lesions had faded even further, leaving subtle linear verrucous papules and plaques. There was complete resolution on multiple body areas. The lesions continue to be asymptomatic, and no treatment has been undertaken.

### Patient 2

A 5-day-old boy was referred for evaluation of Blaschkoid verrucous plugged papules coalescing into linear plaques on the right arm extending from the shoulder to the wrist measuring approximately 15 cm in length. There was a similar linear collection of papules on his right lower back. By 7 months of age, there was significant spontaneous clinical

From the Department of Pathology and Laboratory Medicine, University of Ottawa, The Ottawa Hospital<sup>a</sup> and the Departments of Dermatology<sup>b</sup> and Pathology,<sup>c</sup> University of Massachusetts Medical School, UMass Memorial Healthcare.

Funding sources: None.

Conflicts of interest: None disclosed.

Three of the 4 cases were previously presented at the American Society of Dermatopathology Annual Meeting, San Francisco, California, October 8-11, 2015.

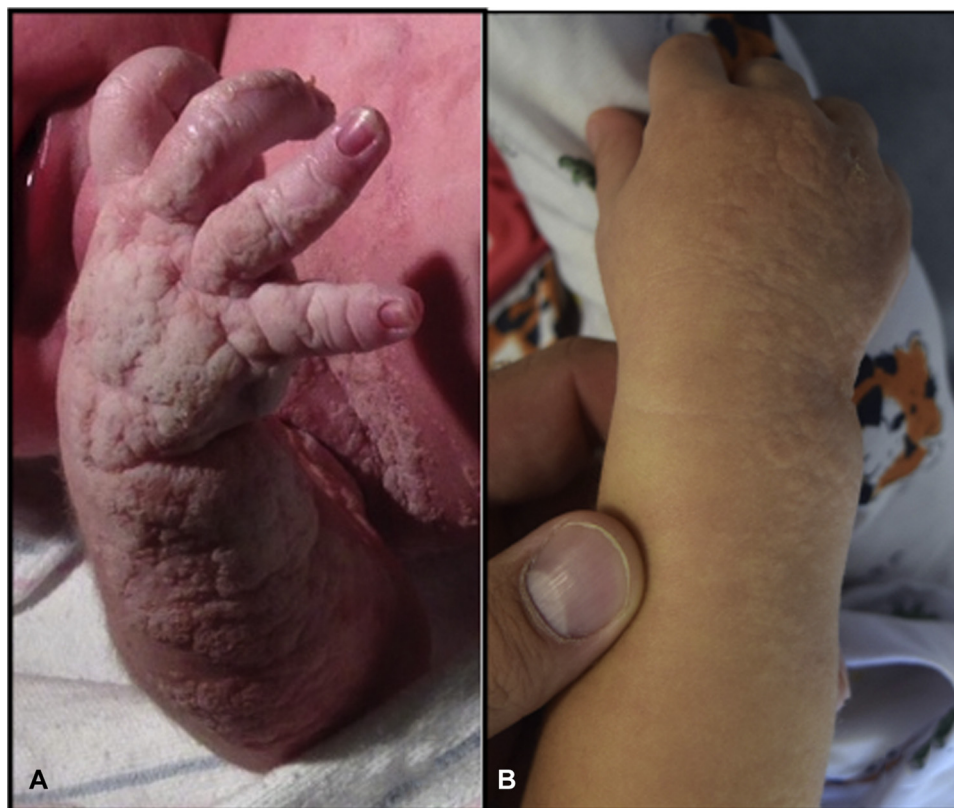Correspondence to: Stephanie Petkiewicz, MD, CM, PhD, FRCPC, Pathologist, The Ottawa Hospital, 4th Floor CCW, Room W4223,

501 Smyth Road, Ottawa, ON K1H 8L6. E-mail: [Spetkiewicz@toh.on.ca](mailto:Spetkiewicz@toh.on.ca).

JAAD Case Reports 2018;4:972-5.  
2352-5126

© 2018 by the American Academy of Dermatology, Inc. Published by Elsevier, Inc. This is an open access article under the CC BY-NC-ND license (<http://creativecommons.org/licenses/by-nc-nd/4.0/>).

<https://doi.org/10.1016/j.jidcr.2018.08.001>



**Fig 1.** **A**, PEODDN. Patient 1: stippled verrucous papules in a blaschkoid distribution over the hand and forearm seen at birth. **B**, Patient 1: Marked decrease in linear papules and plaques seen at 15 months of age.

improvement, with thin, less than 1-mm papules scattered over the right forearm.

### Patient 3

A 15-year-old girl reported congenital onset of tan, hyperkeratotic, linear verrucous papules involving the left dorsal hand, forearm, and breast. On the thumb showed pink papules with central hyperkeratotic plugs. She attempted treatment with 40% topical urea cream and pulsed dye laser with no improvement. CO<sub>2</sub> laser was attempted with some improvement in appearance, but she had anxiety about further procedures and was lost to follow up.

### Patient 4

A 40-year-old man had hyperkeratotic papules in the axilla. The age of onset was unknown.

### SUMMARY OF CASES

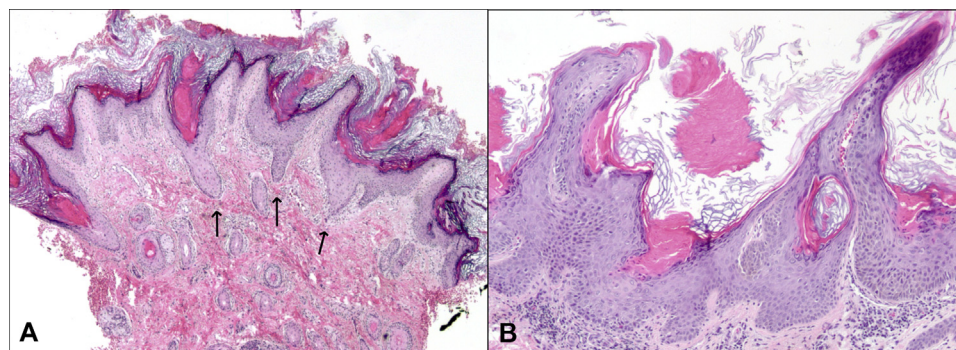
All 4 of these patients had similar histologic findings. Both biopsies from patient 3 were superficial with only minimal epidermis but were characterized by hyperorthokeratosis and columns of parakeratosis. The first, third, and fourth cases showed

papillomatous epidermal hyperplasia with invaginations containing cornoid lamellae overlying areas of diminished granular cell layer and occasional dyskeratotic cells. The cornoid lamellae were located over eccrine duct ostia (Fig 2). Histochemical staining with periodic acid–Schiff and immunohistochemical staining with monoclonal carcinoembryonic antigen highlighted the underlying eccrine ostia.

### DISCUSSION

Upon review of the literature, there are at least 81 reported cases of PEODDN. Many of these cases had onset at birth and most involved a single limb. Our first case is unusual in the extent of involvement of nearly the entire hemibody. Other cases have been reported with hemibody<sup>6,7</sup> and generalized involvement<sup>8</sup>; however, this is quite uncommon. Dramatic improvement, as seen in our first 2 cases, has been reported previously in both PEODDN<sup>7,9</sup> and PEHFN<sup>10</sup> (Table I), however this phenomenon appears to be uncommon with most lesions remaining stable over the patient's life.

The clinical differential diagnosis for PEODDN includes linear verrucous epidermal nevus,



**Fig 2.** PEODDN histologic features. **A**, PEODDN shows cornoid lamellae arising over the eccrine ducts (arrows). **B**, Loss of the granular cell layer and dyskeratotic cells are noted at the base of the cornoid lamellae. (**A** and **B**, Hematoxylin-eosin stain; original magnifications: **A**,  $\times 4$ ; **B**,  $\times 10$ .)

**Table I.** Cases of prokeratotic adnexal ostial nevus with reports of spontaneous regression

Study	Gender	Age onset	Location	Timeframe
Current study, patient 1	F	Birth	Right hemibody trunk/limbs	Improved within first few months of life
Current study, patient 2	M	Birth	Right lower back and right arm-shoulder to wrist	Improved within first few months of life
Agulló-Pérez et al <sup>10,*</sup>	F	Birth	Scalp, trunk, right arm, and leg and feet	Scalp trunk and limbs involuted over 2 years; back, foot, and sole lesions more hyperkeratotic
Aloi and Pippione <sup>9</sup>	F	Birth	Widespread—bilateral hands, feet, arms, axillae	Palms and soles unchanged; reduced hyperkeratosis of limb lesions
Mazuecos et al <sup>7</sup>	F	Birth	Right hemibody	Most regressed over 26 years

\*Report by Agulló-Perez was a PEHFN.

inflammatory linear verrucous epidermal nevus, nevus comedonicus, punctate palmoplantar keratoderma, and linear porokeratosis. PEODDN can be distinguished clinically by the stippled appearance clinically and the cornoid lamellae overlying the eccrine duct ostia histologically. The pathologic differential diagnosis includes linear porokeratosis, epidermal nevus with cornoid lamellae, and PEHFN. In all these entities, however, the cornoid lamellae are not located over the eccrine duct ostia.

Treatment of PEODDN is challenging. Topical corticosteroids, retinoids, and keratolytics have been attempted with limited success. Clinical improvement has been most consistently reported with CO<sub>2</sub> laser.<sup>1,4,11-13</sup> Improvement has also been reported with topical tretinoin (0.5%) cream with urea (10%)<sup>14</sup> and topical photodynamic therapy with aminolevulinic acid.<sup>15</sup> The 2 infants described here had significant spontaneous improvement in clinical appearance despite widespread involvement noted at birth. This natural regression has been previously reported<sup>8-10</sup> and may be important information for clinicians as well as new parents of children with PEODDN.

#### REFERENCES

- Coras B, Vogt T, Roesch A, Landthaler M, Hohenleutner U. Bowen's disease on porokeratotic eccrine ostial and dermal duct nevus. *Dermatol Surg Off Publ Am Soc Dermatol Surg Al.* 2007;33(4):496-499.
- Goddard DS, Rogers M, Frieden IJ, et al. Widespread porokeratotic adnexal ostial nevus: clinical features and proposal of a new name unifying porokeratotic eccrine ostial and dermal duct nevus and porokeratotic eccrine and hair follicle nevus. *J Am Acad Dermatol.* 2009;61(6):1060.e1-1060.e14.
- Nassiri N, Hansen J. Diffuse squamous cell carcinoma in porokeratotic eccrine ostial and dermal duct nevus. *Plast Reconstr Surg.* 2009;123(2):87e-88e.
- Llamas-Velasco M, Hilty N, Kempf W. Porokeratotic adnexal ostial naevus: review on the entity and therapeutic approach. *J Eur Acad Dermatol Venereol.* 2015;29(10):2032-2037.
- Easton JA, Donnelly S, Kamps MAF, et al. Porokeratotic eccrine nevus may be caused by somatic connexin26 mutations. *J Invest Dermatol.* 2012;132(9):2184-2191.
- Dogra S, Jain R, Mohanty SK, Handa S. Porokeratotic eccrine ostial and dermal duct nevus: unilateral systematized involvement. *Pediatr Dermatol.* 2002;19(6):568-569.
- Mazuecos J, Ortega M, Ríos JJ, Camacho F. Long-term involution of unilateral porokeratotic eccrine ostial and dermal duct naevus. *Acta Derm Venereol.* 2003;83(2):147-149.
- Cobb MW, Vidmar DA, Dilaimy MS. Porokeratotic eccrine ostial and dermal duct nevus: a case of systematized involvement. *Cutis.* 1990;46(6):495-497.

9. Aloï FG, Pippione M. Porokeratotic eccrine ostial and dermal duct nevus. *Arch Dermatol*. 1986;122(8):892-895.
10. Agulló-Pérez AD, Resano-Abarzuza MÁ, Córdoba-Iturriagagoitia A, Yanguas-Bayona JI. Porokeratotic eccrine and hair follicle nevus: a report of two cases and review of the literature. *An Bras Dermatol*. 2017;92(5 Suppl 1):121-125.
11. Zade J, Jfri A, Nabatian A, Alajaji A, Geller L, Khorasani H. Porokeratotic eccrine ostial and dermal duct nevus: a unique case treated with CO2 laser. *Clin Case Rep*. 2017;5(5):675-678.
12. Jain S, Sardana K, Garg VK. Ultrapulse carbon dioxide laser treatment of porokeratotic eccrine ostial and dermal duct nevus. *Pediatr Dermatol*. 2013;30(2):264-266.
13. Leung CS, Tang WY, Lam WY, Fung WK, Lo KK. Porokeratotic eccrine ostial and dermal duct naevus with dermatomal trunk involvement: literature review and report on the efficacy of laser treatment. *Br J Dermatol*. 1998;138(4):684-688.
14. Bhunia D, Ghosh S, Rudra O, Biswas SK. Porokeratotic eccrine ostial and dermal duct nevus - revisited. *Dermatol Online J*. 2014;20(9).
15. Kim WJ, Choi SR, Lee HJ, Kim DH, Yoon MS. Porokeratotic eccrine ostial and dermal duct nevus showing partial remission by topical photodynamic therapy. *Ann Dermatol*. 2011;23(Suppl 3):S322-S325.