



## Case report

## Acute angle closure in an aphakic infant: Case report and review of the literature

Lily Okrent Smolar<sup>a,b,\*</sup>, Anfisa Ayalon<sup>a,b</sup>, Noa Ela-Dalman<sup>a,b</sup>, Elad Moisseiev<sup>a,b</sup><sup>a</sup> Department of Ophthalmology, Meir Medical Center, Kfar Saba, Israel<sup>b</sup> Sackler School of Medicine, Tel Aviv University, Tel Aviv, Israel

## ARTICLE INFO

## Keywords:

Aphakic pupillary block  
 Pediatric aphakic glaucoma  
 Congenital cataract  
 Posterior peripheral vitrectomy

## ABSTRACT

**Purpose:** Aphakic pupillary block glaucoma is a rare complication after congenital cataract surgery. We describe the case of an infant with acute angle closure in an aphakic eye following congenital cataract lensectomy with anterior vitrectomy nine months prior. Potential pathophysiology and therapeutic strategies are discussed.

**Observations:** A one-year-old male infant presented to our emergency unit with right eye injection and pain. At the age of six weeks he had undergone right eye lensectomy with anterior vitrectomy for congenital cataract and was left aphakic with large anterior and posterior capsulorrhexis. Examination was significant for a shallow anterior chamber centrally and iridocorneal touch of the periphery for 360° with intraocular pressure (IOP) measured at 70 mmHg. The child was diagnosed with aphakic pupillary block leading to an acute angle closure event. He underwent emergent anterior vitrectomy with surgical peripheral iridotomy (PI) performed via pars plana approach. This resulted in immediate deepening of the anterior chamber, with resolution of the pupillary block and iridocorneal touch. Thereafter, his ocular exam was normal.

**Conclusions and Importance:** This unusual case underscores the importance of vigilance in the postoperative management of children after congenital cataract extraction. Unexpected complications remain a threat despite the initial undertaking of preventative measures.

## 1. Introduction

The timing of congenital cataract removal remains controversial, with judicious consideration necessary regarding the risk of deprivation amblyopia weighed against that of glaucoma and other known complications. The appropriate window for removal was implicated at four to six weeks of age by earlier works,<sup>1</sup> and this recommendation is often implemented today. Glaucoma is a common complication following congenital cataract extraction in both pseudophakic and aphakic infantile eyes. Significant risk factors for its development are anatomical anomalies, such as maldevelopment and abnormal iridocorneal angle anatomy.<sup>2</sup> In the absence of such anomalies, other risk factors include microcornea and age at extraction younger than 9 months.<sup>2,3</sup> Reports in the literature vary regarding the role of primary intraocular lens (IOL) implantation and its timing in the development of post-extraction glaucoma in these children, and these matters remain controversial.<sup>1–4</sup> Post-congenital cataract extraction glaucoma is most often characterized by an open angle. Its pathogenesis is poorly understood, but previous works implicate patient-related factors such as congenital anomalies and abnormal ocular development as mentioned above, or a

complication of surgical technique or anatomical damage incurred.<sup>2,3</sup>

Acute angle closure glaucoma and pupillary block glaucoma in aphakic infants is currently exceedingly rare. Described in only a handful of cases in the literature, it occurs most often in the first months to one year of the postoperative period.<sup>2,3,5</sup> In previous works, this complication has been ascribed to surgically-related factors including retention of lens material leading to proliferation of Elschnig pearls, sulcus placement in IOL implantation, failure to perform anterior vitrectomy or laser iridotomy (LI), damage to the angle, or patient factors such as microcornea and other congenital abnormalities.<sup>2,6</sup> In adults, aphakic angle closure is often due to pupillary block by the anterior vitreous face. In infants left aphakic after congenital cataract extraction, anterior vitrectomy with or without posterior capsulorrhexis is often done at the time of cataract removal as a preventative measure.<sup>2</sup> We describe the case of an infant who presented with acute angle closure in an aphakic eye following congenital cataract extraction nine months prior, having undergone anterior vitrectomy during the same procedure.

\* Corresponding author. Meir Medical Center, Tchernichovsky 59, Kfar-Saba, 44281, Israel.

E-mail address: [alokrent@gmail.com](mailto:alokrent@gmail.com) (L.O. Smolar).

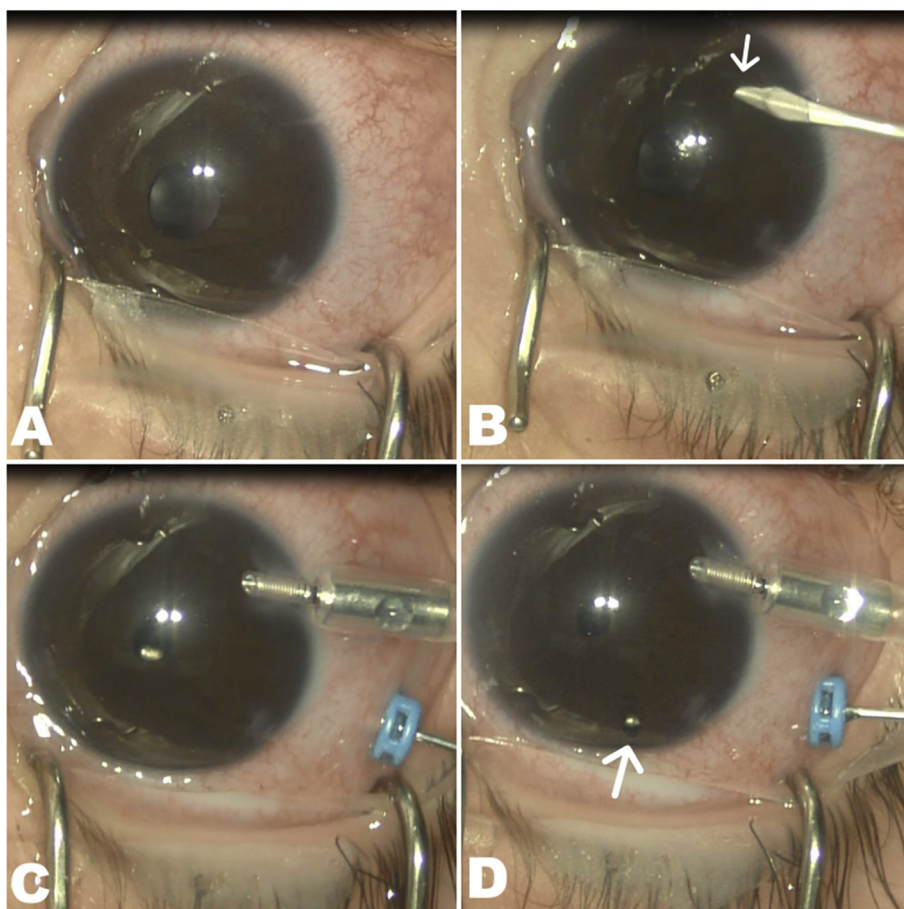
<https://doi.org/10.1016/j.ajoc.2019.100459>

Received 25 February 2019; Received in revised form 17 April 2019; Accepted 24 April 2019

Available online 01 May 2019

2451-9936/© 2019 The Authors. Published by Elsevier Inc. This is an open access article under the CC BY-NC-ND license

(<http://creativecommons.org/licenses/by-nc-nd/4.0/>).



**Fig. 1.** Treatment of acute aphakic angle closure event.

A. Initial shallow AC with peripheral iridocorneal touch and non-reactive pupil.

B. Iridocorneal touch can be appreciated by noting burial of the blade tip in the iris upon penetration of the cornea (arrow).

C. Vitrectomy performed posterior to the pupil results in immediate deepening of the AC and miosis, resolving peripheral touch.

D. PI is performed posterior to the iris via the pars plana incision with the vitrectome, which can be seen through the PI (arrow).

## 2. Case report

A one-year-old male infant presented to our emergency unit with redness of the right eye, eye rubbing and decreased appetite since the preceding evening. His past ocular history was significant for lensectomy with wide anterior vitrectomy for congenital cataract in the same eye at the age of six weeks, without evidence of PFV. The child had been left aphakic following anterior and posterior capsulorrhexis with anterior vitrectomy and was treated with patching and a contact lens. On presentation the child was lethargic, and his examination was notable for conjunctival injection with mild diffuse microcystic corneal edema, a shallow anterior chamber (AC) centrally and iridocorneal touch of the periphery for 360°. The pupil was fixed and mid-dilated. The eye was tense to palpation, and intraocular pressure (IOP) was measured by tonopen as 70 mmHg in the right eye, and 16 mmHg in the left, which was quiet with a deep AC.

The diagnosis of acute angle closure was made, with suspected pupillary block as its cause (Fig. 1a). Notably, Cosopt (Timolol + Dorzolamide) was ineffective in decreasing the IOP, neither was pilocarpine administered pre-operatively effective in constricting the pupil or deepening the AC. The child was taken emergently to the operating room for surgical repair under general anesthesia. A single paracentesis was made to accommodate an anterior chamber infusion maintainer (Fig. 1b), and a single 25-gauge pars plana sclerotomy was made temporally. A vitrectomy probe was inserted and anterior vitrectomy was performed behind the pupil (Fig. 1c). Vitreous was observed in the pupil and removed, with instant deepening of the AC and pupillary constriction. Thereafter, a superior peripheral iridotomy (PI) was made using the vitrectomy probe from behind the iris, with extension of the anterior vitrectomy including posterior to the iridotomy site (Fig. 1d and Video 1). The paracentesis and sclerotomy sites were

sutured, and antibiotics administered. Following recuperation from the surgery and anesthesia, the infant was no longer lethargic and regained his appetite. On the first postoperative day, the AC was deep and quiet and IOP measured by ICare was 23 mmHg, and on follow up returned to within normal range and remained stable thereafter. Retinal hemorrhages were noted and were attributed to the abrupt decrease in IOP, and all resorbed by two weeks postoperatively.

Supplementary video related to this article can be found at <https://doi.org/10.1016/j.ajoc.2019.100459>.

## 3. Discussion

Post-operative glaucoma is a known complication of congenital cataract extraction in the pediatric age group, in eyes having undergone IOL implantation and those left aphakic. In the Infant Aphakia Treatment Study, among the most common complications after lensectomy without intraocular lens implantation were glaucoma (16%) or glaucoma suspect (19%), contact lens related adverse events (18%), and less frequently such complications as vitreous hemorrhage (2%), retinal detachment (2%), retinal hemorrhage (2%), and retained cortex (2%).<sup>4</sup> When it occurs, the complication of glaucoma and/or high IOP is most often characterized by an open-angle.<sup>3,4</sup> In the Infant Aphakia Treatment Study, it was defined by IOP > 21 mmHg and one of the following: increased corneal diameter, myopic shift with corneal or axial length enlargement, optic nerve cupping  $\geq 0.2$ , or utilization of IOP lowering surgery. These diagnostic criteria implicate a subacute or chronic mechanism of increased IOP in these pediatric eyes. In our case, the absence of buphthalmos without pathological optic disc cupping was notable, implying that this was either the first or one of few such episodes, and that the mechanism of increased IOP was an acute rather than chronic one.

The occurrence of this complication nine months following the initial procedure is unusual in the current era of congenital cataract extraction in which anterior vitrectomy is commonly employed, and early studies describing acute angle closure in infants following congenital cataract extraction were either in non-vitrectomized eyes, or at a period immediately following the initial procedure. The topic was summarized neatly by Chen et al., demonstrating that these studies were amongst the first to suggest and establish the importance of anterior vitrectomy at the time of extraction.<sup>7</sup> As the parents were extremely wary and brought their child in promptly after detecting a red eye, it is unlikely that there were grossly detectable prior events, and on follow up exam the angle was open and free of synechiae. The complication of acute angle closure months following lensectomy and aphakia, as seen with our patient, is not described in the current, larger studies,<sup>3,4</sup> and is now an exceedingly rare complication in this patient population.

Pupillary block glaucoma in aphakia is rare complication in which the pathogenesis is not fully understood. There are few existing theories regarding angle closure in aphakia. Hitchings suggested that pupillary block can be caused by intact, broken or prolapsed anterior hyaloid through the posterior capsulotomy, causing irido-vitreous contact and obstruction of forward aqueous flow, and described seven cases in which iridectomy failed to cure the pupillary block, but incision of anterior hyaloid together with posterior synechiolysis had good results.<sup>8</sup> Shah reported an adult patient who had undergone congenital cataract surgery at the age of seven weeks and remained aphakic, who developed acute angle closure and was effectively treated with anterior vitrectomy.<sup>9</sup> In these examples, anterior vitrectomy was not initially done, and the anterior hyaloid was presumably intact. In our case, acute angle closure occurred in an aphakic eye following congenital cataract extraction despite the performance of anterior vitrectomy.

Another option is that pupillary block aphakic angle closure results from retention of lens material. It has been recommended to perform PI for prophylaxis in the event that lens material is suspected to have remained.<sup>2,6</sup> In our patient, peripheral iridotomy was not done at the time of the initial procedure as the lens material was fully removed. After wide anterior and posterior capsulorhexis, the capsular bag was left within the eye in order to allow more versatility in secondary IOL implantation. Likewise, wide prophylactic anterior vitrectomy was utilized in order to avoid pupillary block by the anterior hyaloid in the future. However, angle closure still occurred, the pattern of which seems to implicate pupillary block by a vitreous fragment or strand. This assumption is based upon the depth of the central anterior chamber relative to that of the periphery, where there was iridocorneal contact. Furthermore, pars plana vitrectomy (with simultaneous anterior chamber infusion) directly behind the pupil immediately deepened the entire anterior chamber, with constriction of the pupil presumably in response to previously administered pilocarpine. The peripheral iridotomy was then undertaken holding the vitrectome immediately posterior to the iris, with tissue removed in a posterior to anterior direction.

This technique of anterior vitrectomy and posterior PI via a single-port pars plana approach was described only once prior in the literature. In a series of five patients with malignant glaucoma reviewed retrospectively, Bitrian & Caprioli performed peripheral hyaloido-zonulectomy and PI utilizing only anterior vitrectomy equipment through a pars plana incision with simultaneous anterior chamber infusion.<sup>10</sup> Some key differences between their article and this case exist. First, their cases were pseudophakic adults with malignant glaucoma, whereas ours is an aphakic child with pupillary block. Second, in our case the trans-conjunctival approach was used, rather than the peritomy described in their series. Finally, in our case, although it is likely that some zonules were severed in the process, we did not intentionally create a zonulectomy. The success of this procedure demonstrates the efficacy and efficiency of this novel method of producing a surgical PI.

We suggest that the clinical picture of aphakic angle closure in our

pediatric patient can be attributed to anterior movement of the vitreous body or strands thereof, causing pupillary block and secondary angle closure. This etiology could explain why the administration of pilocarpine was not effective. Firstly, pilocarpine is known to be ineffective at high pressures, presumably due to ischemia of the iris sphincter and thus its inability to contract. Secondly, when the cause of pupillary block is the vitreous, contraction of the pupil would serve to further entrap the vitreous, whereas pupil dilation would free the vitreous and thus eliminate the source of the block.<sup>9</sup> Although the presence of an IOL could theoretically have prevented this particular complication, pseudophakic infants have been shown to suffer from glaucoma at similar rates, and more from all other examined complications in general, than aphakic ones in the Infant IOL Complications Study.<sup>4</sup> Therefore, when congenital cataract extraction is performed at 6 weeks of age, as it was in our patient, it is recommended to perform lensectomy and anterior vitrectomy without IOL implantation.

#### 4. Conclusions

This case demonstrates the rare, late postoperative complication of aphakic angle-closure glaucoma nine months into the postoperative period, treated effectively surgically via PPV with posterior PI. It highlights the importance of a thorough anterior vitrectomy at the time of cataract extraction, and the possibility of unusual and unexpected complications in these children at any point post-operatively. Additionally, it demonstrates an elegant surgical technique suited to address the pathogenic mechanism of this unusual complication.

#### Patient consent

Consent to publish the case report was not obtained. This report does not contain any personal information that could lead to the identification of the patient.

#### Acknowledgments and disclosures

##### Funding

No funding or grant support

##### Conflicts of interest

The following authors have no financial disclosures: LOS, AA, NED, EM.

##### Authorship

All authors attest that they meet the current ICMJE criteria for Authorship.

#### Acknowledgements

None.

#### Appendix A. Supplementary data

Supplementary data to this article can be found online at <https://doi.org/10.1016/j.ajoc.2019.100459>.

#### References

1. Birch EE, Stager DR. The critical period for surgical treatment of dense congenital unilateral cataract. *Investig Ophthalmol Vis Sci.* 1996;37(8):1532–1538.
2. Koc F, Kargi S, Biglan AW, Chu CT, Davis JS. The aetiology in paediatric aphakic glaucoma. *Eye.* 2005;20:1360 <https://doi.org/10.1038/sj.eye.6702150>.
3. Khan AO, Al-Dahmesh S. Age at the time of cataract surgery and relative risk for aphakic glaucoma in nontraumatic infantile cataract. *J Am Assoc Pediatr Ophthalmol*

- Strabismus*. 2009;13(2):166–169. <https://doi.org/10.1016/j.jaapos.2008.10.020>.
4. Plager DA, Lynn MJ, Buckley EG, Wilson ME, Lambert SR, Infant Aphakia Treatment Study Group. Complications in the first 5 years following cataract surgery in infants with and without intraocular lens implantation in the Infant Aphakia Treatment Study. *Am J Ophthalmol*. 2014 Nov;158(5):892–898.
  5. Zhu XJ, Zhang KK, He WW. Diagnosis of pupillary block glaucoma after removal of congenital cataracts with intraoperative ultrasound biomicroscopy: a case report. *BMC Ophthalmol*. 2016 May 17;16(1):58.
  6. Mills MD, Robb RM. Glaucoma following childhood cataract surgery. *J Pediatr Ophthalmol Strabismus*. 1994;31:355–360.
  7. Chen TC, Bhatia LS, Halpern EF, Walton DS. Risk factors for the development of aphakic glaucoma after congenital cataract surgery. *J Pediatr Ophthalmol Strabismus*. 2006 43(5):274–280.
  8. Hitchings RA. Acute aphakic pupil block glaucoma: an alternative surgical approach. *Br J Ophthalmol*. 1979 Jan;63(1):31–37.
  9. Shah BP, Clarke J. A 35-year-old woman presenting with pain, reduced right-eye vision, and headache. *Digit J Ophthalmol*. 2015 May 13;21(2):1–7.
  10. Bitrian E, Caprioli J. Pars plana anterior vitrectomy, hyaloido-zonulectomy, and iridectomy for aqueous humor misdirection. *Am J Ophthalmol*. 2010;150(1):82–87.