



# Educational Case: Yolk Sac (Endodermal Sinus) Tumor of the Ovary

Pouya Jamshidi, MD<sup>1</sup> and Jerome B. Taxy, MD<sup>1</sup>

*The following fictional case is intended as a learning tool within the Pathology Competencies for Medical Education (PCME), a set of national standards for teaching pathology. These are divided into three basic competencies: Disease Mechanisms and Processes, Organ System Pathology, and Diagnostic Medicine and Therapeutic Pathology. For additional information, and a full list of learning objectives for all three competencies, see <http://journals.sagepub.com/doi/10.1177/2374289520909497>.<sup>1</sup>*

## Keywords

pathology competencies, organ system pathology, female reproductive, ovarian neoplasia, yolk sac tumor, endodermal sinus tumor, Schiller-Duval body

Received June 5, 2019. Received revised January 3, 2020. Accepted for publication January 18, 2020.

## Primary Objective

*Objective FO1.2: Causes of Ovarian Neoplasm.* Describe the risk factors, genetic associations, and molecular basis, including hereditary cancer syndromes, for ovarian neoplasms, including those derived from epithelium, sex cord stromal as well as germ cell neoplasms.

Competency 2: Organ System Pathology, Topic FO: Female Reproductive—Ovary; Learning Goal 1: Ovarian Neoplasia.

## Patient Presentation

A 20-year-old female with no significant past medical history presented with progressive shortness of breath. Physical examination was notable for decreased breath sounds in lower half of the right chest, a distended abdomen with a palpable adnexal mass in the left lower abdomen extending 2 fingers below the umbilicus. Pelvic examination was remarkable for a large, mobile pelvic mass with fullness in posterior cul-de-sac.

## Diagnostic Findings, Part I

Computed tomography (CT) of the chest showed large right pleural effusion and trace left pleural effusion with associated atelectasis. Computed tomography of the abdomen and pelvis

revealed a large left adnexal mass with central necrosis and moderate amount of free fluid within the abdomen.

## Questions/Discussion Points, Part I

*What Is the Clinical Differential Diagnosis Based on the Physical Examination and Imaging Findings?*

Differential diagnosis of an adnexal mass in a young adult is very broad and should include benign ovarian cysts and masses (ie, corpus luteum cyst, follicular cyst, mature teratoma, polycystic ovaries, theca-lutein cyst etc) as well as malignant ovarian neoplasms (ie, borderline tumors, epithelial carcinoma, ovarian germ cell tumor, sex cord, or stroma tumor etc). One should also consider benign and malignant nonovarian entities, including ectopic pregnancy, hydrosalpinx, leiomyoma, tubo-

<sup>1</sup> Department of Pathology and Laboratory Medicine, Northshore University Health System, Evanston, IL, USA

## Corresponding Author:

Pouya Jamshidi, Department of Pathology and Laboratory Medicine, Northshore University Health System, 2650 Ridge Ave, Evanston, IL 60201, USA.

Email: [pjamshidi@northshore.org](mailto:pjamshidi@northshore.org)



**Table 1.** Summary of Ovarian Germ Cell Tumors and Their Clinicopathological Features.

Subtype	Frequency of Incidence	Benign/Malignant	Uni/Bi-Lateral	Serum Tumor Markers
Choriocarcinoma	Very rare	Malignant	Usually unilateral	βHCG
Dysgerminoma	35%-50%	Malignant	10%-15% bilateral	Serum LDH and serum βHCG
Endodermal sinus tumor (yolk sac)	20%	Malignant	Usually unilateral	AFP, alpha I-antitrypsin (rarely)
Embryonal carcinoma	Rare	Malignant	Usually unilateral	AFP and βHCG
Mixed germ cell tumor (GCT)	10%-15%	Depending based on the cell types present		Depending based on the cell types present
Teratoma	Immature (20%) of malignant GCT	Benign or malignant	10%-15% bilateral	Immature: AFP, serum LDH, CA-125

Abbreviations: AFP, α-fetoprotein; βHCG, β subunit human chorionic gonadotropin; CA-125, cancer antigen 125; LDH, lactate dehydrogenase.

ovarian abscess, to name a few. Similarly, benign and malignant nongynecologic etiologies should be considered including appendiceal abscess, nerve sheath tumor, pelvic kidney, gastrointestinal carcinoma (Krukenberg tumor), metastasis from breast, colon and so on.<sup>2,3</sup>

The presence of pleural effusion with ascites likely constitutes a Meigs syndrome, which is defined by a triad of an ovarian fibroma or fibroma-like tumor, pleural effusion, and ascites.<sup>4</sup>

### What Additional Laboratory Studies Should Be Performed?

A urine pregnancy test should be performed routinely in any woman of reproductive age who presents with an adnexal mass. If the pregnancy test is positive, a quantitative β subunit human chorionic gonadotropin (β-HCG) should be obtained. Several tumor markers are also available that may be helpful in the evaluation of patients with adnexal masses. Cancer antigen (CA)-125, lactate dehydrogenase (LDH), α-fetoprotein (AFP) should be obtained for initial assessment.<sup>5</sup> Additionally, fine needle aspirate of the pleural effusion should be considered, which may provide cytological diagnostic information.

### Diagnostic Findings, Part 2

Thoracentesis of the pleural effusion yielded cytology negative for malignancy. Cancer biomarkers including serum LDH (166; ref range: 84-246 U/L), CA-125 (29.2; ref range: 1.5-35.0 U/mL), and AFP (>15 000; ref range: 0.5-8.0 ng/mL), were obtained.

### Questions/Discussion Points, Part 2

#### How Do the Cancer Biomarkers Help in Narrowing the Differential Diagnosis?

Tumor markers are soluble glycoproteins that are found in the blood, urine, or tissues of patients with certain types of cancer. They are typically produced by tumor cells, but in some cases,

they may be produced by the body in response to malignancy or to certain benign conditions.<sup>5</sup>

As such, serum tumor markers are useful as a preoperative diagnostic tool in certain types of gynecological cancer. In epithelial ovarian cancer, CA-125 has been identified as the most sensitive marker. Serum tumor markers are particularly informative in distinguishing ovarian germ cell tumors (Table 1). Serum LDH is often increased in dysgerminoma and mixed germ cell tumors. In choriocarcinoma, dysgerminoma, and mixed germ cell tumors, β-HCG is significantly increased. AFP is increased in yolk sac tumor and embryonal cell tumors.<sup>6</sup>

The patient is young (<30 years), not in the usual age range for ovarian carcinoma (peri and postmenopausal age), and her presurgical serum AFP was solely and significantly elevated, focusing the differential diagnosis to yolk sac (endodermal sinus) tumor.

### Diagnostic Findings, Part 3

Given her extensive disease, patient underwent a fertility-sparing left salpingo-oophorectomy, cytoreduction, and surgical staging procedure. A mass replacing the left ovary weighed 1112 g and was 15.5 cm in greatest dimension. Sectioning revealed complete effacement by a variegated soft, yellow, gray, and red lesion with numerous areas of geographic hemorrhage and necrosis.

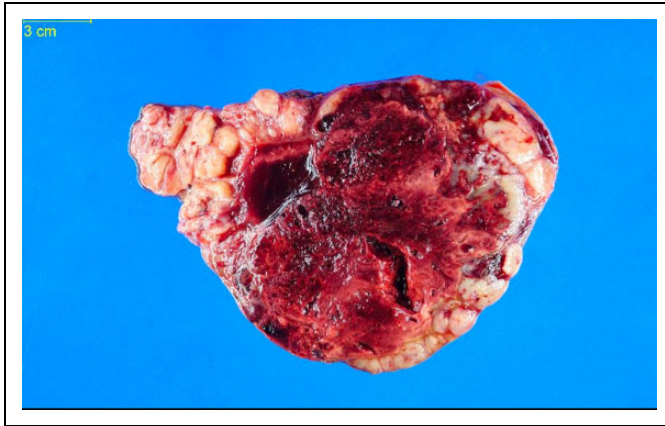
### Questions/Discussion Points, Part 3

#### Describe the Gross Findings Seen in Figure 1

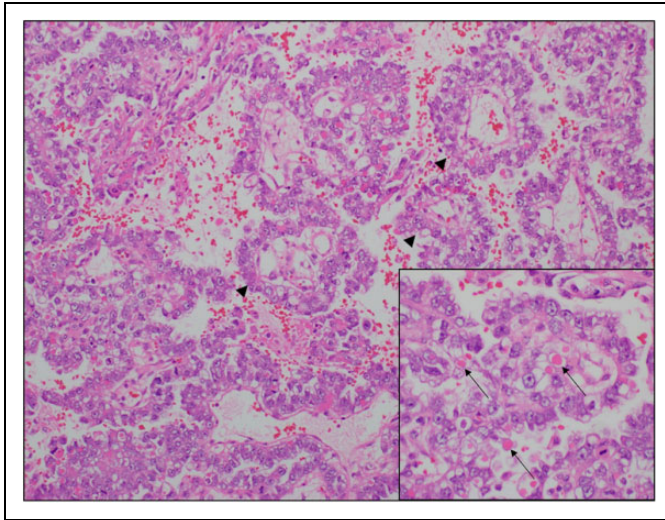
The cut surface reveals a large mass with a tan-white, fleshy, and lobulated surface and extensive areas of necrosis and hemorrhage.

#### Describe the Histologic Features Seen in Figures 2

A medium-power photomicrograph showing the microscopic characteristic feature of yolk sac tumor. Schiller-Duval body,



**Figure 1.** Cross section of the tumor showing bulging lobulated surfaces with centrally prominent hemorrhagic necrosis.

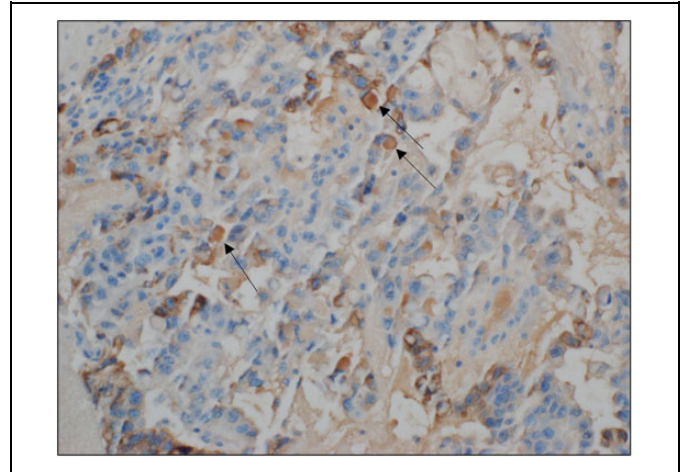


**Figure 2.** A glomeruloid proliferation of tumor cells around a central core of thin-walled vessels, that is, Schiller-Duval bodies (arrow heads), characteristic of yolk sac tumor. Hematoxylin and eosin (H&E)  $\times 100$ . Inset. Variably sized eosinophilic hyaline globules accompany the Schiller-Duval bodies (arrows). H&E  $\times 400$ .

which is composed of a central vessel surrounded by loose connective tissue, which in turn is surrounded by primitive-appearing epithelium free floating in spaces (arrow heads). The inset in Figure 2, is a high-power photomicrograph, exhibiting the variably sized eosinophilic hyaline globules that may be seen in association with the Schiller-Duval bodies (arrows).

### Describe the Histologic Features Seen in Figures 3

Immunohistochemistry (IHC) selectively identifies the cells with antigens (proteins) by employing the principle of antibodies binding specifically to antigens in biological tissues, in this case AFP. Figure 3 demonstrates a high-power photomicrograph, highlighting the positive AFP immunoreactivity of hyaline globules (arrows).



**Figure 3.** Hyaline globules showing positive  $\alpha$ -fetoprotein immunoreactivity (arrows),  $\times 200$ .

### What Are the Distinguishable Morphologic and Laboratory Features of This Tumor?

The World Health Organization (WHO) classifies ovarian neoplasms according to their most probable tissue of origin. Most primary ovarian tumors arise from 1 of the 4 ovarian components: (1) surface epithelium and tubal fimbria, (2) ovarian stroma, (3) sex cord-stroma, and (4) germ cells. In yolk sac tumor, a germ cell neoplasm, the neoplastic elements mimic the cells that migrate from the embryological yolk sac to the ovary.<sup>7</sup>

Although rare, yolk sac tumor (previously denoted as endodermal sinus tumor) is the second most common malignant germ cell tumor of the ovary that affects children and adolescents.<sup>6,8</sup> Consistent with differentiation along the extraembryonic yolk sac lineage, the serum AFP level is elevated, whereas the serum chorionic gonadotropin levels are normal.<sup>7,8</sup> Histological characteristics of yolk sac tumors are variable, for example, reticular or microcystic areas formed by a loose meshwork lined by flat or cuboidal cells; rounded glomeruloid bodies composed of a central blood vessel enveloped by tumor cells within a space that is also lined by tumor cells (Schiller-Duval body).<sup>8</sup>

Intracytoplasmic and extracellular eosinophilic, periodic acid-Schiff-positive hyaline droplets are almost always present and frequently stain for AFP by immunoperoxidase techniques. These droplets may also contain  $\alpha$  1-antitrypsin and basement membrane components. Yolk sac tumor shows positivity for SALL4 and glypican-3 and is negative for OCT 3-4. The tumor cells may react with pan-keratin (but not for keratin 7 or epithelial membrane antigen (EMA)—differentiating them from endometrioid and clear cell ovarian carcinoma) as well as WT1 (similar to serous ovarian carcinoma). DNA studies have revealed that yolk sac tumors are aneuploid.<sup>7-9</sup>

Treatment management in oncology is often guided based on the stage of the cancer. Cancer staging is a rating measure to

reflect the growth and spread of disease. Most cancers are staged based on the TNM staging system, which is maintained by the American Joint Committee on Cancer. In this system, T (tumor size), N (nodes), and M (metastasis) describe a different area of cancer growth. The values from T, N, and M are combined to assign an overall stage. Cancers that can't spread to distant sites are rated as stage 0. Stage I includes small primary tumors that haven't spread to lymph nodes. Stage II and III are larger or more extensive primary tumors with or without cancer in nearby lymph nodes. Stage IV is cancer that has spread to distant sites at diagnosis.<sup>10</sup>

The introduction of multidrug chemotherapy regimen has dramatically improved survival rates. Administration of adjuvant chemotherapy, clinical stage, and younger age are associated with good outcomes. Serial measurements of serum AFP are informative in monitoring the tumor course.<sup>11</sup>

### Patient Follow-Up

Following the surgery, patient was confirmed to have stage IV disease, underwent systemic treatment, and completed 4 cycles of bleomycin, etoposide, and cisplatin chemotherapy regimen. She has resolution of respiratory symptoms and pleural effusion. Her serum AFP levels have normalized with the most recent level at 3.2 (ref range: 0.5-8.0 ng/mL). For surveillance, she will have serum AFP measurement monthly for 2 years.

### Teaching Points

- Yolk sac tumor is a rare, but potentially aggressive germ cell ovarian neoplasm that most often presents in children and young adults.
- Serum cancer biomarker levels may be a useful presurgical tool to focus the differential diagnosis. Yolk sac tumor is characterized by significantly elevated serum AFP level.
- Schiller-Duval body is the defining morphologic feature of yolk sac tumor.
- Yolk sac tumor shows positive immunostaining for AFP, pankeratin, WT1, SALL4, and glypican-3 and demonstrates negative immunoreactivity for OCT 3-4.
- Administration of adjuvant chemotherapy, clinical stage, and younger age (<30 years) are associated with more favorable outcomes.

### Declaration of Conflicting Interests

The author(s) declared no potential conflicts of interest with respect to the research, authorship, and/or publication of this article.

### Funding

The author(s) received no financial support for the research, authorship, and/or publication of this article.

### References

1. Knollmann-Ritschel BEC, Regula DP, Borowitz MJ, Conran R, Prystowsky MB. Pathology Competencies for Medical Education and Educational Cases. *Acad Pathol.* 2017; 4. doi:10.1177/2374289517715040.
2. Kumar V, Abbas A, Aster J, Cotran R, Robbins S. *Robbins and Cotran Pathologic Basis Of Disease* 9th ed. Philadelphia, PA: Elsevier/Saunders; 2015:1031-1032.
3. Biggs WS, Marks ST. Diagnosis and management of adnexal masses. *Am Fam Physician.* 2016;93:676-681.
4. Saha S, Robertson M. Meigs' and pseudo-Meigs' syndrome. *Australas J Ultrasound Med.* 2012;15:29-31.
5. Terry KL, Sluss PM, Skates SJ, et al. Blood and urine markers for ovarian cancer: a comprehensive review. *Dis Markers.* 2004;20:53-70.
6. Euscher ED. Germ cell tumors of the female genital tract. *Surg Pathol Clin.* 2019;12:621-649.
7. Kurman RJ, Carcangiu ML, Herrington CS, Young RH. *WHO Classification of Tumours of Female Reproductive Organs. Vol 6. WHO Series on Histological and Genetic Typing of Human Tumours.* 4th, ed. Geneva, Switzerland: International Agency for Research on Cancer/World Health Organization; 2014.
8. Tewari K, Cappuccini F, Disaia PJ, Berman ML, Manetta A, Kohler MF. Malignant germ cell tumors of the ovary. *Obstet Gynecol.* 2000;95:128-133.
9. Kommos F, Bibbo M, Talerma A. Nuclear deoxyribonucleic acid content (ploidy) of endodermal sinus (yolk sac) tumor. *Lab Invest.* 1990;62:223-231.
10. Amin MB, Edge S, Greene F, eds. *AJCC Cancer Staging Manual* 8th ed. Chicago, IL: Springer International Publishing American Joint Commission on Cancer; 2017.
11. Nasioudis D, Chapman-Davis E, Frey MK, Caputo TA, Holcomb K. Management and prognosis of ovarian yolk sac tumors; an analysis of the national cancer data base. *Gynecol Oncol.* 2017; 147:296-301.