

Right-sided hemiagenesis of the thyroid lobe and isthmus: A case report

Prabhat Kumar Tiwari, M Baxi¹, J Baxi¹, D Koirala

Departments of Radiology and ¹Surgery, Manipal Teaching Hospital, PO Box: 341, Phulbari, Pokhara, Nepal

Correspondence: Dr Mukta Baxi, Department of Surgery, Manipal Teaching Hospital, PO Box: 341, Phulbari, Pokhara, Nepal.

E-mail: muktabaxi@yahoo.com

Abstract

Unilateral or bilateral hypoplasia or agenesis of one or both thyroid lobes, with or without isthmic agenesis, is a rare developmental anomaly. Hemiagenesis of the left lobe is far commoner than of the right. Clinically, these patients may be euthyroid, hyperthyroid, or hypothyroid. Ultrasonography is usually able to diagnose this condition easily, as we demonstrate in this case report of a 37-year-old lady with an incidentally detected thyroid nodule who was found to have hemiagenesis of the right lobe and isthmus.

Key words: Congenital anomalies; hemiagenesis; thyroid

Developmental anomalies of the thyroid are rare. They are usually a result of abnormal descent rather than of abnormal development. Hemiagenesis of either lobe, with or without agenesis of the isthmus, is very rare, with a prevalence rate of around 0.2%^[1,2] in asymptomatic children. The left side is the most commonly involved in hemiagenesis (80%). The isthmus may be absent in 40–50% of cases.^[2,3] Rarely, right-sided hemiagenesis may be encountered. The disorder is more common in females, the male : female ratio being 3:1. Thyroid function may be altered in 38–47% of patients.^[3] USG plays an important role in diagnosis.

We present a rare case of hemiagenesis of the right lobe and isthmus of the thyroid.

Case Report

A 37-year-old lady presented with bilateral cyclical mastalgia and benign breast disease, which was confirmed by USG and fine needle aspiration cytology. On clinical examination, there was an enlarged left lobe; a solitary thyroid nodule, measuring 1.5 × 1.0 cm in size was also found. The right lobe could not be felt. There was no past history of surgery in the region of the neck.

Free T₃, free T₄, and TSH on two occasions suggested a biochemically euthyroid state. USG showed multiple hypoechoic to isoechoic heterogeneous nodules [Figure 1] in the enlarged left lobe, the largest being 6.6 mm in diameter. Doppler showed increased vascularity in the left lobe. The isthmus and right lobe were not visualized [Figure 2]. CT scan of the neck and thyroid confirmed the agenetic

right lobe and isthmus [Figure 3]. Fine needle cytology of the thyroid nodule showed a colloid nodule with cystic degeneration and hemorrhage.

The patient was reassured and was prescribed vitamin E supplementation for her mastalgia. Due to the mild symptoms and the increased vascularity of the left lobe, and in view of the possibility of developing hypothyroidism or hyperthyroidism in the future, 3-monthly follow-up with thyroid function tests and USG was advised.

Discussion

Congenital thyroid anomalies are rare. They may be related to abnormal descent of the thyroid gland or to structural abnormalities in thyroid development, such as hypoplasia or hemiagenesis with or without isthmic agenesis.

A literature review in the year 2000 documented 256 cases of hemiagenesis.^[4] We could find 51 new cases published between 2000 and 2007 in the English literature. Left-sided hemiagenesis is far commoner than right-sided hemiagenesis,^[1,2,5–10] with a left : right ratio of 4:1. The prevalence of this disorder, as documented in 2845 Belgian school children who were screened by USG for congenital thyroid anomalies, was found to be 0.2%.^[11]

Though the etiology of hemiagenesis is not clearly known and most of the cases are sporadic, a few may be familial and there may be a genetic predisposition.^[12–16] Although patients may have a normal thyroid lobe with euthyroidism,^[1,3] both hypothyroidism^[13,14] and

hyperthyroidism,^[4,16-18] are known to occur. Other anomalies such as benign euthyroid adenoma,^[19] thyroiditis,^[20]

multinodular goiter,^[1,2,8,21] papillary carcinoma,^[7,9,22] and primary hyperparathyroidism^[5] have also been reported.

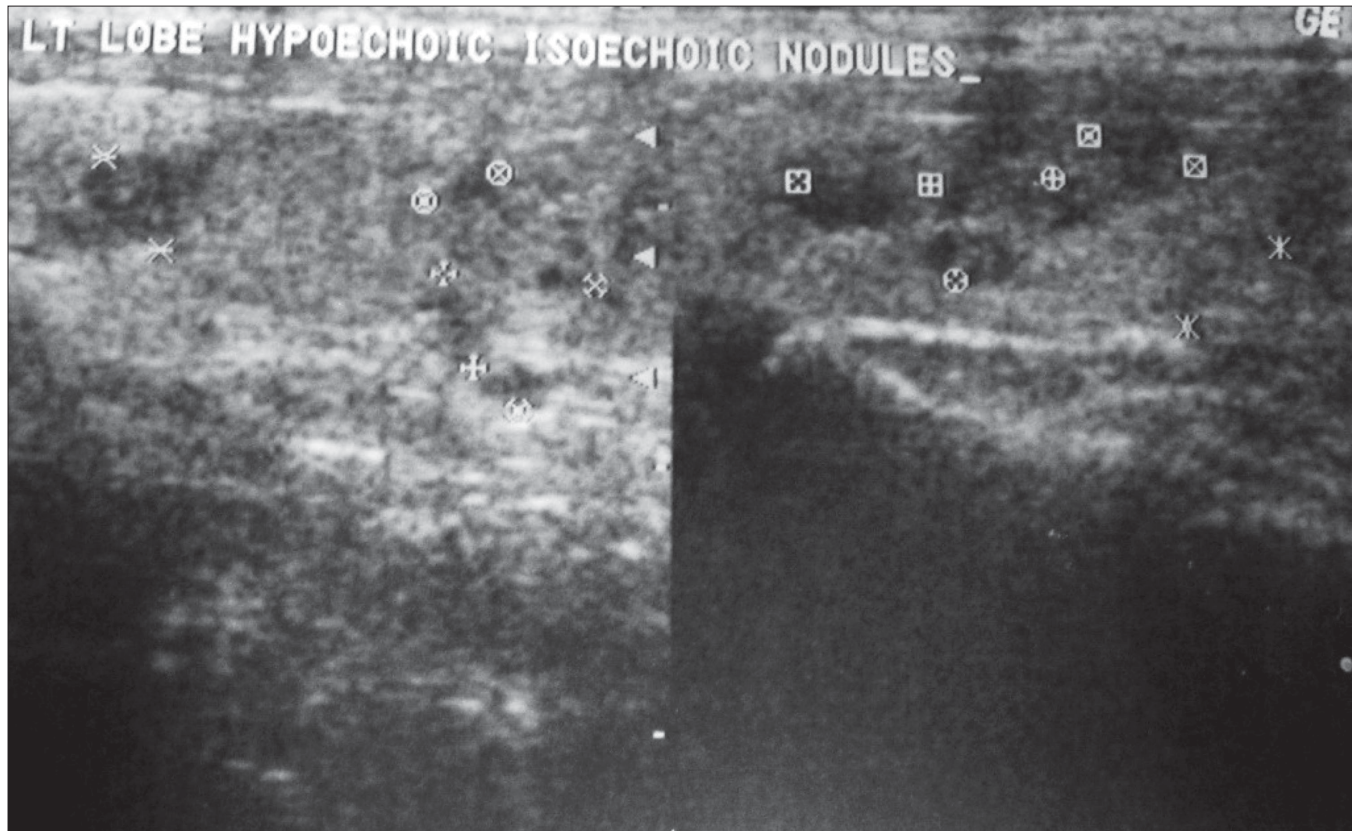


Figure 1: Transverse USG image shows multiple nodules in the left thyroid gland

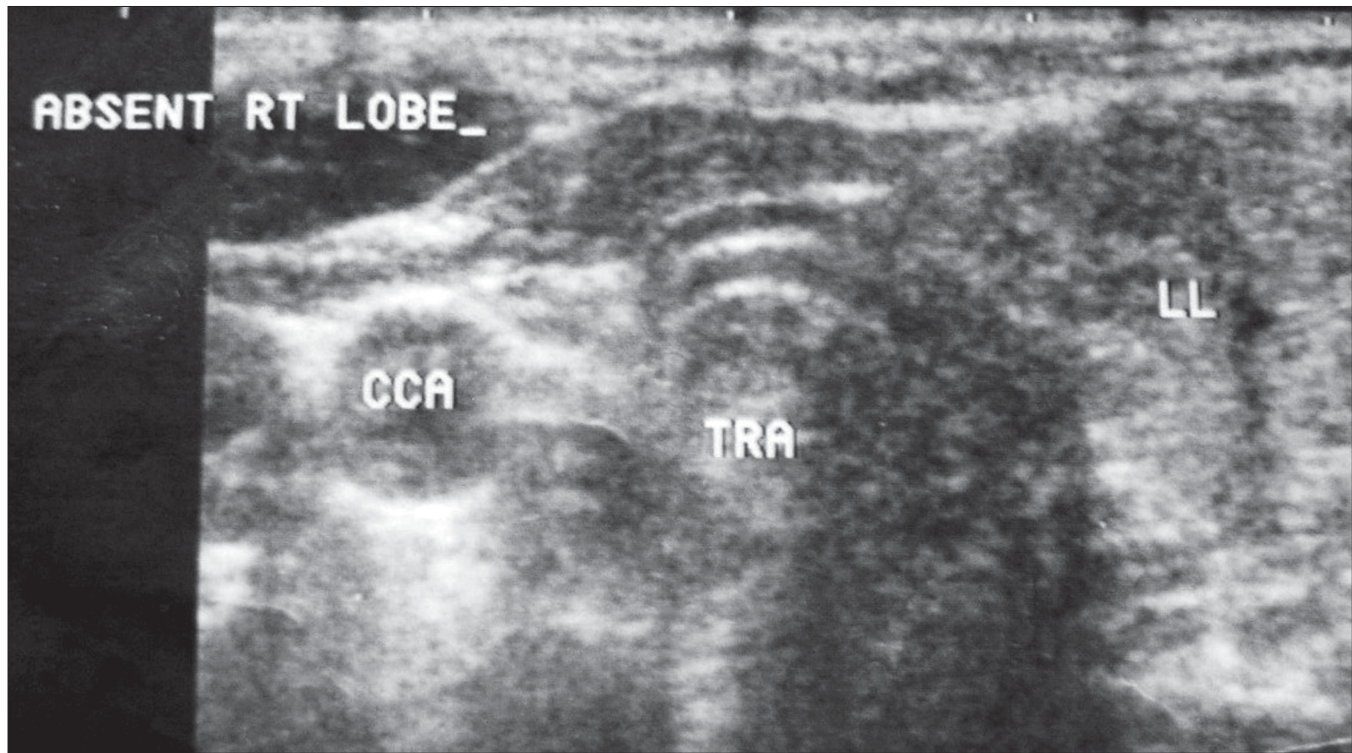


Figure 2: Transverse USG image shows agenesis of the right lobe

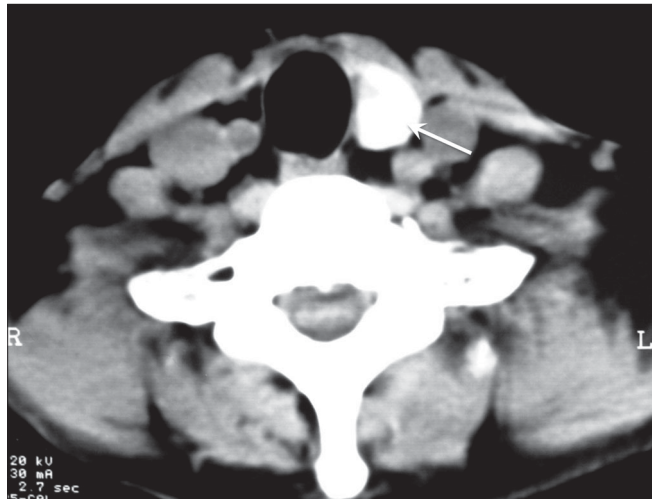


Figure 3: CT scan of the neck shows absence of the right lobe of the thyroid. The left lobe is well seen (arrow)

Our patient had a euthyroid colloid nodule. The associated cyclical mastalgia and bilateral fibroadenosis were most likely coincidental findings.

As in our case, most patients with hemiogenesis are diagnosed incidentally.^[1,2,8,11] USG is a useful modality to detect this anomaly. In endemic zones, there may be a high incidence of adenomatous nodules and colloid cysts in the single lobe. Malignancy always remains a cause for concern. Though a CT scan was performed in our patient, other modalities may not always be required to confirm the diagnosis of hemiogenesis, USG usually being diagnostic.^[8,11,23-26]

References

- Aslaner A, Aydin M, Ozdere A. Multinodular goiter with thyroid hemiogenesis: A case report and review of the literature. *Acta Chir Belg* 2005;105:528-30.
- Karabay N, Comlekci A, Canda MS, Bayraktar F, Degirmenci B. Thyroid hemiogenesis with multinodular goiter: A case report and review of the literature. *Endocr J* 2003;50:409-13.
- Vázquez-Chávez C, Acevedo-Rivera K, Sartorius C, Espinosa-Said L. Thyroid hemiogenesis: Report of 3 cases and review of the literature. *Gac Med Mex* 1989;125:395-9.
- Veliz J, Pineda G. Thyroid hemiogenesis associated with Basedow-Graves disease: Report of a case. *Rev Med Chil* 2000;128:896-8.
- Sakurai K, Amano S, Enomoto K, Matsuo S, Kitajima A. Primary hyperparathyroidism with thyroid hemiogenesis. *Asian J Surg* 2007;30:151-3.
- Büyükdereci G, Guney IB, Kibar M, Kinaci C. Thyroid hemiogenesis: A report of three cases and review of the literature. *Ann Nucl Med* 2005;19:147-50.
- Huang SM, Chen HD, Wen TY, Kun MS. Right thyroid hemiogenesis associated with papillary thyroid cancer and an ectopic prelaryngeal thyroid: A case report. *J Formos Med Assoc* 2002;101:368-71.
- Mikosch P, Gallowitzsch HJ, Kresnik E, Molnar M, Gomez I, Lind P. Thyroid hemiogenesis in an endemic goiter area diagnosed by ultrasonography: Report of sixteen patients. *Thyroid* 1999;9:1075-84.
- Khatri VP, Espinosa MH, Harada WA. Papillary adenocarcinoma in thyroid hemiogenesis. *Head Neck* 1992;14:312-5.
- Letonturier P, Hazard J, Tourneur R, Perlemuter L, Angel R. Thyroid hemiogenesis (single thyroid lobe): 8 cases. *Nouv Presse Med* 1979;8:1227-9.
- Shabana W, Delange F, Freson M, Osteaux M, De Schepper J. Prevalence of thyroid hemiogenesis: Ultrasound screening in normal children. *Eur J Pediatr* 2000;159:456-8.
- Castanet M, Leenhardt L, Léger J, Simon-Carré A, Lyonnet S, Pelet A, *et al.* Thyroid hemiogenesis is a rare variant of thyroid dysgenesis with a familial component but without Pax8 mutations in a cohort of 22 cases. *Pediatr Res* 2005;7:908-13.
- Gaudino R, Garel C, Czernichow P, Léger J. Proportion of various types of thyroid disorders among newborns with congenital hypothyroidism and normally located gland: A regional cohort study. *Clin Endocrinol (Oxf)* 2005;62:444-8.
- Tonacchera M, Banco ME, Montanelli L, Di Cosmo C, Agretti P, De Marco G, *et al.* Genetic analysis of the PAX8 gene in children with congenital hypothyroidism and dysgenetic or eutopic thyroid glands: Identification of a novel sequence variant. *Clin Endocrinol (Oxf)* 2007;67:34-40.
- Rajmil HO, Rodriguez-Espinosa J, Soldevila J, Ordonez-Llanos J. Thyroid hemiogenesis in two sisters. *J Endocrinol Invest* 1984;7:393-4.
- Lee IT, Sheu WH, Lin SY. Familial form of thyroid dysgenesis: Report of thyroid hemiogenesis with accompanying Graves' disease in a woman whose daughter has thyroid agenesis. *Horm Res* 2003;59:47-9.
- Baldini M, Orsatti A, Cantalamessa L. A singular case of Graves' disease in congenital thyroid hemiogenesis. *Horm Res* 2005;63:107-10.
- Sasaki H, Futata T, Ninomiya H, Higashi Y, Okumura M. CT and MR imagings of single thyroid lobe (thyroid hemiogenesis) with Graves' disease. *Postgrad Med J* 1991;67:701.
- Vaswani K, Vitellas KM, Bennett WF. Thyroid hemiogenesis with adenoma. *AJR Am J Roentgenol* 2000;175:895-8.
- Sharma R, Mondal A, Popli M, Sahoo M, Malhotra N, Soni S. Hemiogenesis of the thyroid associated with chronic lymphocytic thyroiditis. *Clin Nucl Med* 2001;26:506-8.
- Graber AL. Multinodular goiter in thyroid hemiogenesis. *J Tenn Med Assoc* 1983;76:174.
- Pizzini AM, Papi G, Corrado S, Carani C, Roti E. Thyroid hemiogenesis and incidentally discovered papillary thyroid cancer: Case report and review of the literature. *J Endocrinol Invest* 2005;28:66-71.
- Hydovitz JD, Winzelberg GA. Use of ultrasonography to eliminate hemiogenesis of a thyroid lobe in the differential diagnosis of a toxic adenoma (Plummer's disease) *Clin Nucl Med* 1988;3:144-5.
- Leckie RG, Delaplain CB, Watabe JT, Darrow M. Thyroid hemiogenesis by I-123 thyroid scan with high-resolution real-time ultrasound confirmation *Clin Nucl Med* 1993;18:161-3.
- De Remigis P, D'Angelo M, Bonaduce S, Di Giandomenico V, Sensi S. Comparison of ultrasonic scanning and scintiscanning in the evaluation of thyroid hemiogenesis. *J Clin Ultrasound* 1985;13:561-3.
- Kreisner E, Camargo-Neto E, Maia CR, Gross JL. Accuracy of ultrasonography to establish the diagnosis and etiology of permanent primary congenital hypothyroidism. *Clin Endocrinol (Oxf)* 2003;59:361-5.

Source of Support: Nil, Conflict of Interest: None declared.