

# Rapid economical acetic acid Papanicolaou staining procedure versus conventional staining procedure in normal oral mucosa

Karthika Panneerselvam<sup>1</sup>, Raghavendhar Karthik. K<sup>2</sup>, Ramya Ramadoss<sup>2</sup>, A. Ramesh Kumar<sup>2</sup>, K. Rajkumar<sup>2</sup>

<sup>1</sup>Oral Pathology and Microbiology, Karpaga Vinayaga Institute of Dental Sciences, Kanchipuram, <sup>2</sup>Oral Pathology and Microbiology, SRM Dental College and Hospital, Chennai, Tamil Nadu, India

## Abstract

**Background:** Papanicolaou (Pap) staining technique is a conventional technique used in cytology but it is time consuming.

**Aim:** The aim of the study was to determine the efficacy of Rapid Economical Acetic acid Papanicolaou stain (REAP) over conventional staining technique in studying normal oral mucosa.

**Materials and Methods:** Eighty patients were selected and were grouped based on their habits. Two smears were obtained from each patient and were subjected to both the staining techniques. A total of 160 slides were studied for features such as cellular outline, nuclear outline, nuclear details, cellular differentiation, micronuclei and cellular transparency.

**Results:** The conventional staining procedure showed 79 cases of optimal cellular staining, 78 cases of optimal nuclear staining, 35 cases of optimal nuclear details, 57 cases of optimal differentiation and 27 cases of optimal transparency and 33 cases of optimal micronuclei. REAP staining showed 75 cases of optimal cellular staining, 64 cases of optimal nuclear staining, 20 cases of optimal nuclear details, 36 cases of optimal differentiation and 28 cases of optimal transparency and 25 cases of optimal micronuclei.

**Conclusion:** REAP staining effectively reduces the time and the cost factor, but the cytological details are well observed under conventional staining technique in normal patients.

**Keywords:** Conventional staining, modification, REAP staining

**Address for correspondence:** Dr. Karthika Panneerselvam, Plot No: 87 and 88, Phase 2 Porur Gardens, Vanagaram, Madhuravoyal Post, Chennai - 600 095, Tamil Nadu, India.

E-mail: karthikaomfp@gmail.com

**Submitted:** 07-Apr-2020, **Revised:** 18-May-2021, **Accepted:** 19-Oct-2021, **Published:** 28-Jun-2022

## INTRODUCTION

Papanicolaou (Pap) staining technique was first developed by George N. Pap in the year 1943. Pap staining is a commonly used cytological staining technique in screening tests of inflammatory and cancerous lesions of cervix.<sup>[1]</sup> In the year 1954 and 1960, Pap subsequently introduced

modification in the techniques. Various other modifications were introduced aiming to reduce the cost and time involving the procedure.<sup>[2]</sup> Rapid economical acetic acid Pap (REAP) stain is one such modified staining procedure introduced by Shabnam Izhar *et al.*<sup>[1]</sup> The aim of this

This is an open access journal, and articles are distributed under the terms of the Creative Commons Attribution-NonCommercial-ShareAlike 4.0 License, which allows others to remix, tweak, and build upon the work non-commercially, as long as appropriate credit is given and the new creations are licensed under the identical terms.

**For reprints contact:** WKHLRPMedknow\_reprints@wolterskluwer.com

**How to cite this article:** Panneerselvam K, Karthik R, Ramadoss R, Kumar AR, Rajkumar K. Rapid economical acetic acid Papanicolaou staining procedure versus conventional staining procedure in normal oral mucosa. *J Oral Maxillofac Pathol* 2022;26:285.

### Access this article online

#### Quick Response Code:



#### Website:

www.jomfp.in

#### DOI:

10.4103/jomfp.JOMFP\_135\_20

study is to compare REAP technique over conventional staining technique to interpret their efficacy and determine cytological differences in patients with different habits.

## MATERIALS AND METHODS

The study was conducted in the Department of Oral Pathology and Microbiology, S. R. M Dental College, Chennai. Eighty patients without any oral lesion and inflammation were selected and were divided into four groups. Group 1 (N): patients without habits, Group 2 (S): patients with smoking habit, Group 3 (S + A): patients with smoking and alcohol habit and Group 4 (S + A + P): patients with smoking, alcohol and paan chewing habit. Informed consent was obtained from all the patients before the start of the procedure. Patients were asked to rinse mouth, and the cytological smears were obtained from the buccal mucosa using a wooden spatula with a single stroke. Slides were prepared and wet fixed immediately. The procedure was done twice for each patient to prepare two slides for two different staining techniques such as conventional staining and REAP staining technique.

The staining technique for REAP is:

1% acetic acid	10 dips
Preheated (60°C) Harris Hematoxylin	10 dips
Tap water	10 dips
1% acetic acid	10 dips
OG-6	10 dips
1% acetic acid	10 dips
EA-50	10 dips
1% acetic acid	10 dips
Methanol	10 dips
Xylene	10 dips.

Cellular outline, nuclear outline, nuclear detail, cellular differentiation, transparency and micronuclei were studied by two independent observers. Based on the visibility of the cellular detail, scores of 0 (suboptimal) and 1 (optimal) were assigned for each feature. The criteria for the scores were:

- Cell outline – Identification of clear, sharp cell outline and absence of fuzziness
- Nuclear outline – Identification of clear, sharp nuclear outline and color intensity
- Nuclear details – Identification of the presence of fragmentation, chromatin network and inclusions in the nuclei
- Differentiation – Identification of cellular color differentiation
- Transparency-Identification of cellular cytoplasm

without any particulate

- Micronuclei – Identification of well-defined micronuclei.

## RESULTS

A total of 160 slides were studied. The cellular and nuclear details of each patient were studied under conventional and REAP technique. Tables 1-6 represent cellular outline, nuclear staining, nuclear details, cellular differentiation, cellular transparency and micronuclei scores of both techniques.

Under conventional staining technique [Figure 1], the total scores were 79 for optimal cellular outline, 78 for optimal nuclear staining, 35 for optimal nuclear, 57 for optimal differentiation, 27 for optimal transparency and 33 for optimal micronuclei. Scores for REAP staining [Figure 2] were 75 for optimal cellular staining, 64 for optimal nuclear staining, 20 for optimal nuclear details, 36 for optimal differentiation, 28 for optimal transparency and 25 for optimal micronuclei. Significant results were obtained on comparing the two staining techniques without group differentiation in relation to nuclear outline ( $P < 0.001$ ), nuclear detail ( $P < 0.013$ ) and cellular differentiation ( $P$  value 0.001). When the groups were divided and studied, in normal patients without habits, conventional staining was better than REAP staining technique in relation to nuclear detail ( $P < 0.004$ ), nuclear differentiation ( $P < 0.006$ ) and cellular transparency ( $P < 0.003$ ). In patients with smoking habits, conventional staining was better than REAP staining technique in relation to cellular transparency ( $P < 0.002$ ). In patients with smoking, alcohol and paan chewing habit, REAP staining was better than conventional staining in relation to cellular differentiation ( $P < 0.003$ ). Apart from the six features that were studied, the study also noticed that the slides stained by either technique showed the presence of inflammatory cells and in few cases presence of bacteria too.

## DISCUSSION

Pap staining is by far the most preferred staining method for cytological studies due to its better enhancement of nuclear details and increased cellular transparency. However, it has the limitations of prolonged procedural time and increased costing.

Numerous modifications have been introduced over the years, with the aim of reducing procedural time and cost. Kline, Tao and Sato introduced modification in staining techniques which reduced staining time to 4 min, 5 min and 90 s, respectively.

However, this compromised cytological features.<sup>[3]</sup>

The ultrafast Papanicolaou stain (UFP) was introduced

**Table 1: Chi square test to compare proportions between staining techniques (cell outline)**

Habit	Cell outline	Staining			$\chi^2$	P
		Conventional, n (%)	REAP, n (%)	Total, n (%)		
N	Sub-optimal	0	0	0	-	-
	Optimal	20 (100.0)	20 (100.0)	40 (100.0)		
	Total	20 (100.0)	20 (100.0)	40 (100.0)		
S	Sub-optimal	0	0	0	-	-
	Optimal	20 (100.0)	20 (100.0)	40 (100.0)		
	Total	20 (100.0)	20 (100.0)	40 (100.0)		
S+A	Sub-optimal	1 (5.0)	3 (15.0)	4 (10.0)	* 0.605	
	Optimal	19 (95.0)	17 (85.0)	36 (90.0)		
	Total	20 (100.0)	20 (100.0)	40 (100.0)		
S+A+P	Sub-optimal	0	2 (5.0)	2 (5.0)	* 0.487	
	Optimal	20 (100.0)	18 (90.0)	38 (95.0)		
	Total	20 (100.0)	20 (100.0)	40 (100.0)		
Total	Sub-optimal	1 (1.3)	5 (6.3)	6 (3.8)	* 0.210	
	Optimal	79 (98.8)	75 (93.8)	154 (96.3)		
	Total	80 (100.0)	80 (100.0)	160 (100.0)		

\*Fischer's exact Chi-square. REAP: Rapid economical acetic acid Papanicolaou

in the year 1995 by Young and Alvarez. This was a quick method taking 90 s while being an amalgamation of the Romanowsky and conventional Pap staining methods using chemicals such as Richard–Allan hematoxylin, Richard Allan Cyto-stain and ethyl alcohol.<sup>[4]</sup> Sinkar *et al* and Biswas *et al.* further modified the technique to modified UFP due to the paucity in the availability of Richard Allan hematoxylin and Richard Allan Cyto-stain stains. Substitution with the Gills or Harris hematoxylin and modified eosin azure instead made the staining time 130 s.<sup>[4,5]</sup>

The Reap technique incorporated acetic acid as an alternative to alcohol. This reduced both the cost and the procedural time. Moreover, the study revealed optimal staining of the cytoplasm (differentiation and transparency) in 90.5% of the cases and optimal staining of nucleus (nuclear detail and chromatin pattern) in 96% of the cases.<sup>[1]</sup> In a study by Biswas *et al.* with 220 (gynecological) smears obtained from 110 patients, cellular and nuclear staining quality of REAP staining technique was observed to be better than conventional PAP. The study reported considerable

**Table 2: Chi-square test to compare proportions between staining techniques (nuclear outline)**

Habit	Nuclear outline	Staining			$\chi^2$	P
		Conventional, n (%)	REAP, n (%)	Total, n (%)		
N	Sub-optimal	1 (5.0)	3 (15.0)	4 (10.0)	*	0.605
	Optimal	19 (95.0)	17 (85.0)	36 (90.0)		
	Total	20 (100.0)	20 (100.0)	40 (100.0)		
S	Sub-optimal	0	4 (20.0)	4 (10.0)	*	0.106
	Optimal	20 (100.0)	16 (80.0)	36 (90.0)		
	Total	20 (100.0)	20 (100.0)	40 (100.0)		
S+A	Sub-optimal	1 (5.0)	5 (25.0)	6 (15.0)	*	0.182
	Optimal	19 (95.0)	15 (75.0)	34 (85.0)		
	Total	20 (100.0)	20 (100.0)	40 (100.0)		
S+A+P	Sub-optimal	0	4 (20.0)	4 (10.0)	*	0.106
	Optimal	20 (100.0)	16 (80.0)	36 (90.0)		
	Total	20 (100.0)	20 (100.0)	40 (100.0)		
Total	Sub-optimal	2 (2.5)	16 (20.0)	18 (11.3)	12.269	<0.001

\*Fischer's exact Chi square. REAP: Rapid economical acetic acid Papanicolaou

**Table 3: Chi square test to compare proportions between staining techniques (nuclear detail)**

Habit	Nuclear detail	Staining			$\chi^2$	P
		Conventional, n (%)	REAP, n (%)	Total, n (%)		
N	Sub-optimal	4 (20.0)	13 (65.0)	17 (42.5)	8.286	0.004
	Optimal	16 (80.0)	7 (35.0)	23 (57.5)		
	Total	20 (100.0)	20 (100.0)	40 (100.0)		
S	Sub-optimal	13 (65.0)	17 (85.0)	30 (75.0)	2.133	0.144
	Optimal	7 (35.0)	3 (15.0)	10 (25.0)		
	Total	20 (100.0)	20 (100.0)	40 (100.0)		
S+A	Sub-optimal	17 (85.0)	17 (85.0)	34 (85.0)	*	1.000
	Optimal	3 (15.0)	3 (15.0)	6 (15.0)		
	Total	20 (100.0)	20 (100.0)	40 (100.0)		
S+A+P	Sub-optimal	11 (55.0)	13 (65.0)	24 (60.0)	0.417	0.519
	Optimal	9 (45.0)	7 (35.0)	16 (40.0)		
	Total	20 (100.0)	20 (100.0)	40 (100.0)		
Total	Sub-optimal	45 (56.3)	60 (75.0)	105 (65.6)	6.234	0.013
	Optimal	35 (43.8)	20 (25.0)	55 (34.4)		
	Total	80 (100.0)	80 (100.0)	160 (100.0)		

\*Fischer's exact Chi-square. REAP: Rapid economical acetic acid Papanicolaou

**Table 4: Chi-square test to compare proportions between staining techniques (differentiation)**

Habit	Differentiation	Staining			$\chi^2$	P
		Conventional, n (%)	REAP, n (%)	Total, n (%)		
N	Sub-optimal	2 (10.0)	4 (50.0)	12 (30.0)	7.619	0.006
	Optimal	18 (90.0)	10 (50.0)	28 (70.0)		
	Total	20 (100.0)	20 (100.0)	40 (100.0)		
S	Sub-optimal	11 (55.0)	13 (65.0)	24 (60.0)	0.417	0.519
	Optimal	9 (45.0)	7 (35.0)	16 (40.0)		
	Total	20 (100.0)	20 (100.0)	40 (100.0)		
S+A	Sub-optimal	9 (45.0)	12 (60.0)	21 (52.5)	0.902	0.342
	Optimal	11 (55.0)	8 (40.0)	19 (47.5)		
	Total	20 (100.0)	20 (100.0)	40 (100.0)		
S+A+P	Sub-optimal	1 (5.0)	9 (45.0)	10 (25.0)	8.533	0.003
	Optimal	19 (95.0)	11 (55.0)	30 (75.0)		
	Total	20 (100.0)	20 (100.0)	40 (100.0)		
Total	Sub-optimal	23 (28.7)	44 (55.0)	67 (41.9)	11.324	0.001
	Optimal	57 (71.3)	36 (45.0)	93 (58.1)		
	Total	80 (100.0)	80 (100.0)	160 (100.0)		

REAP: Rapid economical acetic acid Papanicolaou

**Table 5: Chi square test to compare proportions between staining techniques (transparency)**

Habit	Transparency	Staining			$\chi^2$	P
		Conventional, n (%)	REAP, n (%)	Total, n (%)		
N	Sub-optimal	1 (5.0)	9 (45.0)	10 (25.0)	8.533	0.003
	Optimal	19 (95.0)	11 (55.0)	30 (75.0)		
	Total	20 (100.0)	20 (100.0)	40 (100.0)		
S	Sub-optimal	19 (95.0)	12 (60.0)	31 (77.5)	-	0.020
	Optimal	1 (5.0)	8 (40.0)	9 (22.5)		
	Total	20 (100.0)	20 (100.0)	40 (100.0)		
S+A	Sub-optimal	15 (75.0)	18 (90.0)	33 (82.5)	-	0.407
	Optimal	5 (25.0)	2 (10.0)	7 (17.5)		
	Total	20 (100.0)	20 (100.0)	40 (100.0)		
S+A+P	Sub-optimal	18 (90.0)	13 (65.0)	31 (77.5)	-	0.127
	Optimal	2 (10.0)	7 (35.0)	9 (22.5)		
	Total	20 (100.0)	20 (100.0)	40 (100.0)		
Total	Sub-optimal	53 (66.3)	52 (65.0)	105 (65.6)	0.028	0.868
	Optimal	27 (33.8)	28 (35.0)	55 (34.4)		
	Total	80 (100.0)	80 (100.0)	160 (100.0)		

\*Fischer's exact Chi-square. REAP: Rapid economical acetic acid Papanicolaou

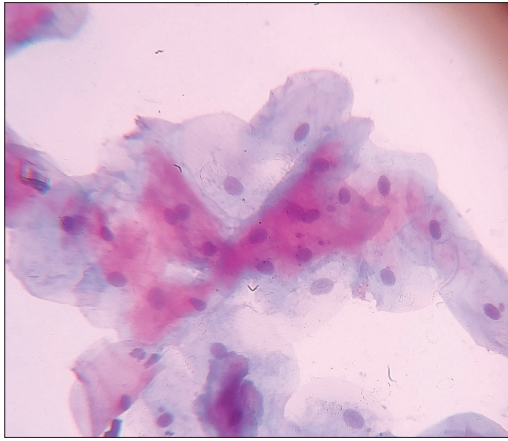
**Table 6: Chi square test to compare proportions between staining techniques (micronuclei)**

Habit	Micronuclei	Staining			$\chi^2$	P
		Conventional, n (%)	REAP, n (%)	Total, n (%)		
N	Sub-optimal	14 (70.0)	18 (90.0)	32 (80.0)	-	0.235
	Optimal	6 (30.0)	2 (10.0)	8 (20.0)		
	Total	20 (100.0)	20 (100.0)	40 (100.0)		
S	Sub-optimal	11 (55.0)	12 (60.0)	23 (57.5)	0.102	0.749
	Optimal	9 (45.0)	8 (40.0)	17 (42.5)		
	Total	20 (100.0)	20 (100.0)	40 (100.0)		
S+A	Sub-optimal	10 (50.0)	9 (45.0)	19 (47.5)	0.100	0.752
	Optimal	10 (50.0)	11 (55.0)	21 (52.5)		
	Total	20 (100.0)	20 (100.0)	40 (100.0)		
S+A+P	Sub-optimal	12 (60.0)	16 (80.0)	28 (70.0)	1.905	0.168
	Optimal	8 (40.0)	4 (20.0)	12 (30.0)		
	Total	20 (100.0)	20 (100.0)	40 (100.0)		
Total	Sub-optimal	47 (58.8)	55 (68.8)	102 (63.7)	1.731	0.188
	Optimal	33 (41.3)	25 (31.3)	58 (36.3)		
	Total	80 (100.0)	80 (100.0)	160 (100.0)		

\*Fischer's exact Chi-square. REAP: Rapid economical acetic acid Papanicolaou

reduction of time to 3 min and cost reduction to 25%.<sup>[6]</sup>  
 Bhagat *et al.* in their study of 102 liquid-based cytology samples that were subjected to Rapid PAP staining technique

and the conventional PAP technique reported that the nuclear staining with modified staining was found to be equivalent to conventional Pap technique in 99.9% of cases and the cytoplasmic staining was as good as conventional



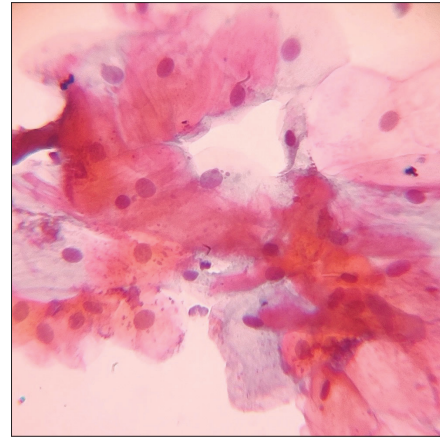
**Figure 1:** Conventional Papanicolaou staining with cellular differentiation

technique in 69.6% of cases. The study supported the use of REAP technique as a cost-effective alternative.<sup>[7]</sup>

Similar conclusions were drawn by Deshpande and Shabnam Izhar in their studies on the use of REAP technique. Deshpande *et al.* reported REAP could be used as an alternative to conventional technique in screening programs. The study observed similar quality of nuclear border staining with both conventional and REAP staining technique, but the cell border, cytoplasmic and chromatin staining quality of REAP was slightly inferior to PAP. Excellent slide preservation for 2 years with considerable reduction in time and cost associated with the REAP staining method was also documented by Deshpande *et al.*<sup>[2]</sup> Similarly study by Shabnam Izhar reported that the REAP technique is a simple, rapid and economical technique that could be used in places with restricted resources but not for research purpose.<sup>[1]</sup> In their study of 737 cervical smears, excellent cytomorphological details were observed in 91.6% cases with the use of conventional staining and only in 33.6% cases with REAP staining.

Our study compared the conventional staining and REAP staining technique in normal oral mucosal samples with and without habits. Analysis of total sample data of 80 slides revealed that, except for cellular transparency, greater percentage of optimal reading was observed with conventional staining technique. Statistically significant results were observed with conventional staining techniques in relation to nuclear outline, nuclear detail and cellular differentiation. The procedural time for staining in our series was 3 min due to the use of as acetic acid instead of ethanol.

According to the literature, procedures involving acetic acid require less time as it not only helps in nuclear fixation but it also intensifies staining capacity. Acetic acid forms



**Figure 2:** Cellular differentiation with REAP staining

ethyl acetate in combination with ethanol derived from EA-36 and OG-6. This forms complexes with cytoplasm and settle in the cell aiding in preserving the intensity of cytoplasmic staining. This is unlike in the regular conventional procedure where alcohol is used as dehydrant and OG-6 and EA-36 stains (alcohol-based stain) diffuse into alcohol during the procedure reducing the cytoplasmic staining intensity.<sup>[7]</sup>

In our study, although 1% acetic acid was used in the REAP procedure, nuclear outline and details were better observed with conventional PAP staining. Although cellular transparency was higher with the REAP technique, it was not statistically significant.

Asthana and Singh, in their study, compared two stains (conventional Pap and REAP) in 100 smears obtained from 50 normal healthy oral mucosal samples without any habits. The study reported higher optimal cytoplasmic (84%) and nuclear staining (92%) with REAP technique when compared with PAP staining.<sup>[8]</sup> This was contradictory to our findings where conventional PAP staining was superior or exhibited greater percentage of optimal reading with significant differences in nuclear details (conventional 80%, REAP 35%,  $P = 0.004$ ), differentiation (conventional 90%, REAP 50%,  $P = 0.006$ ) and transparency (conventional 95%, REAP 55%,  $P = 0.003$ ). Although this could be attributed due to the incorporation of samples from participants with habits such as smoking and alcohol which may interfere with the staining reaction, even the normal samples without habits in our study when subjected to both the techniques demonstrated similar outcomes.

When compared to the conventional staining technique, REAP technique was cost effective too as acetic acid was used in the place of ethanol.

## CONCLUSION

In this study, cytological features were well observed with conventional staining technique in patients with and without habits. We conclude that though staining time and cost were lower with REAP staining technique were very favorable, conventional staining method was found to be superior to REAP technique.

## Financial support and sponsorship

Nil.

## Conflicts of interest

There are no conflicts of interest.

## REFERENCES

1. Izhar S, Kaur R, Masih K. Efficacy of rapid, economical, acetic acid, Papanicolaou stain in cervical smears as an alternative to conventional Papanicolaou stain. *J Cytol* 2014;31:154-7.
2. Deshpande AK, Bayya P, Veeragandham S. Comparative study of Papanicolaou stain [PAP] with rapid economic acetic acid Papanicolaou stain (REAP) in cervical cytology. *J Evol Med Dent Sci* 2015;4:7089-96.
3. Thakur M, Guttikonda VR. Modified ultrafast Papanicolaou staining technique: A comparative study. *J Cytol* 2017;34:149-53.
4. Choudhary P, Sudhamani S, Pandit A, Kiri V. Comparison of modified ultrafast Papanicolaou stain with the standard rapid Papanicolaou stain in cytology of various organs. *J Cytol* 2012;29:241-5.
5. Sinkar P, Arakeri SU. Utility of modified ultrafast Papanicolaou stain in cytological diagnosis. *J Clin Diagn Res* 2017;11:EC28-31.
6. Biswas RR, Paral CC, Dey R, Biswas SC. Rapid economic, acetic acid, Papanicolaou stain (REAP) – Is it suitable alternative to standard PAP stain. *Al Ameen J Med Sci* 2008;1:99-103.
7. Bhagat P, Susheilia S, Singh K, Sadhukhan S, Rajwanshi A, Dey P. Efficacy of modified rapid economic acetic acid-based Papanicolaou stain. *Cytopathology* 2016;27:452-5.
8. Asthana A, Singh AK. Comparison of the routine Papanicolaou staining technique with the rapid, economic, acetic acid, Papanicolaou (REAP) technique. *Int J Med Dent Sci* 2014;3:484-9.