

[CASE REPORT]

Acute Unilateral Isolated Oculomotor Nerve Palsy in an Adult Patient with Influenza A

Joe Senda^{1,2}, Kunihiro Araki², Yasushi Tachi³, Hazuki Watanabe^{2,4}, Yuichi Kagawashira², Mizuki Ito^{2,5}, Naoki Atsuta², Masahisa Katsuno², Hirohisa Watanabe^{2,6} and Gen Sobue^{2,7}

Abstract:

An otherwise healthy 44-year-old woman exhibited isolated unilateral oculomotor nerve palsy accompanied by an influenza A infection. An intra-orbital MRI scan revealed that her right third intracranial nerve was enlarged and enhanced. She recovered completely during the first month after treatment with oseltamivir phosphate. Although intracranial nerve disorders that result from influenza infections are most frequently reported in children, it is noteworthy that influenza can also cause focal intracranial nerve inflammation with ophthalmoparesis in adults. These disorders can be diagnosed using intra-orbital MRI scans with appropriate sequences and through immunological assays to detect the presence of antiganglioside antibodies.

Key words: oculomotor nerve palsy, influenza A, intra-orbital MRI, antiganglioside antibody

(Intern Med 58: 433-436, 2019)

(DOI: 10.2169/internalmedicine.0850-18)

Introduction

Influenza infections can cause several neurological complications, including polyneuritis, meningitis, encephalomyelitis, encephalopathy, and Guillain-Barré syndrome (GBS) (1). We describe a rare adult case of influenza A virus infection and acute unilateral isolated oculomotor (third) nerve palsy. In this case, the diagnosis was made based on the intra-orbital magnetic resonance imaging (MRI) findings and the presence of antiganglioside antibodies.

Case Report

A 44-year-old Japanese woman presented with high fever (39.0°C) and cough. Her previous doctor diagnosed her with influenza A virus (H3N2) infection via a rapid test performed on a pharynx liquid sample. Her symptoms immediately improved after treatment with oseltamivir phosphate (150 mg). Five days after the onset of influenza symptoms, the patient presented with sudden-onset diplopia when look-

ing towards the right, as well as palpebral ptosis. She had no history of diabetes, glucose intolerance, arterial hypertension, hypercholesterolemia, systemic vasculitis, smoking, obesity, or other risk factors for ischemic oculomotor nerve palsy. The patient had not been vaccinated against influenza in that season. In addition, the patient had no personal or family history of any neurological disorder. A general physical examination revealed no abnormalities. Her blood pressure was 122/64 mmHg. A neurological examination revealed mild oculomotor palsy on the right side. The pupils on both sides were normal and responded promptly to light, which suggested external ophthalmoplegia with pupillary sparing. All other cranial nerves were intact. There were no symptoms of limb weakness, ataxia, or sensory disturbance. Her deep tendon reflexes were all normal, and her plantar responses were flexor. Laboratory screens detected an increase in segmented neutrophils (8,400/ μ L, 80.0% of total white blood cell count) and a slight increase in the C-reactive protein level (1.14 mg/dL). An examination of the cerebrospinal fluid (CSF) on day 5 revealed a mononuclear cell count of 1/ mm^3 , a CSF protein level of 26 mg/dL, and a

¹Department of Neurology and Rehabilitation, Komaki City Hospital, Japan, ²Department of Neurology, Nagoya University Graduate School of Medicine, Japan, ³Department of Radiology, Nagoya University Graduate School of Medicine, Japan, ⁴Department of Neurology, Japanese Red Cross Nagoya First Hospital, Japan, ⁵Department of Neurology, Toyota Kosei Hospital, Japan, ⁶Brain and Mind Research Center, Nagoya University, Japan and ⁷Research Division of Dementia and Neurodegenerative Disease, Nagoya University, Japan

Received: January 18, 2018; Accepted: July 2, 2018; Advance Publication by J-STAGE: September 12, 2018

Correspondence to Dr. Joe Senda, senda1@med.nagoya-u.ac.jp

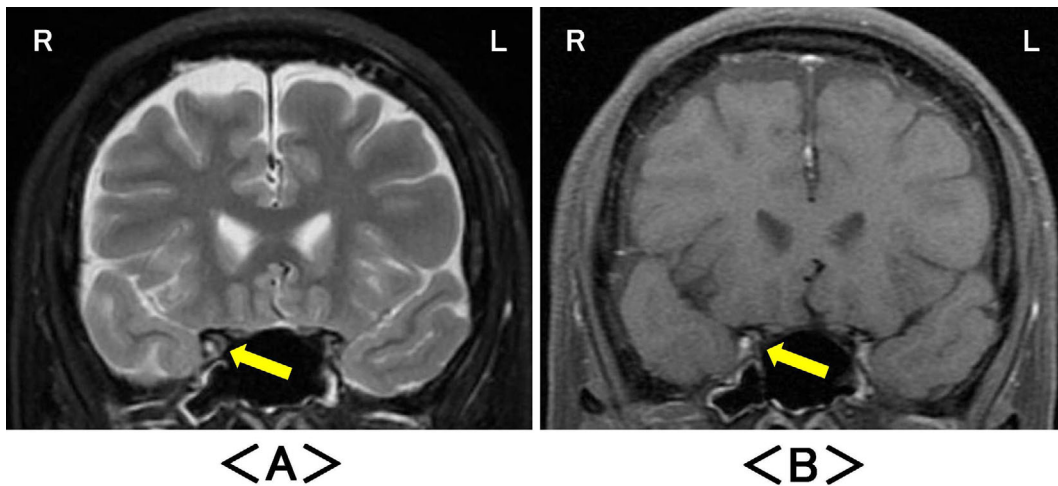


Figure 1. Coronal intra-orbital magnetic resonance imaging on day 5 after the onset of influenza symptoms revealed the significant enlargement and the enhancement of the right oculomotor nerve on (A) fat-suppressed T2-weighted images (arrow) and (B) fat-suppressed T1-weighted images with gadolinium enhancement (arrow). R: right, L: left

glucose level of 61 mg/dL, with a plasma glucose level of 87 mg/dL; these values were all within the normal ranges. An intra-orbital MRI scan of the coronal plane (1.5T Signa HDxt, GE Healthcare, Waukesha, USA) on day 5 revealed the significant enlargement and enhancement of the right oculomotor nerve on fat-suppressed T2-weighted images (Fig. 1A) and fat-suppressed gadolinium-enhanced T1-weighted images (Fig. 1B). Magnetic resonance angiography did not reveal any abnormalities in the orbits or brain. The levels of antiganglioside immunoglobulin M (IgM) and immunoglobulin G (IgG) antibodies in the patient's serum on day 10 were measured by a semi-quantitative enzyme-linked immunosorbent assay (-, +, ++, +++, +++++). IgM antibodies against N-acetylgalactosaminyl-GD1a (GalNAc-GD1a), GM1, and GM2 were detected (IgM GalNAc-GD1a: ++, IgM GM1: +, IgM GM2: +). However, no IgG and IgM antibodies against GM1b, GD1a, GD1b, GT1a, or GQ1b were detected. No indicators of autoimmune disease, including serum anti-acetylcholine receptor and IgG4 antibodies, myelin basic protein, and oligoclonal IgG bands in the CSF, were observed. Cultures of the patient's blood and cerebrospinal fluid were negative. Electromyography and nerve conductivity measurements of upper and lower limbs on both sides revealed no abnormalities. Intracranial MRI scans showed no abnormalities apart from the enlarged right oculomotor nerve. Thus, a diagnosis of influenza A infection and acute ophthalmoparesis was made. The patient's ocular symptoms gradually improved and complete recovery was observed after one month, without the administration of intravenous immunoglobulin, corticosteroids, or other immunosuppressive medication. Two years later, the patient was still free of neurological symptoms. A follow-up MRI scan showed slight persistent enhancement of the right oculomotor nerve on fat-suppressed T2-weighted images. Significant enhancement was not observed in any other region on gadolinium-enhanced T1-weighted images (Fig. 2). Additionally, IgM

antibodies against GalNAc-GD1a, GM1, and GM2 were still present (IgM GalNAc-GD1a: ++, IgM GM1: +, IgM GM2: +) at the time of a follow-up MRI scan.

Discussion

We herein describe the case of a patient with an influenza A virus infection and acute unilateral oculomotor nerve palsy that was detected based on MRI findings and the presence of antiganglioside antibodies. Unilateral oculomotor nerve palsy can be caused by several disorders, including cerebral aneurysms, vascular disorders, tumors, or diabetes mellitus. However, no clinical, laboratory, or imaging examinations showed any indications of an underlying structural cause of the oculomotor nerve injury, indicating that influenza infection might have caused the transient oculomotor nerve palsy in this case.

Intracranial nerve disorders caused by influenza infection, including oculomotor nerve and abducens (sixth) nerve palsies, are most frequently reported in children (2-5). Oculomotor nerve palsy after influenza infection or vaccination is rare in adults, and only a few cases have been reported (6, 7). These studies revealed no specific differences in the clinical characteristics of children and adults. However, the reported subjects in these studies did not all undergo MRI. In these cases, an underlying mechanism related to post-infectious GBS was suspected. Influenza infection or vaccination may directly damage the myelin sheaths and surrounding axons due to complications such as GBS (8), acute disseminated encephalomyelitis (9), transverse myelitis (10), and optic neuritis (11). This hypothesis suggests that oculomotor nerve palsy could be triggered by the same mechanism.

In the present case, the intra-orbital MRI scan (coronal plane) at the acute stage revealed significantly enlarged and enhanced signals in the right oculomotor nerve on fat-

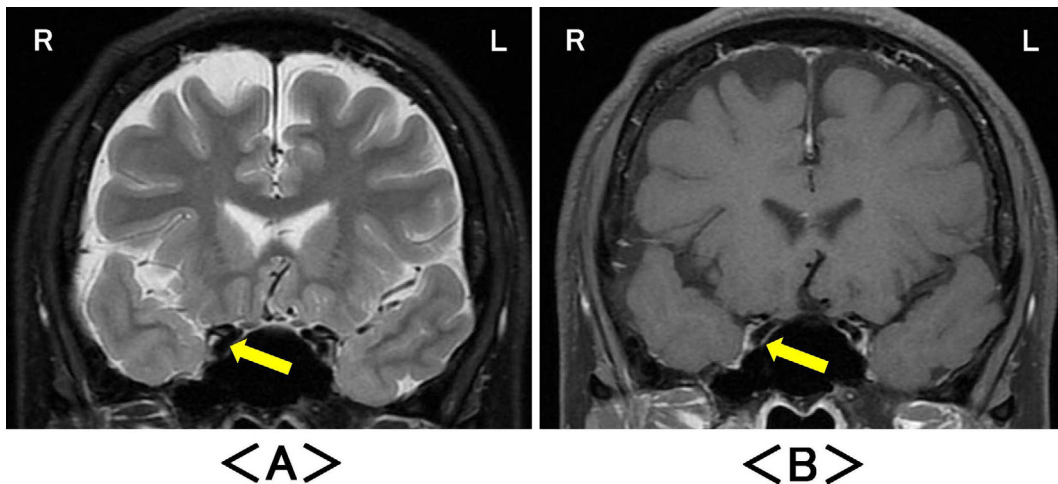


Figure 2. Coronal intra-orbital magnetic resonance imaging two years later revealed slight enhancement of the right oculomotor nerve on (A) fat-suppressed T2-weighted images (arrow), but (B) no abnormalities on fat-suppressed T1-weighted images with gadolinium enhancement (arrow). R: right, L: left

suppressed T2-weighted and gadolinium-enhanced images. The physical examination revealed that the patient's right eye had external ophthalmoplegia with pupillary sparing. Some of the major causes of isolated third nerve palsy include aneurysms of the posterior communicating artery, microvascular ischemia, neoplasm, inflammation, and trauma (12). Microvascular ischemia, which is often associated with diabetes mellitus and hypertension, is believed to be the most common cause of isolated pupil-sparing third nerve palsies. However, compression by aneurysms or tumors can also lead to pupil-sparing oculomotor nerve palsy (13). Neuroimaging, such as brain and intra-orbital MRI, is recommended for patients with such presentations. This patient's recovery from the observed symptoms corroborated the hypothesis of focal demyelination, and this was supported by the MRI findings. Furthermore, this case suggested that the pathological processes involved, including ophthalmoparesis, were caused by influenza A infection, and resulted from a post-infection immune-mediated mechanism that is believed to be associated with the pathogenesis of GBS and ophthalmoparesis involving anti-GQ1b antibodies (14).

To the best of our knowledge, this is the first report of an adult patient with isolated unilateral oculomotor nerve palsy ophthalmoparesis that was detected based on intra-orbital MRI scans and the presence of antiganglioside antibodies, such as IgM antibodies against GalNAc-GD1a, GM1, and GM2. There are reported associations between antiganglioside antibody subtypes and clinical neurological manifestations, such as GM1 and multifocal motor neuropathy (15), GM2 and peripheral facial paralysis (16), and GalNAc-GD1a and acute motor axonal neuropathy (17). In particular, IgM antibodies against GM2 are associated with the post-infection phase of cytomegalovirus (CMV) infections (18). Unfortunately, despite the possibility that this patient had a mixed infection with influenza A virus and

CMV, we were not able to assess her CMV infection status. However, the patient displayed no peripheral facial paralysis. Additionally, with the exception of peripheral facial paralysis, neurological disorders caused by CMV infection are usually associated with a history of acquired immune deficiency syndrome (AIDS) (19). These findings collectively suggest that influenza A infection might cause immune-mediated disorders via antiganglioside antibodies, and that as a consequence it may have caused unilateral oculomotor nerve palsy in this case.

Although neural disorders arising after influenza infection, including encephalitis and encephalopathy, are most frequently reported in children, it is important to note that influenza virus infections can also cause focal neurological signs, such as ophthalmoparesis, in adults. Several techniques are available for characterizing these disorders. First, laboratory screens can be performed to test for the presence of antiganglioside antibodies. Second, intra-orbital MRI scans with adequate sequences, such as fat suppression sequences, are more suitable for detecting the presence of these disorders than conventional MRI scans (20, 21).

It remains unclear why focal neurological deficits may arise following influenza infections in the presence of antiganglioside antibodies, and discrepancies still exist between our patient's symptomatic improvement and the persistence of MRI abnormalities and antiganglioside antibody positivity. Furthermore, due to the slight abnormality in the right oculomotor nerve in the follow-up examination, other pathological mechanisms such as vasculitis via direct virus invasion (22, 23), tumors like orbital schwannoma, or other demyelinating diseases cannot be excluded (24). In addition, spontaneous remission was observed without the use of immunosuppressive therapy with immunoglobulins and corticosteroids, which is considered to be an appropriate treatment for inflammatory neuropathy and related diseases (25). Further investigations are required to determine the appro-

ropriate treatment strategy for cases such as the one described in the present report.

The authors state that they have no Conflict of Interest (COI).

Acknowledgement

The authors extend their gratitude to 1) Dr. Susumu Kusunoki, Department of Neurology, Kindai University Faculty of Medicine, for the measurement of the anti-ganglioside antibodies, and to 2) Dr. Yuzo Nakao, Department of Ophthalmology, Kindai University Faculty of Medicine, for providing advice on this case.

References

1. Studahl M. Influenza virus and CNS manifestations. *J Clin Virol* **28**: 225-232, 2003.
2. Migita M, Matsumoto T, Fujino O, Takaishi Y, Yuki N, Fukunaga Y. Two cases of influenza with impaired ocular movement. *Eur J Paediatr Neurol* **5**: 83-85, 2001.
3. Matsuda A, Chin S, Ohashi T. Two cases of inferior branch palsy of the oculomotor nerve in children. *Nihon Ganka Gakkai Zasshi (J Jpn Ophthalmol Soc)* **99**: 861-865, 1995 (in Japanese, Abstract in English).
4. Khan AO. Recurrent isolated sixth nerve palsy after consecutive annual influenza vaccination in a child. *J AAPOS* **13**: 623, 2009.
5. Leiderman YI, Lessell S, Cestari DM. Recurrent isolated sixth nerve palsy after consecutive annual influenza vaccinations in a child. *J AAPOS* **13**: 317-318, 2009.
6. Yamashita S, Kouzaki Y, Kawano R, Tokunaga M, Uchino M. Acute ophthalmoparesis accompanied with Influenza A infection. *Intern Med* **47**: 1627-1629, 2008.
7. de Almeida DF, Teodoro AT, Radaeli Rde F. Transient oculomotor palsy after influenza vaccination: short report. *ISRN Neurol* **2011**: 849757, 2011.
8. Lehmann HC, Hartung HP, Kieseier BC, Hughes RA. Guillain-Barré syndrome after exposure to influenza virus. *Lancet Infect Dis* **10**: 643-651, 2010.
9. Wang GF, Li W, Li K. Acute encephalopathy and encephalitis caused by influenza virus infection. *Curr Opin Neurol* **23**: 305-311, 2010.
10. Manjunatha N, Math SB, Kulkarni GB, Chaturvedi SK. The neuropsychiatric aspects of influenza/swine flu: a selective review. *Ind Psychiatry J* **20**: 83-90, 2010.
11. Karussis D, Petrou P. The spectrum of post-vaccination inflammatory CNS demyelinating syndromes. *Autoimmun Rev* **13**: 215-224, 2014.
12. Bruce BB, Biousse V, Newman NJ. Third nerve palsies. *Semin Neurol* **27**: 257-268, 2007.
13. Jacobson DM. Relative pupil-sparing third nerve palsy: etiology and clinical variables predictive of a mass. *Neurology* **56**: 797-798, 2001.
14. Yuki N, Odaka M, Hirata K. Acute ophthalmoparesis (without ataxia) associated with anti-GQ1b IgG antibody: clinical features. *Ophthalmology* **108**: 196-200, 2001.
15. Kuwabara S, Yuki N, Koga M, et al. IgG anti-GM1 antibody is associated with reversible conduction failure and axonal degeneration in Guillain-Barré syndrome. *Ann Neurol* **44**: 202-208, 1998.
16. Kaida K, Kusunoki S, Kamakura K, Motoyoshi K, Kanazawa I. Guillain-Barré syndrome with antibody to a ganglioside, N-acetylgalactosaminyl GD1a. *Brain* **123**: 116-124, 2000.
17. Sheikh KA, Deerinck TJ, Ellisman MH, Griffin JW. The distribution of ganglioside-like moieties in peripheral nerves. *Brain* **122**: 449-460, 1999.
18. Caudie C, Quittard Pinon A, Taravel D, et al. Preceding infections and anti-ganglioside antibody profiles assessed by a dot immunoassay in 306 French Guillain-Barré syndrome patients. *J Neurol* **258**: 1958-1964, 2011.
19. Griffiths P. Cytomegalovirus infection of the central nervous system. *Herpes* **11**: 95-104, 2004.
20. Tien RD, Chu PK, Hesselink JR, Szumowski J. Intra- and paraorbital lesions: value of fat-suppression MR imaging with paramagnetic contrast enhancement. *AJNR Am J Neuroradiol* **12**: 245-253, 1991.
21. Ettl A, Kramer J, Daxer A, Koornneef L. High resolution magnetic resonance imaging of neurovascular orbital anatomy. *Ophthalmology* **104**: 869-877, 1997.
22. Hull JH, Mead SH, Foster OJ, Modarres-Sadeghi H. Severe vasculitic neuropathy following influenza vaccination. *J Neurol Neurosurg Psychiatry* **75**: 1507-1508, 2004.
23. Uji M, Matsushita H, Iwata S. Microscopic polyangiitis after influenza vaccination. *Intern Med* **44**: 892-896, 2005.
24. Tantiwongkosi B, Hesselink JR. Imaging of ocular motor pathway. *Neuroimaging Clin N Am* **25**: 425-438, 2015.
25. Eldar AH, Chapman J. Guillain Barré syndrome and other immune mediated neuropathies: diagnosis and classification. *Autoimmun Rev* **13**: 525-530, 2014.

The Internal Medicine is an Open Access journal distributed under the Creative Commons Attribution-NonCommercial-NoDerivatives 4.0 International License. To view the details of this license, please visit (<https://creativecommons.org/licenses/by-nc-nd/4.0/>).